CASE REPORT

# A case report on an acute schizophreniform disorder in an octogenarian with hearing and visual impairment: is combined medical-mental health unit a solution for the ageing population in Malaysia?

**Noor Huda Abd Hamid, MBBCh[1], Zahira Zohari, MRCP[1], Hakimah Sallehuddin, MRCP[1], Wan Muhammad Amir Wan Md Zin, MRCP[1], Shean Yih Soh, DrPsych[2], Nur Hafidah Ishak, MMed (Psychiatry)[2]**

[1]Department of Medicine, Faculty of Medicine and Health Sciences, Universiti Putra Malaysia, Serdang, Selangor, Malaysia, [2]Department of Psychiatry, Faculty of Medicine and Health Sciences, Universiti Putra Malaysia, Serdang, Selangor, Malaysia

## SUMMARY

**Psychosis in older adults is often attributed to advancing dementia, cognitive impairment, and sensory deprivation. The emergence of very late-onset schizophrenia-like psychosis (VLOSLP) is expected to rise with the global ageing population. This condition, which can be diagnosed as Acute Schizophreniform Disorder if the duration of psychosis is less than six months, poses a significant challenge for both psychiatrists and geriatricians. This case report underscores the unique difficulties in diagnosing this condition in older adults with multiple sensory impairments. The management of such cases, which requires skilled nursing and a tranquil environment, can be particularly challenging in a general medical ward, leading to delayed informal admission to the psychiatry ward. In a centre without a geriatric psychiatrist, a recommended admission pathway from the emergency department to respective wards was developed between the medical and psychiatry departments. The case also highlights the need for ongoing research and development in the medical management of older adults with acute psychosis in Malaysia.**

## INTRODUCTION

Schizophrenia is a serious psychiatric condition with severe symptoms that affect how a person thinks, acts or feels. Schizophrenia is most commonly present early in life, but 20% of patients have onset after the age of 40 years and another peak at the age of 60 years.[1] According to the International Late-Onset Schizophrenia Group, late-onset schizophrenia is defined by the onset of illness after 40 years of age, and very late-onset schizophrenia-like psychosis (VLOSLP) is the onset after 60 years of age.[2] Schizophreniform disorder is a mental health condition that is similar to schizophrenia and has a limited duration. The key feature of schizophreniform disorder is that the symptoms last at least one month and for less than six months, while people diagnosed with schizophrenia experience symptoms for more than six months. Diagnosis of schizophreniform disorder is evaluated with DSM-5.[3] The patient should have two or more of the following: 1) delusions, 2) hallucinations, 3) disorganised speech and thoughts, 4) disorganised behaviour, 5) catatonic behaviour, and/or 6) negative symptoms such as difficulty with self-care, withdrawal and blunted emotional response. There is a dearth of research in this area, and a review of schizophrenia research in Malaysia did not address this condition among older adults.[4]

Early diagnosis and treatment are crucial as they can help to limit damage to the person's life, family, and other relationships. Another aspect of this disorder is the specialist care that they should receive. Ideally, this condition is best managed by geriatric psychiatrists. Acute admission for psychosis is best managed in a properly designated ward, where the environment is supportive, and staff are well-trained. However, in a centre where there is no dedicated psycho-geriatric ward for older patients with acute psychosis, a proper protocol must be developed to safeguard the patients and staff because a patient with psychosis can have severely disruptive behaviour that may cause injury to people or damage to properties. This case report illustrated a challenging diagnosis and management of an 88-year-old man with psychosis admitted to a centre with no geriatric psychiatrist, no gazetted ward for involuntary psychiatry admission, and developed severe disruptive behaviours in the general internal medicine ward.

## CASE PRESENTATION

An 88-year-old gentleman presented with a 3-month history of auditory and visual hallucinations and persecutory delusion of people trying to harm him. He has an underlying visual and hearing impairment, as well as hypertension, dyslipidemia, and coronary artery disease. He was well until the COVID-19 pandemic, when the country went into multiple phases of movement control orders, and he missed his cataract surgery and became socially deprived. Two weeks before the admission, the family noticed disorganised behaviour and progressively worsening auditory hallucinations that disturbed him from performing prayers. The auditory hallucinations presented as a group of other people talking about him and criticising his prayers, making him angry and refusing to continue praying. The visual hallucination presented as confusion on a family member's

*This article was accepted: 22 January 2025*
*Corresponding Author: Hakimah Sallehuddin*
*Email: drhakimah@upm.edu.my*

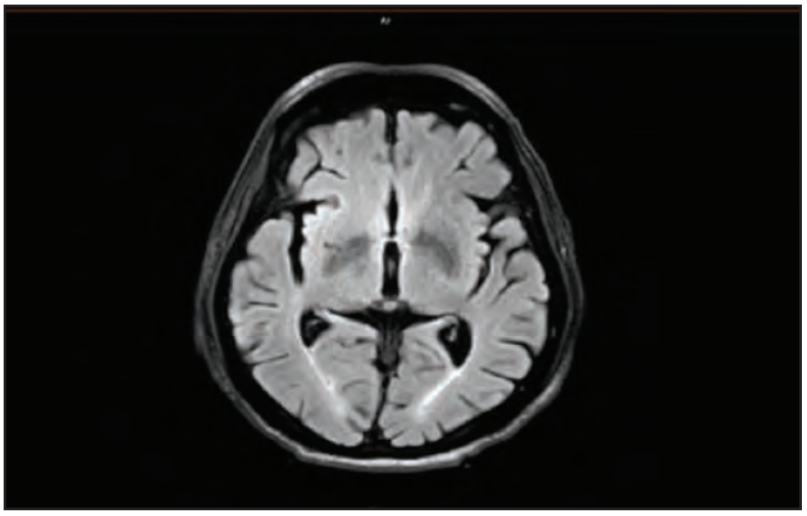

**Fig. 1:** MRI of the brain showing small vessel disease and age-related cerebral atrophy

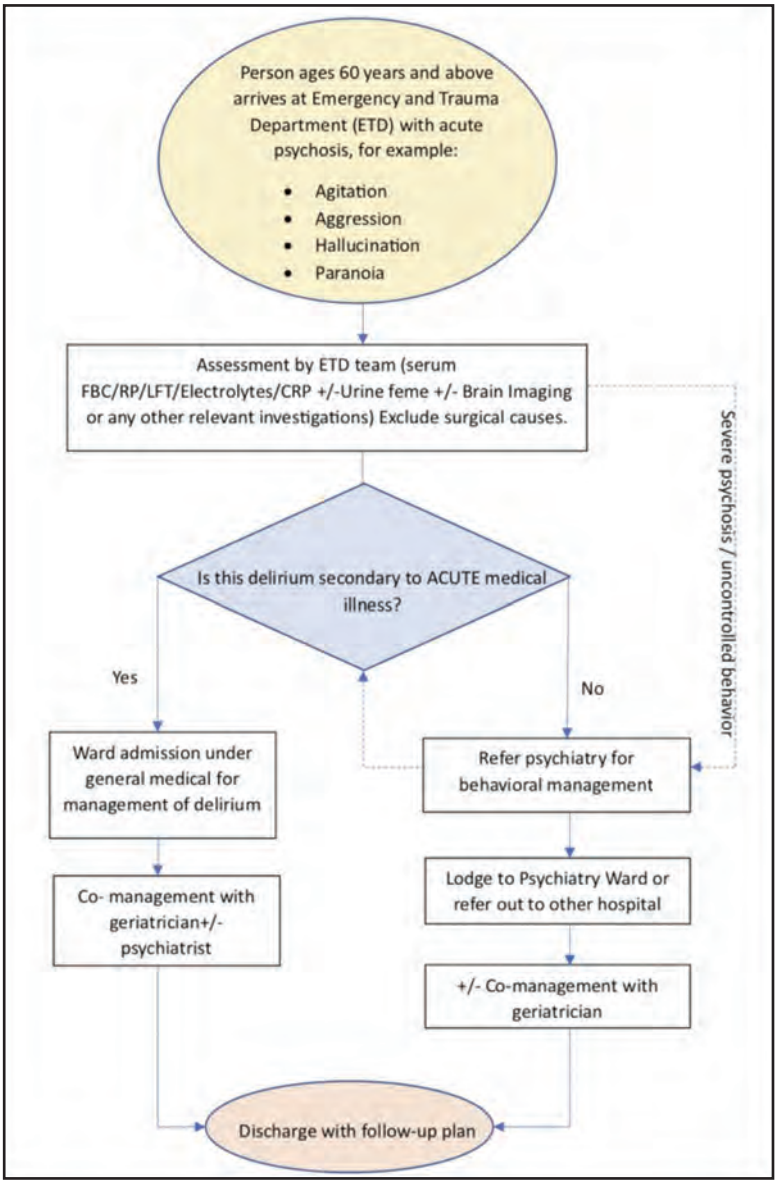


**Fig. 2:** Flowchart for older patients with acute psychosis in ETD. (Dashed line means that an early referral to the psychiatry team can be made while waiting for the investigation results)

face (mistaking his daughter for someone else) and seeing a family member come when he/she did not come at all. He also wanted to see a friend who had passed away long ago. He became aggressive and combative on the day of the presentation to the hospital, which caused a head haematoma to the son as the son prevented him from going to his late friend's house. He adamantly believed that the friend was still alive as he saw him. Functionally, he was living alone, still able to take care of himself, including cooking and doing house chores.

A general examination noted that he has good hygiene and motor function. There was no fever or any localising signs suggesting infection or neurological deficit. His gait was normal, and there were no signs of parkinsonism. A Mini-Mental State Examination (MMSE) was done and showed he had good attention (score 5/5) and short-term recall (score 3/3), but was unable to be completed due to visual impairment, hearing impairment, and he became uncooperative towards the end of the test. Apart from showing paranoia to the attending healthcare practitioners, he had good eye contact and communicated coherently. He refused to eat and said people tried to poison him. We were unable to complete the Geriatric Depression Scale as he became suspicious midway and refused to answer.

He was admitted to the general medical ward, where co-management was done between a geriatrician and general psychiatrists. He was given a diagnosis of acute schizophreniform disorder as the duration was less than 6 months to fulfil the DSM-V criteria for schizophrenia. Differential diagnoses included delirium secondary to sensory deprivation and dementia with Lewy bodies. Given that good baseline memory from history and MMSE were inconclusive in showing significant cognitive impairment (due to the hearing and visual impairments) compared to the degree of behavioural disorder, we proceeded with a particular neuropsychological test for individuals with hearing impairment. We found that the test again was inconclusive as this patient also has visual impairment. To the best of our knowledge, no specific neuropsychological tests assessed cognition in persons with double sensory impairment (visual and hearing).

Blood investigation showed normal complete blood count, electrolytes, thyroid function tests, Vitamin B12 level and liver function tests. Septic markers were negative. Magnetic Resonance Imaging (MRI) of the brain revealed small vessel disease (FAZEKAS 1) and generalised age-related cerebral atrophy (Figure 1).

He required multiple types and doses of anti-psychotics while in the medical ward because of his paranoia and aggressive behaviours. The noise and busy environment in the acute general medical ward were detrimental to the control of his behaviour, requiring him to be transferred to the psychiatry ward, which was more conducive and quieter. On admission, he was started on intramuscular (IM) Haloperidol 2.5mg stat and tablet (T) Quetiapine 50mg twice a day (BD). This did not control the aggression and Syrup Risperidone 1mg BD was started. As we were titrating the dose, he remained uncooperative. Three days later, the medication was changed to orodispersible T.Olanzapine 5mg BD as he refused to take regular medications and kept saying people were poisoning him. T.Olanzapine was titrated within three days to 15mg BD. After 3 days on this dose, he was still uncooperative and showed aggressive behavior towards staf and other patients, needing IM Haloperidol 2.5mg BD. He seemed to respond to this dose and T. Haloperidol 2.5mg BD was started after two days of stabilization and later titrated to 5mg BD. He developed symptoms of tardive dyskinesia while on Risperidone and Olanzapine, and his behaviour was difficult to control on Quetiapine. He was finally stabilised on T.Haloperidol 5 mg BD. He was discharged to his family's home. Unfortunately, he passed away at home three months after being discharged from the ward.

## DISCUSSION

This case illustrated the complex presentation of late-life psychosis in an older adult and the challenge of reaching a diagnosis, as there was no objective cognitive test that was suitable for an older adult with dual sensory impairment. The most important approach was determining whether this was a delirium with reversible causes. The diagnosis of VLOSLP requires clinical evidence and supportive features lasting more than six months, such as a two-stage progression of psychotic episodes, partition delusions, multimodal hallucinations and lack of formal thought disorder or negative symptoms. These features are not pathognomonic but rather highly suggestive of VLOSLP. Previous literature showed that underlying cerebrovascular risk factors (such as long-standing hypertension and dyslipidaemia) and age-specific neurobiological processes contributed to the pathophysiology of VLOSLP.[5] His brain imaging showed a small vessel disease change, which was not significant (FAZEKAS 1) to cause cognitive impairment and also age-related cerebral atrophy.

The management of acute psychosis with underlying acute medical illness (e.g. infection, stroke, fracture) in Malaysia is typically co-managed by two departments – namely medicine and psychiatry. According to the latest data in 2022 from the Malaysian Society of Geriatric Medicine, there were only 63 geriatricians in the country, with 20 public-funded geriatric services to cater for 2.5 million older adults aged 65 and above. On the other hand, there were only 19 geriatric psychiatrists in the country. In centres with geriatricians in the medical department, the case will be managed by geriatricians, with or without psychiatrists. In our scenario, the problem arises if the older patient has acute psychosis but no acute medical illness to suggest a potentially reversible cause of delirium. Traditionally, the best personnel to manage is a geriatric psychiatrist. However, in our setting, there is no geriatric psychiatrist, and there is no gazetted psychiatric ward for involuntary admission of patients with acute psychosis. Admission to a medical ward for patients with no acute medical illness will expose them to nosocomial infections, especially if they need a longer time to stabilise the psychotic episodes.

There may be a legal implication as the admission to a psychiatry ward will be an involuntary admission, with the next of kin must sign a consent form for admission. Previous literature has shown that older adults were at the greatest risk for 'informal admission' to the mental health unit due to the

lack of capacity to provide informed consent for treatment and admission itself.[6] A systematic review of the prevalence of incapacity towards admission and treatment decisions in medical and psychiatry settings showed an average weighted proportion of 45% and 34%, respectively.[7] The same review also mentioned that incapacity in the psychiatry setting was greater in those with dementia, psychosis and mania, while in the medical setting, those with delirium, learning disability and neurological disorders.

In Malaysia, the legal criteria for detaining a patient state that they must be experiencing a "mental disorder of a nature or degree" that justifies admission to a psychiatric hospital for assessment or treatment. This is necessary either for the patient's own health and safety or to protect other individuals.[8] Under the Malaysian Mental Health Act 2001, a person can be admitted involuntarily if they are suspected of having a mental disorder. An application for detention can be made by a relative of the individual to the medical director of the psychiatric hospital. Alternatively, it can be made based on the recommendation of a medical officer or registered medical practitioner who has conducted a personal examination of the individual no more than five days prior to admission. The Act specifies that "no consent is required for other forms of conventional treatment," which includes psychiatric medication. Unlike in some jurisdictions, such as the United Kingdom (UK), where an approved mental health professional can also submit an application, the authority to apply for detention rests solely with the medical profession.

On the other hand, inappropriate admission of patients with acute psychosis to general medical wards might lead to property damage from aggressiveness and injury to the staff and other patients. The open ward, the high load of patients and the noisy environment (from the syringe-pump machines and visitors) of the general medical ward are deemed not conducive for patients with psychosis, who often require a quiet environment and, perhaps, one-to-one care.

Following this case, a geriatrician and two psychiatrists drafted a protocol for admission, as the pathway is complex when the resources are limited. Our centre is a relatively new hospital (started operating in 2020) with only a few trained healthcare professionals in psychosis management, no acute delirium ward, no gazetted psychiatry ward for involuntary admission for acute psychosis, and no geriatric psychiatrist. This protocol was then validated through a series of consensus development conferences with another two senior consultants from internal medicine and psychiatry,respectively (Figure 2).

As our centre is not gazetted for involuntary admission for psychosis, 'lodging' in Figure 2 means the patient is a medical patient but admitted to the psychiatry ward while investigations are ongoing to rule out delirium. Under the hospital system, the medical team was the primary team. Hence, this case illustrates whether, in the future, we need to have a medical mental health unit (MMHU) rather than just a liaison old age psychiatry (LOAP) or a stand-alone psychiatry ward. This unit is a gap in our clinical service provision in Malaysia.

A randomised controlled trial done in the UK on the MMHU in managing older people with delirium and dementia has shown improved carer satisfaction, better patient experience, and was cost-effective compared to standard care (management in either general medical or geriatric unit). This and other models have been summarized by the Malaysian Ministry of Health Medical Development Division.[9] Alternatively, LOAP has been implemented to offer psychiatry services in medical and surgical wards, as well as training the general medical staff.[10] Service delivery for the mental health of older adults also requires more dedicated research as it involves resource and financial implications for the nation in the long run.

Many times, in the event of acute psychosis, the carer was stressed and exhausted. Therefore, care and empathy must be exercised to allow respite and counselling. Some of the carers will need mental health support from psychologists and psychiatrists to manage behaviours at home. Crisis-plan interventions and education must be given to the carers so that they can be prepared if such an event occurs again, and steps must be taken to possibly prevent it.

## CONCLUSION

In a resource-limited setting, safeguarding older adults with acute psychosis is of utmost importance. Admission to an appropriate ward is crucial to avoid health-related implications, to allow stabilisation of the psychosis and to provide respite to the carer. An MMHU or other joint behavioral units, co-managed by geriatricians and psychiatrists, has been shown to be beneficial and cost-effective. However, if the unit is deemed to involve substantial financial and resource implications, then the LOAP service can be implemented. Finally, it is recommended that each healthcare facility have a structured pathway of admission for older adults with acute psychosis.

## ACKNOWLEDGMENT

The publication of this manuscript was funded by the Universiti Putra Malaysia Department of Medicine Publication Grant. The authors thank the patient's family for permitting us to publish this article. We also thank the head of medical department, Dr Anim Md Shah and the head of psychiatry department, Dr Chong Seng Choi for the invaluable input in refining the admission pathway.

## CONSENT

Written consent was obtained from the next-of-kin as the patient had been deceased at time of writing.

## CONFLICT OF INTEREST

The authors have no conflict of interest to declare.

## REFERENCES

1. Stępień-Wyrobiec O, Nowak M, Wyrobiec G, Morawiec E, Wierzbik-Strońska M, Staszkiewicz R, et al. Crossroad between current knowledge and new perspective of diagnostic and therapy of late-onset schizophrenia and very late-onset schizophrenia-like psychosis: An update. Front Psychiatry 2022; 13: 1025414.

2. Howard R, Rabins PV, Seeman MV, Jeste DV. Late-onset schizophrenia and very-late-onset schizophrenia-like psychosis: an international consensus. The International Late-Onset Schizophrenia Group. Am J Psychiatry 2000; 157(2): 172-8.
3. Diagnostic and statistical manual of mental disorders. 5th ed: American Psychiatric Assoaciation; 2013.
4. Yoon CK, Aziz SA. A Review of Schizophrenia Research in Malaysia. Med J Malaysia 2014; 69: 46-54.
5. Regala J, Moniz-Pereira F. Very Late-Onset Schizophrenia-Like Psychosis: A Case Report and Critical Literature Review. Ann Geriatr Med Res 2023; 27(2): 175-8.
6. Khan FA, Rice D, Tadros G. The use of supportive observations within an inpatient mental health unit for older people and dilemma of using the Mental Health Act (2007) or the Mental Capacity Act (2005) in England and Wales. J Psychiatr Ment Health Nurs 2013; 20(1): 91-6.
7. Lepping P, Stanly T, Turner J. Systematic review on the prevalence of lack of capacity in medical and psychiatric settings. Clinical Medicine 2015; 15(4): 337-43.
8. Khan NN, Yahya BA, Abu Bakar AK, Ho RC. Malaysian mental health law. BJPsych International 2015; 12(2): 40-2.
9. Nurkhodrulnada ML and Izzuna MMG. Delirium Unit in Geriatric Ward. Technology Review. Ministry of Health Malaysia: Malaysian Health Technology Assessment Section (MaHTAS); 2021 70 p. Report No.: 018/2020.
10. Nogueira V, Lagarto L, Cerejeira J, Renca S, Firmino H. Improving quality of care: focus on liaison old age psychiatry. Ment Health Fam Med 2013; 10(3): 153-8.