CASE REPORT

A rare spectrum of branchi-oto-renal syndrome

Saidatur Rabiqah Adawiyah Md Ali, MB BcH BAO, Azliana Aziz, MMED ORL-HNS, FEBORL-HNS

Department of Otorhinolaryngology-Head & Neck Surgery, School of Medical Sciences, Universiti Sains Malaysia Health Campus, Kubang Kerian, Kelantan, Malaysia

SUMMARY

This case describes an eight-year-old boy who presented with bilateral progressive hearing loss and speech impediments. Physical examination revealed small cutaneous opening on both sides of the neck and an asymmetrical ear formation, specifically a 'bat-ear' deformity on the right side. Auditory testing confirmed the loss of hearing bilaterally, and extensive radiological evaluations uncovered complete bilateral branchial fistulas and anomalies in the external, middle, and inner ear structures, with no kidney abnormalities detected, leading to the diagnosis of Branchiootic Syndrome. These findings highlight the importance of considering this rare syndrome when encountering patients with similar auditory and physical signs, guiding clinicians toward accurate diagnostic and therapeutic strategies.

INTRODUCTION

Branchi-oto-renal spectrum disorder (BORSD) is a genetic disorder inherited in an autosomal dominant manner characterized by structural ear malformations alongside branchial and renal anomalies.[1,2] This spectrum encompasses both branchi-oto-renal (BOR) syndrome, which includes renal anomalies, and branchiootic (BO) syndrome, which spares the kidneys.[1] While BOR has an estimated incidence of 1 in 40,000, BO is even rarer, and both syndromes exhibit high phenotypic variability.[1,3] Diagnosing BORSD typically requires meeting major and minor criteria based on Chang et al. in 2004 which may include branchial anomalies, hearing loss, auricular deformities, and preauricular pits.[2] Early recognition of BO can improve outcomes, especially in cases where auditory rehabilitation is critical for speech development.[3] Here, we present a case of BO syndrome in a young boy, highlighting the clinical presentation, diagnostic process, and management, underscoring the importance of a detailed workup in similar cases.

CASE PRESENTATION

An eight-year-old boy was seen in the outpatient clinic with a two-year history of progressive bilateral hearing loss and associated speech challenges. His teacher initially observed the problem, noting that the boy often seemed confused when given verbal instructions. His articulation was impaired, and he had started using gestures to aid in communication. Apart from worsening hearing, he had no symptoms of ear discharge, dizziness, facial weakness, or tinnitus.

On physical examination, bilateral cutaneous fistula (Figure 1 and Figure 2) openings were noted anterior to the sternocleidomastoid muscles, which occasionally discharged a clear, colorless, and odorless fluid. The right pinna was positioned lower than the left and was cup-shaped, resembling a "bat-ear" (Figure 3). Bilateral preauricular sinuses were also present but were not actively discharging. Audiometry performed in June 2023 showed moderate-to-severe mixed hearing loss with a reverse sloping configuration. Tympanometry was type A bilaterally. Follow-up audiometry a year later indicated moderate-to-profound mixed hearing loss on the right and mild-to-severe loss on the left, with no change in tympanometry results. At the time of initial assessment, the patient's speech was limited, and he increasingly relied on sign language due to his declining auditory responses.

The family history was significant, as the patient's mother reported bilateral hearing loss and branchial sinus anomalies, although she had never been formally evaluated. The patient's younger brother also displayed similar physical findings, and further assessment was planned.

Given the clinical presentation, the patient underwent contrast-enhanced computed tomography (CECT) of the neck, a CT fistulogram, high-resolution computed tomography (HRCT) of the temporal bones, and a renal ultrasound. The CECT demonstrated complete bilateral branchial fistulas, originating from cutaneous openings on the neck and extending internally to the inferior poles of the palatine tonsils. HRCT of the temporal bones revealed structural abnormalities bilaterally. On the right side, a dilated eustachian tube was noted, along with malformed ossicles fixed to the attic and a hypoplastic cochlea with 1.5 spiral turns and medial deviation of the apex seen. A funnel-shaped internal auditory canal and a 0.4 cm dehiscence in the superior semicircular canal were also observed. The left side had similar findings, with the addition of a dilated vestibular aqueduct instead of semicircular canal dehiscence. The patient denied any urinary-related symptoms, such as dysuria, frequency changes, or hematuria. However, we proceeded with renal profile tests and a renal ultrasound to confirm the absence of abnormalities. The renal ultrasound revealed normal kidney structure and function, ruling out renal involvement. Typically, BOR is associated with renal agenesis, pelviectasis, calyceal cysts, and hydronephrosis, none of which were present here, supporting the diagnosis of BO.[1]

This article was accepted: 09 January 2025
Corresponding Author: Azliana Binti Aziz
Email: az_aziz@usm.my

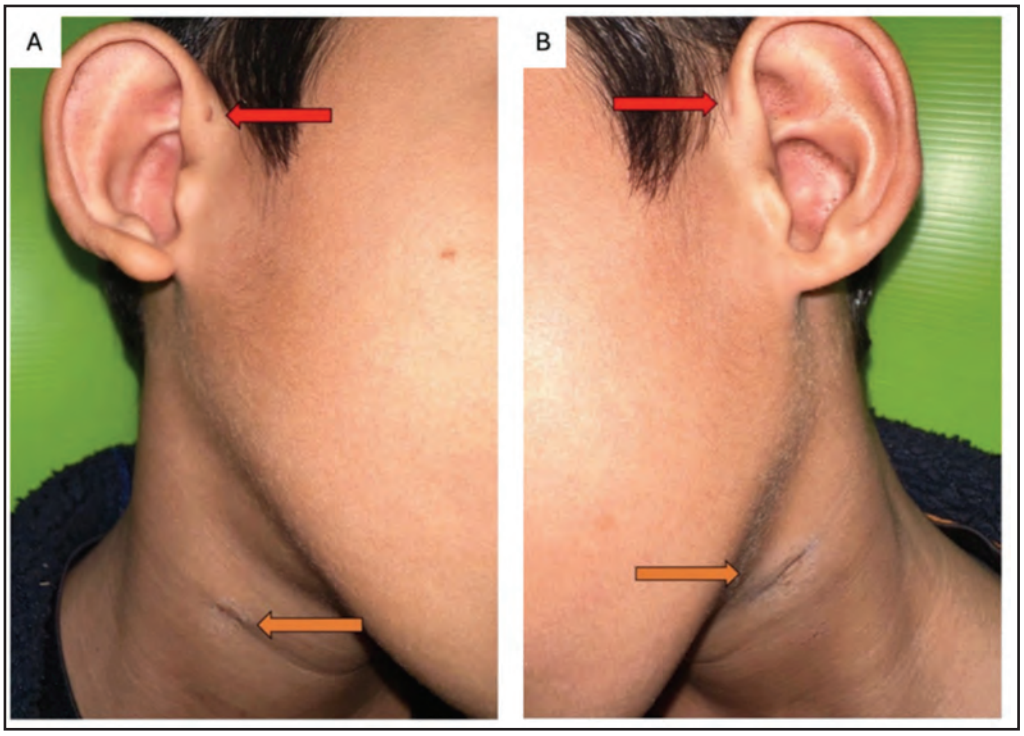

Fig. 1: Figure A shows right preauricular sinus (red arrow) with right cervical fistula (orange arrow) while figure B shows left preauricular sinus (red arrow) with left cervical fistula (orange arrow)



Fig. 2: The right ear displays a 'bat-ear' deformity, positioned more laterally and inferiorly compared to the left ear

Treatment included surgical planning for excision of the branchial fistulas, as well as fitting hearing aids to address his auditory deficits. Post-hearing aid trial, the patient showed improved auditory perception and was more engaged in communication. Speech therapy was recommended to enhance articulation and overall language development.

DISCUSSION

This case report describes a young boy with BO, presenting with classic features of branchial and ear anomalies without renal involvement. Differentiating BO from BOR relies on the absence of renal abnormalities.[1]

In BORSD, a family history can aid the diagnosis. However, when such a history is lacking, a diagnosis can be made based on the presence of either three major criteria or two

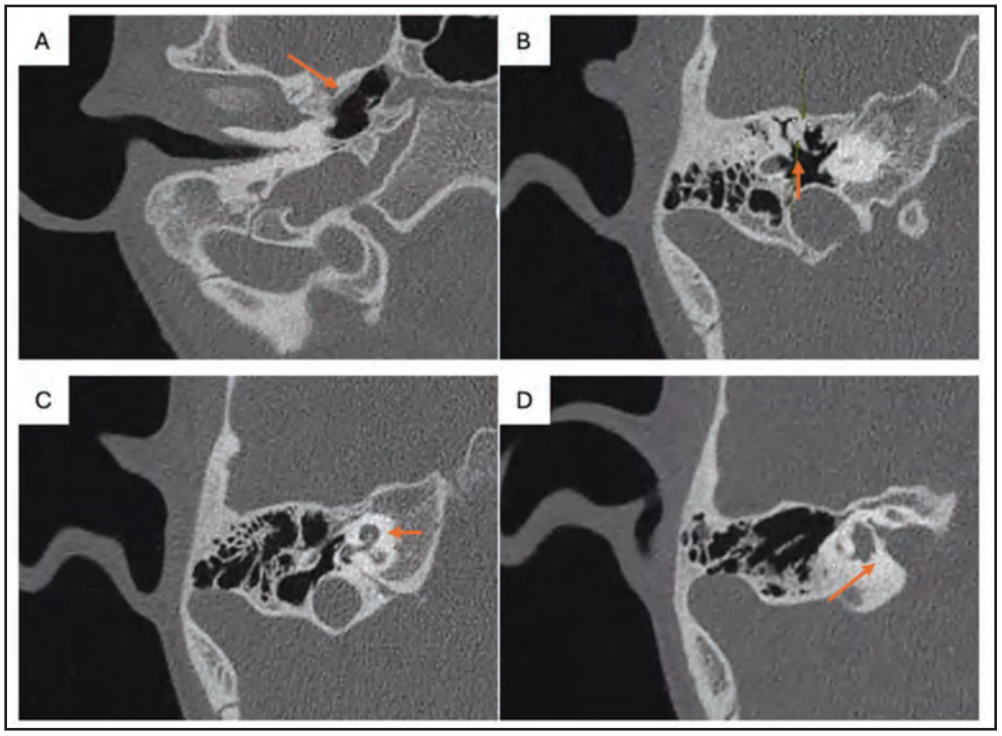

Fig. 3: HRCT temporal bone images (bone window) in axial view, showing the abnormalities (Orange coloured arrows). A; right patulous eustachian tube, B; malformed incus and malleus and fixed in the attic, C; hypoplastic apical turns of cochlear (1.5 spiral turns), D; funnel-shaped internal auditory meatus

major and two minor criteria. Major criteria include second branchial anomalies, hearing loss, preauricular pits, auricular malformations, and renal anomalies. Minor criteria encompass abnormalities of the external auditory canal, middle ear, inner ear, preauricular tags, facial anomalies, and palate abnormalities.[1] The phenotypic variability within BORSD is well documented, with incomplete penetrance and variable expressivity contributing to a wide range of clinical manifestations, even among relatives within the same family.[2]

High-resolution computed tomography (HRCT) of the temporal bone in BORSD often reveals distinctive abnormalities, including an aberrant facial nerve course, funnel-shaped internal auditory canals, and a patulous eustachian tube. Additional findings may include malformed semicircular canals, a reduced tympanic cavity, and an abnormal ossicular chain, which can contribute to conductive hearing loss. Atresia of the external auditory canal is also commonly observed, further impacting ear function.[4] Another specific feature of BORSD is cochlear hypoplasia type 4, also known as the "unwound cochlea," which should prompt a renal evaluation in undiagnosed patients due to its link to renal abnormalities.[5] HRCT of the temporal bones is critical for identifying the specific anatomical anomalies in BO, as it provides detailed images of the middle and inner ear structures, helping guide aural rehabilitation strategies.[4]

Associated renal anomalies in BORSD include renal agenesis, ureteropelvic junction obstruction, calyceal cysts or diverticula, caliectasis, pelviectasis, hydronephrosis, and vesicoureteral reflux. Since renal insufficiency often progresses slowly and with subtle symptoms, a diagnosis may be delayed until significant renal impairment is present.[6]

One of major criteria for BORSD is second branchial arch anomalies. In our case, the patient presented with bilateral complete branchial fistulas, which are notably rare as most cases fistulas present in incomplete form.[7] In a retrospective study of 106 patients with branchial cleft and pouch anomalies conducted by Ford et al., only two cases of complete fistulas were identified.[8]

Management modalities of patients with BO vary depending on the extent and severity of manifestations. Regular audiological assessments are crucial due to the potential impact on hearing, with semi-annual examination is required to check for hearing impairment and annual audiometry is important to assess for the progression of hearing loss.[1] Following the Malaysia Neonatal Hearing Screening Guideline, newborns from families with known cases of BORSD should undergo hearing screening at birth, with subsequent referrals to audiologists for further evaluation, even if they pass the initial screening, given the risk of delayed onset hearing loss.[9] Early aural rehabilitation is imperative for speech development and psychosocial well-being. For patients with hearing loss, aural rehabilitation options such as hearing aids or implants should be considered based on the type and degree of hearing impairment.[1] Surgical excision may be indicated for discharging branchial cleft/fistula, although conservative management is viable for asymptomatic cases.

Given the autosomal dominant inheritance pattern of BORSD, genetic counselling is crucial for affected families. Molecular testing for mutations in the EYA1, SIX1, and SIX5 genes can confirm the diagnosis, particularly in cases without a clear family history[1]. Since each child born to a parent with BORSD has a 50% chance of inheriting the disorder, genetic counselling and prenatal testing can provide valuable guidance for family planning.

CONCLUSION

This case illustrates the need for a thorough evaluation of children with branchial and ear anomalies to accurately distinguish between BOR and BO syndromes. Early recognition of BO can lead to timely interventions that enhance the patient's quality of life, as well as facilitate genetic counselling and support for families.

ACKNOWLEDGMENT

We extend our gratitude to the patient's family for their cooperation and consent in sharing this case.

DECLARATION

The authors declare no conflict of interest.

CONSENT

Consent to publish this case report together with the images was obtained from the patient's parents.

REFERENCES

1. Smith RJH. Branchiootorenal Spectrum Disorder. 1999 Mar 19 [updated 2018 Sep 6]. In: Adam MP, Feldman J, Mirzaa GM, Pagon RA, Wallace SE, Amemiya A, editors. GeneReviews® [Internet]. Seattle (WA): University of Washington, Seattle; 1993–2025. (accessed on 2024, Jan 1)
2. Raman P. Branchiootic Syndrome in a Male Kid - A Rare Case Presentation with Clinical and Imaging Report. Ann Clin Case Rep 2020; 5: 1801.
3. Weerakkody Y, Bell D. Branchio-otic syndrome. Radiopaedia.org [Internet]. 2020 Feb 3. Available from: https://doi.org/10.53347/rid-74067 [accessed on 2024, Apr 4].
4. D'Arco F, Youssef A, Ioannidou E, Bisdas S, Pinelli L, Caro-Dominguez P, et al. Temporal bone and intracranial abnormalities in syndromic causes of hearing loss: an updated guide. Eur J Radiol 2020; 123: 108803.
5. Williams LE, Sohner MT, Sibley RC 3rd, Pfeifer CM. Multimodality depiction of findings in branchio-oto-renal syndrome: two case reports. Acta Radiol Open 2019; 8(7): 2058460119861606.
6. Lin Z, Li J, Pei Y, Mo Y, Jiang X, Chen L. Misdiagnosed Branchio-Oto-Renal syndrome presenting as proteinuria and renal insufficiency with insidious signs since early childhood: a report of three cases. BMC Nephrol 2023; 24(1): 248.
7. Goh LC, Norain RS, Shifa Z, Manuel AM. Bilateral Second Arch Branchial Fistula-A Case Report. Iran J Otorhinolaryngol 2019; 31(107): 383-6.
8. Ford GR, Balakrishnan A, Evans JN, Bailey CM. Branchial cleft and pouch anomalies. J Laryngol Otol. 1992;106(2):137-43.
9. Ministry of Health Malaysia. Guidelines for neonatal hearing screening [Internet]. 2014. Available from: https://www.moh.gov.my/resources/Penerbitan/PErkhidmatan%20Pembedahan%20KKM/GUIDELINES_FOR_NEONATAL_HEARING_SCREENING_PROGRAM_-.pdf [accessed on 2024, April 4]