A Case Report - Discovering Cardiac Myxoma through Microscopic Hematuria

Sue-Anne Han, MRCS, Basheer A Abdul Kareem, FRCS

Department of Cardiothoracic Surgery, Hospital Pulau Pinang, Ministry of Health Malaysia, George Town, Pulau Pinang, Malaysia

SUMMARY

Cardiac myxoma is the most common primary benign cardiac tumours, often located in the left atrium. It usually presents with obstructive cardiac, embolisation or constitutional symptoms, which prompt echocardiography or further imaging studies to confirm the diagnosis. Surgical resection is the treatment of choice for these patients. We present a case with an unusual presentation of microscopic haematuria which resolved completely six months after surgical resection. Interleukin-6 (IL-6) is a proinflammatory cytokine, and the excessive IL-6 production commonly seen in patients with cardiac myxoma has been linked to constitutional symptoms. Overproduction of IL-6 can mimic inflammatory, antibody-mediated autoimmune diseases, vasculitis, and glomerular diseases, leading to glomerular injury, proteinuria, and microscopic haematuria.

INTRODUCTION

Cardiac myxoma is the most common benign cardiac tumours, typically found in the left atrium. It is more frequently observed in women between the ages of 30 and 60. Cardiac myxoma can be either sporadic or familial, with sporadic cases being more prevalent.[1] The presentation of cardiac myxoma usually depends on the location, size, and mobility of the myxoma, with a classical triad of obstructive cardiac, constitutional symptoms or systemic embolization.[1] A transthoracic echocardiogram (ECHO) is usually performed to visualise and diagnose cardiac myxoma, because it is widely available in all hospitals and often yields adequate information necessary for surgical intervention. There have been reports of cardiac myxoma cases presenting with abnormal urinalysis findings, such as proteinuria combined with microscopic haematuria,[2] or proteinuria along with right heart failure.[3] However, no cases have been reported where microscopic haematuria was the sole presenting symptom. Here, we report a case of a patient who presented with microscopic haematuria, without other accompanying renal findings.

CASE PRESENTATION

A 68-year-old woman with underlying hypertension and dyslipidaemia was found to have persistent microscopic haematuria on a urine dipstick examination during routine surveillance for hypertension. She denied having any urinary tract symptoms. Her blood tests showed normocytic normochromic anaemia. A computed tomography (CT) renal 4 phase scan was performed, which did not reveal any renal pathology. Instead, splenic cyst (0.7 x 0.6 cm), cholelithiasis, and a left atrial myxoma (2.5 x 5.0 x 3.5cm) arising from the intra-atrial septum were seen.

She was referred to the cardiothoracic surgery department for further management. She did not have any obstructive cardiac, embolic, or constitutional symptoms. Her transthoracic ECHO showed an ejection fraction of 55-60%, a dilated left atrium, mild mitral regurgitation, and a LA myxoma measuring 12cm^2. CT angiogram of the coronary arteries showed mild coronary arterial disease with a calcium score of 196 and a left atrial mass arising from the interatrial septum with peripheral calcification.

She was scheduled for a left atrial myxoma excision. A transoesophageal ECHO was performed after the patient was under general anaesthesia, showing a 5 x 4 cm left atrial myxoma (Figure 1). A median sternotomy approach was used, and the patient was placed on cardiopulmonary bypass and cooled down to 32ºC. An aortic cross-clamp was applied, and antegrade cardioplegia was administered to achieve diastolic cardiac arrest. A transseptal atrial approach was taken to access the left atrial myxoma. The myxoma measured 5 x 4 cm, with its stalk attached to the fossa ovalis. The myxoma was removed intact, the interatrial septum was closed with a bovine pericardial patch, followed by closure of the right atriotomy. After the patient was rewarmed and the aortic cross clamp was removed, cardiopulmonary bypass was weaned off and terminated uneventfully. The sternum was closed, and the patient was transferred to the cardiothoracic intensive care unit for postoperative care. Transoesophageal ECHO showed satisfactory valve function with no interatrial defects.

Postoperatively, she recovered well and was discharged five days after surgery. Histopathology confirmed a cardiac myxoma with cords and stellate myxoma cells in the background of an abundant myxoid matrix. There were areas of haemorrhage, haemosiderin-laden macrophages, and fibrin deposition. There was no mitosis or nuclear atypia. Follow-up transthoracic ECHO at our clinic showed no residual myxoma, and her urine examination six months later showed resolution of microscopic haematuria.

DISCUSSION

Cardiac tumours can be categorised as primary and secondary tumours, with primary tumours further divided into benign and malignant. Cardiac myxoma is the most

This article was accepted: 30 March 2025
Corresponding Author: Sue-Anne Han Jia Chyn
Email: sueanne_han@hotmail.com

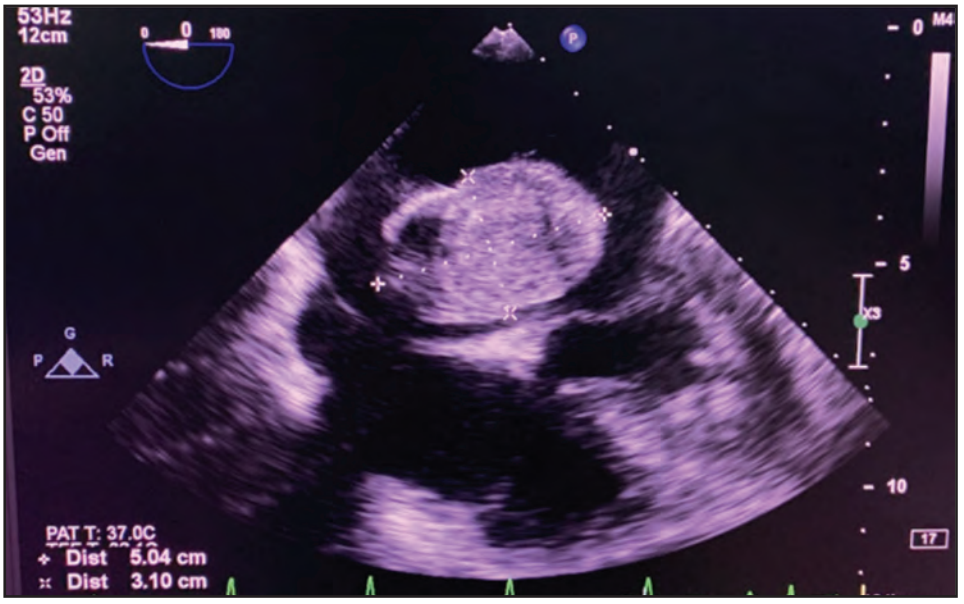

Fig. 1: Left atrial myxoma on transesophageal ECHO intraoperatively

common primary benign cardiac tumours (75%).[1] It has a female predominance and is commonly seen in patients in their third to sixth decade of life. Cardiac myxomas are most commonly found in the left atrium (75%), followed by the right atrium (15-20%), left ventricle (3-4%), and right ventricle (3-4%).[1] Patients with cardiac myxoma usually present with symptoms that form part of the triad of obstructive cardiac, constitutional symptoms, and systemic embolization.[1] However, the patient in this case report presented with persistent microscopic haematuria rather than the typical triad of symptoms, which is an uncommon presentation for a cardiac myxoma in the absence of additional clinical symptoms or signs.

Several studies, including those by Mendoza et al[4] and Jougasaki et al[5], have reported elevated interleukin-6 (IL-6) levels in patients with cardiac myxoma. IL-6 is a proinflammatory cytokine produced by various cell types, such as monocytes, B cells, T cells, fibroblasts, keratinocyte, mesangial cells,[6,7] endothelial cells, vascular smooth muscle cells, and cardiac myocytes.[4,5] IL-6 plays a role in various biological processes, including immune regulation, inflammation, haematopoiesis, oncogenesis, metabolism, and tissue regeneration.[5,7] Excess IL-6 production is associated with constitutional symptoms such as fever, malaise, and weight loss,[2] with higher IL-6 levels correlating with more severe and diverse systemic manifestations.[4] Additionally, IL-6 levels have been positively correlated with tumour size index.[4,5] In our case report, the absence of constitutional symptoms in the patient could be attributed to a tumour size below the threshold required to produce significant IL-6 levels. However, there are no reports establishing the threshold level necessary for constitutional symptoms.

Jougasaki et al[5] demonstrated that circulating IL-6 in patients with cardiac myxoma originates from neoplastic myxoma cells, which further amplify IL-6 production through autocrine and paracrine mechanisms. The classic signaling pathway activates intracellular transduction systems such as Janus kinase (JAK)-signal transducer and phophatidylinositol-3-kinase (PI3K) / Akt. In contrast, the trans-signaling pathway primarily activates the signal transducer and activator of transcription (STAT) 3 and PI3K/Akt pathways.

Renal cells, including podocytes, endothelial cells, mesangial cells, and tubular epithelial cells, are also capable of secreting IL-6. As a result, IL-6 overproduction by cardiac myxoma, in conjunction with activation of the JAK, PI3K/Akt, and STAT3 pathways, may contribute to renal autoimmune, glomerular, and inflammatory disease.[6] These pathways trigger mesangial cell proliferation, glomerular hypertrophy, interstitial fibrosis, tubular atrophy, and extracellular matrix deposition, ultimately resulting in glomerular injury, haematuria, and proteinuria. IL-6 has also been shown to initiate endothelial injury by reducing endothelial nitric oxide synthase and adiponectin expression, which contributes to renal dysfunction.

In addition, renal cells respond to IL-6 by influencing renal cell injury and repair processes, as well as contributing to immune, metabolic, ischaemic and toxin-mediated renal diseases. This has been demonstrated in animal models of systemic lupus erythematosus, where the absence of IL-6 makes mice resistant to immune and inflammatory-mediated tissue injury, resulting in delayed onset of haematuria and proteinuria.[6]

Excessive IL-6 production can also cause cardiac myxoma to mimic inflammatory diseases, antibody-mediated autoimmune diseases,[7] or vasculitis such as Takayasu arteritis,[8] giant cell arteritis,[8] microscopic polyangiitis,[9] and granulomatosis with polyangiitis.[10] The latter two are systemic small-vessel vasculitis associated with elevated anti-neutrophil cytoplasmic autoantibodies (ANCA) levels.

These ANCA-associated vasculitis leads to granuloma formation and inflammation of small arteries, arterioles, venules and capillaries. Affected patients may present with constitutional symptoms or specific end-organ involvement, with the kidneys being most commonly affected (65%) and rapidly progressive glomerulonephritis being a major cause of morbidity and mortality.[9] Excessive IL-6 production by cells in the glomeruli, interstitium, and perivascular sites plays a role in recruiting neutrophils and monocytes, driving further inflammation and potential renal dysfunction. This is supported by renal biopsy findings showing scattered endothelial cells and infiltrating inflammatory cells,[9] as well as focal and necrotizing crescentic glomerulonephritis with immunoglobulin deposition in vessel walls.[10] Hence, patients with ANCA-associated vasculitis typically present with microscopic haematuria, proteinuria, and sometimes elevated serum creatinine levels.[10]

Other case reports[2,3] describe patients with cardiac myxoma presenting with abnormal renal findings. This differs from our patient, who presented only with microscopic hematuria without proteinuria, suggesting a milder degree of renal involvement. Renal biopsy findings in patients with clinical remission from small vessel vasculitis, as reported by Geetha et al,[10] suggest that persistent haematuria represents chronic glomerular injury from prior episodes of vasculitis. Therefore, the resolution of haematuria 6 months post-surgery in our patient supports the role of IL-6 and tumour burden in glomerular dysfunction, and milder renal injury compared to the other 2 case reports. The absence of proteinuria and the presence of anaemia highlight unique aspects of her presentation, reinforcing the variable renal manifestations of cardiac myxoma.

CONCLUSION

Cardiac myxoma is a rare disease, often presenting with symptoms that include the triad of obstructive cardiac manifestations, embolisation, and constitutional symptoms. IL-6 is a proinflammatory cytokine that is excessively produced in cardiac myxoma, where its production is amplified through autocrine and paracrine mechanisms. IL-6 overproduction contributes to renal autoimmune, glomerular, and inflammatory disease, causing changes as such glomerular hypertrophy, interstitial fibrosis, and endothelial injury, ultimately leading to renal dysfunction. Excessive IL-6 in cardiac myxoma can also imitate inflammatory diseases, antibody-mediated autoimmune diseases, or various forms of vasculitis. ANCA-associated vasculitis affects the kidney in 65% of cases and can lead to abnormal urinary findings. Renal biopsy findings in patients with elevated ANCA-associated vasculitis have shown inflammatory cells and glomerulonephritis with immunoglobulin deposition in vessel walls. Hence, cardiac myxoma should be considered in the evaluation of patients with abnormal urinary findings associated with renal diseases such as vasculitis, and systemic lupus erythematosus. The overproduction of IL-6 by cardiac myxoma and its impact on renal cells may be the only indication of the presence of cardiac myxoma.

ACKNOWLEDGEMENT

We would like to acknowledge all the healthcare workers of our hospital who were involved in the management of this patient.

DECLARATION

Verbal consent for publication and accompanying images were obtained from the patient. All authors have no conflict of interest to declare. This manuscript did not receive any funding.

REFERENCES

1. Percell RL Jr, Henning RJ, Siddique Patel M. Atrial myxoma: case report and a review of the literature. Heart Dis 2003; 5(3): 224-30.
2. Bushnell JR, Weston C, Karamadoukis L. An unusual presentation of atrial myxoma with haematuria and proteinuria. NDT Plus 2011; 4(2): 124-5.
3. Anpalakhan S, Ramasamy D, Fan KS. An unusual presentation of atrial myxoma. Singapore Med J 2014; 55(10): e156-8.
4. Mendoza CE, Rosado MF, Bernal L. The role of interleukin-6 in cases of cardiac myxoma: clinical features, immunologic abnormalities, and a possible role in recurrence. Tex Heart Inst J 2001; 28(1): 3.
5. Jougasaki M, Takenoshita Y, Umebashi K, Yamamoto M, Sudou K, Nakashima H, Sonoda M, Kinjo T. Autocrine regulation of interleukin-6 via the activation of STAT3 and Akt in cardiac myxoma cells. Int J Mol Sci 2024; 25(4): 2232.
6. Su H, Lei CT, Zhang C. Interleukin-6 signaling pathway and its role in kidney disease: an update. Front Immunol 2017; 8:405.
7. Berti A, Warner R, Johnson K, Cornec D, Schroeder DR, Kabat BF, et al. The association of serum interleukin-6 levels with clinical outcomes in antineutrophil cytoplasmic antibody-associated vasculitis. J Autoimmun 2019; 105: 102302.
8. Yoshifuji H. Pathophysiology of large vessel vasculitis and utility of interleukin-6 inhibition therapy. Mod Rheumatol 2019; 29(2): 287-93.
9. Berti A, Cavalli G, Campochiaro C, Guglielmi B, Baldissera E, Cappio S, Sabbadini MG, Doglioni C, Dagna L. Interleukin-6 in ANCA-associated vasculitis: rationale for successful treatment with tocilizumab. Semin Arthritis Rheum 2015; 45(1): 48-54.
10. Geetha D, Seo P, Ellis C, Kuperman M, Levine SM. Persistent or new onset microscopic hematuria in patients with small vessel vasculitis in remission: findings on renal biopsy. J Rheumatol 2012; 39(7): 1413-7.