CASE REPORT

Community-acquired MRSA complicated pneumonia in 2 Infants

Yan Yi Neo, MRCPCH, Nicholas Chang Lee Wen, MRCPCH, Rus Anida Awang, MMed (Paed)

Department of Paediatrics, Hospital Pulau Pinang, Ministry of Health, Penang, Malaysia

SUMMARY

Community-acquired methicillin-resistant *Staphylococcus aureus* (CA-MRSA) infection prevalence is increasing worldwide. The true prevalence of CA-MRSA is unknown in Malaysia. We present two cases of CA-MRSA complicated pneumonia in two healthy infants. They had prolonged hospitalization and required surgical intervention eventually. The outcomes were favourable in both cases, with complete clinical resolution at discharge. This article emphasizes the risk factors and the main presenting symptoms of CA-MRSA complicated pneumonia to aid in the treatment of such cases in the future.

INTRODUCTION

Community-acquired methicillin-resistant *Staphylococcus aureus* (CA-MRSA) is defined as a positive culture of MRSA within 48 hours of hospitalization, provided the patient does not have previous history of hospitalization, surgery, residence in a long-term care facility, dialysis within the last 12 months, presence of percutaneous device or indwelling catheter or previous MRSA infection or colonization; as per CDC guideline.[1] Based on the history of the emergence of CA-MRSA associated infections, it was first reported in the 1980s in the United States.[1] Since the 2000s, there have been multiple reports of CA-MRSA from different countries across the globe, with large outbreaks reported in the United States, Taiwan, Canada and Australia.[1] CA-MRSA prevalence is increasing and has become more common than hospital-acquired MRSA (HA-MRSA).[2] It is now recognized as a significant disease burden in the paediatric community worldwide.[2,3] CA-MRSA has emerged as the predominant cause of *Staphylococcus aureus* pneumonia in children in the United States.[4]

There are a few reports on CA-MRSA infections in Malaysia. The first case series of CA-MRSA was published in 2008 by a group of microbiologists in University Malaya.[5] Several clinicians from Sabah reported 37 isolates of CA-MRSA among children up to 10-year-old in a period of 18 months from 2015 until 2017.[6] To date, the true prevalence of CA-MRSA in Malaysia is still largely unknown, highlighting the need for further research and awareness among health care workers.

There are several differentiating features between CA-MRSA and HA-MRSA. At the molecular level, CA-MRSA comprises of Staphylococcal cassette chromosome *mec (SCCmec)* type IV and V, while HA-MRSA contains SCCmec Type I, II or III.[3,5] CA-MRSA commonly causes skin and soft tissue infection. However, it can also cause invasive and severe infections such as severe sepsis, osteomyelitis and complicated pneumonia.[3,5] Epidemiologically, CA-MRSA affects young and healthy individuals compared to HA-MRSA infections which affect the elderly, prolonged hospitalized patients and individuals with chronic disease.[1,5]

We describe two paediatric cases of CA-MRSA complicated pneumonia, which affects two healthy infants with no known medical illness.

CASE PRESENTATION

Case 1

AH, a four-month-old girl with no known medical illness, presented to a district hospital with a three days history of lethargy and reduced oral intake. The general practitioner prescribed one dose of oral antibiotic on the second day of illness. She was born full-term via vaginal delivery with no significant birth or post-natal issues. On arrival to the hospital, she was in severe respiratory failure with a respiratory rate of 66 breaths per minute, heart rate of 190 beats per minute, oxygen saturation of 94% under face mask oxygen 5L/min, moderate subcostal recessions and reduced breath sound over the right lung. The rest of the clinical examinations were unremarkable. Her chest X-ray showed loculated effusion over right lung with right lower lobe consolidation (Figure 1a). Ultrasound thorax demonstrated right pleural effusion, with the maximum thickness of 3cm and multiple locules seen, supporting the diagnosis of complicated pneumonia with stage II empyema thoracis. Laboratory values included a raised total white count of 24,000 with predominant neutrophils (59%) and a C-reactive protein of 188mg/L.

The patient was empirically started on intravenous cloxacillin and ceftriaxone and was put on bilevel positive airway pressure (BPAP) support in paediatric intensive care unit (PICU). A right pigtail catheter was inserted and 12ml of seropurulent fluid was drained. Trial of intrapleural urokinase further drained 60-80ml (12-16ml/kg) of fluid per day. On day three of admission, the patient developed right pyopneumothorax with right lower lobe collapse (Figure 1b). Bedside aspiration through the pigtail catheter was done and the pneumothorax resolved. She completed five days of intrapleural urokinase and was weaned off respiratory support upon completion of urokinase.

This article was accepted: 17 February 2025
Corresponding Author: Yan Yi Neo
Email: yanyi_21@hotmail.com

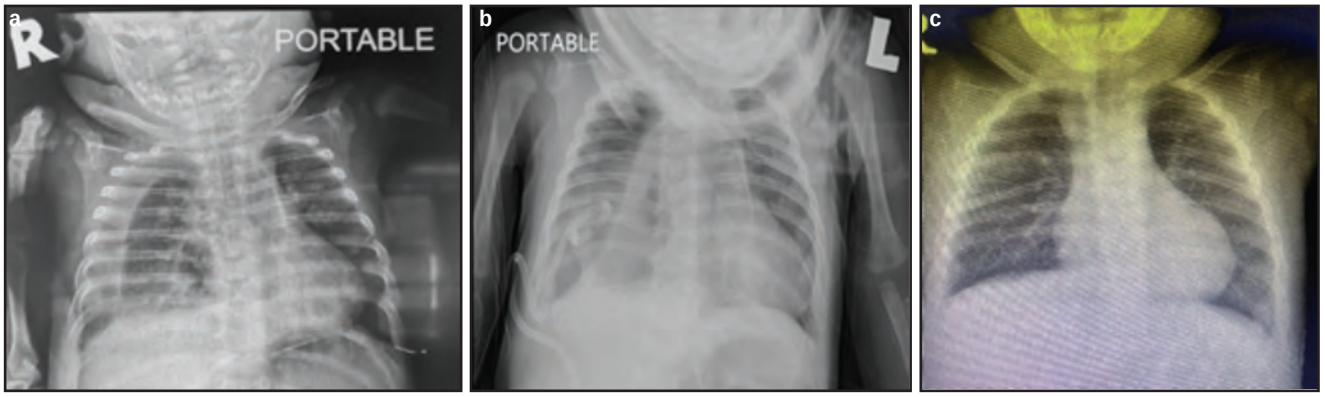

Fig. 1: Chest radiographs of the patient. (a) Frontal supine radiograph shows loculated effusion (arrow) at the right upper and middle zone with right lower lobe collapse evidenced by tenting of the right hemidiaphragm and lower zone opacity). Bilateral air space opacities (including retrocardiac region) suggesting active lung infection. (b) Follow-up chest radiograph showed persistent right loculated effusion with right lower lobe collapse, complicated with pneumothorax. Drainage catheter tip at the area of effusion. (c) Radiograph during review three weeks later in the clinic which showed complete resolution of effusion and lower lobe collapse with no new active lesion seen

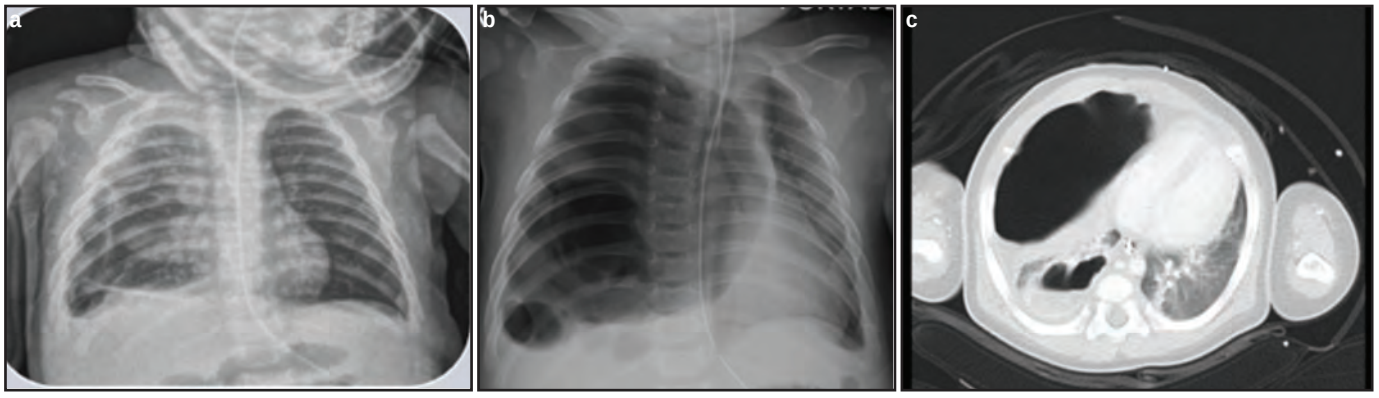

Fig. 2: Imaging of an infant with pleural effusion and CA-MRSA complicated pneumonia. (a) Frontal chest radiograph showed right pleural effusion with right lower lobe collapse. Patchy air space opacities overlying right upper and middle zone represented lung infection. (b) Follow up radiograph showed worsening right pleural effusion with air locule (cavity) extending into right mid-zone. Right lung hyperinflation with mediastinal shift to the left. (c) CECT thorax shows gross right hydropneumothorax with mediastinal shift. The right pleural lining appears thickened and enhancing. There is a cystic lesion with air-fluid level (arrow) in the right lower lobe and adjacent segmental lung collapse

The analysis of the pleural fluid fulfilled Light's criteria for exudative pleural effusion. The pleural culture showed MRSA SCCmec Type IV (CA-MRSA), which was sensitive to co-trimoxazole, gentamicin, rifampicin, and vancomycin but resistant to penicillin, cloxacillin, and clindamycin. The antibiotic was changed to intravenous vancomycin. The blood culture showed no growth.

The right pigtail catheter was not draining nor bubbling for three consecutive days; hence, it was removed. However, one day later, she had worsening respiratory distress due to new onset pneumothorax, which required re-insertion of a right chest drain. Four days later, the chest tube partially dislodged and caused re-accumulation of the right pneumothorax. The persistent air leak gave rise to a clinical suspicion of a right bronchopleural fistula. Following the cardiothoracic surgeon's referral, a mini-thoracotomy with right lung repair was done. A bronchopleural fistula was found in the right lower lobe, and a small 3x4 cm cavity was observed. AH improved tremendously and was discharged home one-week post-surgery (a total of 28 days of hospitalization). She completed ten days of intravenous vancomycin and four weeks of oral sulfamethoxazole and trimethoprim in combination with rifampicin. She recovered completely clinically and radiologically (Figure 1c) upon review three weeks later in our clinic.

Case 2

HT, a 3-month-old girl who was previously healthy, was acutely ill on presentation after six days history of fever and cough. She was born full term via vaginal delivery with no significant birth or post-natal issues. She was in a severe respiratory failure state, with a respiratory rate of 56 breaths per minute, a heart rate of 200 beats per minute and pulse oximetry reading of 96% under room air. On auscultations, there were reduced breath sounds over the right lung. She required BPAP and fluid resuscitation at the emergency department. Her chest X-ray revealed homogenous opacity over the entire right hemithorax, and ultrasound thorax showed right pleural effusion with septation, which was

consistent with stage II empyema thoracis. Laboratory values included a raised white count of 38,700 and CRP of 198mg/L. Her diagnosis was complicated pneumonia with stage II empyema thoracis.

Intravenous cloxacillin and ceftriaxone were initiated. A right chest drain was inserted and drained 95ml (18ml/kg) of seropurulent fluid. On the second day of admission, she was transferred to the PICU in a tertiary hospital. Unfortunately, the chest drain dislodged; however, repeated ultrasound thorax revealed no more effusion. She was continued with respiratory support and intravenous antibiotics.

Pleural fluid culture grew MRSA SCC*mec* type IV (CA-MRSA), and the drug sensitivity results indicated that it was sensitive to vancomycin, cotrimoxazole, rifampicin, sulfamethoxazole, and trimethoprim. Intravenous antibiotic was changed to intravenous vancomycin.

Serial chest X-ray from day three of admission showed an air-filled cavity of increasing size over the right hemithorax (Figure 2a and b). Contrast-enhanced Computerized Tomography (CECT) thorax demonstrated gross right pyopneumothorax with mediastinal shift and a cystic lesion with an air-fluid level in the right lower lobe with communication with the adjacent pyopneumothorax (Figure 2c). GH then underwent right mini-thoracotomy and lung decortication with intra-operative findings of ruptured lung abscess and extensive necrotic tissue within the pleura. Pleural tissue culture was consistent with MRSA. Her primary caretakers were screened positive for MRSA nasal carriers; hence, decolonization with mupirocin ointment and chlorhexidine was done.

She recovered well and was discharged home ten days after surgery (a total of 19 days of admission). She completed two weeks of intravenous vancomycin and four weeks of sulfamethoxazole and trimethoprim. Upon review in the clinic, she was asymptomatic with full radiological resolution within three months.

DISCUSSION

Both cases involved healthy infants under the age of 6 months with severe CA-MRSA complicated pneumonia. They had prolonged recovery and required surgical intervention eventually. The outcomes were favourable in both cases, with a complete clinical resolution upon discharge.

Complicated pneumonia is defined as severe pneumonia with local complications such as parapneumonic effusion, empyema thoracis, lung abscess, bronchopleural fistula, necrotizing pneumonia or systemic complications such sepsis, multiorgan failure and acute respiratory failure. Complicated pneumonia predominantly affects healthy children with no known medical illness. Complicated pneumonia is treated with a prolonged course of antibiotics. The initial choice of antibiotics depends on local guidelines and antibiotic resistance profile. Symptomatic effusion should be drained, followed by intrapleural fibrinolytic if indicated. Surgical interventions such as video-assisted thoracoscopy and thoracotomy, may be needed in advanced empyema thoracis and for those who do not respond to non-surgical interventions.[7]

Community-acquired methicillin-resistant Staphylococcus aureus (CA-MRSA) frequently occurs in otherwise young and healthy individuals.[1,4] In a large case series done in Texas Children's Hospital involving 117 patients, the mean age of CA-MRSA was 0.8 years.[4] This finding was similar to another study in Hawaii, United States.[8] However, a study done in Likas Hospital, Sabah, showed the most prevalent age for CA-MRSA infection is 1 to 5 years old.[6] Besides young age, other risk factors for CA-MRSA infection include MRSA colonization, prior infection among close contacts, overcrowding and low socioeconomic status.[3,6]

CA-MRSA is highly associated with respiratory infections and severe pneumonia compared to methicillin sensitive *Staphylococcus aureus* (MSSA).[2] MRSA pneumonia often involves unilateral consolidation, pneumatocele formation and pneumothorax.[8] They are more prone to develop complicated pneumonia such as necrotizing pneumonia, lung abscess or empyema thoracis as compared to *Streptococcus pneumoniae*.[3] The increased prevalence of Panton-Valentine leucocidin (PVL) toxin in the CA-MRSA strain could explain this clinical condition as PVL promotes white blood cell lysis and causes tissue necrosis.[3] Furthermore, numerous studies found that systemic complications such as sepsis and septic shock, ventilatory support, intensive care unit admission, pleural drainage or surgical intervention are more frequent among CA-MRSA infected patients.[3,8] These undoubtedly cause higher morbidity and increase the length of hospitalization stay.

As a general rule, CA-MRSA is primarily resistant to beta-lactam antibiotics (penicillin, cephalosporin, carbapenem), aminoglycosides and macrolides.[3] Hence, the antibiotic choices remaining are vancomycin, clindamycin, linezolid, trimethoprim-sulfamethoxazole, rifampicin and doxycycline. The Infectious Disease Society of America (IDSA) recommended empirical anti-MRSA therapy for hospitalized children with severe community-acquired pneumonia.[9] Intravenous vancomycin is recommended.[9] Most case series in the developed country used intravenous vancomycin as an empirical antibiotic.[4] However, this is not commonly practised in Malaysia. Both of our patients were given intravenous vancomycin after reviewing the pleural fluid culture result, and they responded well.

Clindamycin is frequently used as the next alternative drug of choice in mild to moderate CA-MRSA infection or oral alternative to intravenous vancomycin.[4,9] However, CA-MRSA may develop inducible resistance to clindamycin, and there is an increasing trend in the resistant profile for clindamycin in Malaysia.[1,5] Clindamycin can be considered after reviewing the drug susceptibility profile.

Linezolid is FDA approved for treating MRSA pneumonia in children;[9] however, its use has been restricted due to high cost. Due to its excellent susceptibility profile, trimethoprim-sulfamethoxazole is the alternative oral drug for treating CA-MRSA pneumonia.[2,5] Rifampicin has bactericidal activity against *Staphylococcus aureus* and achieves high intracellular

levels.[9] It is commonly used in combination with other agents due to the rapid development of resistance if used as monotherapy.[1,9] Further research is needed to look into the role of rifampicin as adjunctive therapy in CA-MRSA infections.[9]

Prevention of CA-MRSA infection relies on good personal and environmental hygienic practices. Close contacts should be screened for CA-MRSA infection if household transmission is suspected.[9] Appropriate decolonization in the patient and family members may be done in recurrent skin and soft tissue infections; however, its efficacy in preventing recurrent CA-MRSA infection is still debated.[9]

CONCLUSION

Treating physicians should be aware of the increasing prevalence of CA-MRSA in the paediatric cohort. Early recognition of clinical and radiological findings of CA-MRSA pneumonia is critical in the appropriate and timely management of this infection. This case series also highlight the need to review the local epidemiology of CA-MRSA among the paediatric population and the subsequent clinical implications in the choice of appropriate empiric and targeted antibiotics for such infections.

REFERENCES

1. Skov R, Christiansen K, Dancer SJ, Daum RS, Dryden M, Huang YC, et al. Update on the prevention and control of community-acquired meticillin-resistant *Staphylococcus aureus* (CA-MRSA). Int J Antimicrob Agents 2012; 39(3): 193-200.
2. Fassbind DA, Rezende RQ, Dias CAG, Motta F. Community-acquired and healthcare-associated *Staphylococcus aureus* infections in a pediatric hospital in southern Brazil over 8 years: how common is MRSA? Front Pediatr 2023; 11: 1212239.
3. Ensinck G, Lazarte G, Ernst A, Romagnoli A, López Papucci S, Aletti A, et al. Community-acquired methicillin-resistant *Staphylococcus aureus* pneumonia in a children's hospital. Our ten-year experience. Arch Argent Pediatr 2021; 119(1): 11-7.
4. Carrillo-Marquez MA, Hulten KG, Hammerman W, Lamberth L, Mason EO, Kaplan SL. *Staphylococcus aureus* pneumonia in children in the era of community-acquired methicillin-resistance at Texas Children's Hospital. Pediatr Infect Dis J 2011; 30(7): 545-50.
5. Che Hamzah AM, Yeo CC, Puah SM, Chua KH, Chew CH. *Staphylococcus aureus* infections in Malaysia: a review of antimicrobial resistance and characteristics of the clinical isolates, 1990-2017. Antibiotics 2019; 8(3): 128.
6. Amit LN, Yung CVL, Moy FS, John DV. Molecular characteristics of infection and colonization isolates of community-acquired methicillin-resistant *Staphylococcus aureus* (CA-MRSA). Trop Biomed 2018; 35(2): 442-52.
7. De Benedictis FM, Kerem E, Chang AB, Colin AA, Zar HJ, Bush A. Complicated pneumonia in children. Lancet 2020; 396(10253): 786-98.
8. Erdem G, Bergert L, Len K, Melish M, Kon K, DiMauro R. Radiological findings of community-acquired methicillin-resistant and methicillin-susceptible *Staphylococcus aureus* pediatric pneumonia in Hawaii. Pediatr Radiol 2010; 40(11): 1768-73.
9. Liu C, Bayer A, Cosgrove SE, Daum RS, Fridkin SK, Gorwitz RJ, et al. Clinical practice guidelines by the Infectious Diseases Society of America for the treatment of methicillin-resistant *Staphylococcus aureus* infections in adults and children. Clin Infect Dis 2011; 52(3): e18-66.