Characterizing Dementia Types through F-18 FDG PET-CT: a Case Series from a Tertiary Institution

Kamalia Kamarulzaman, MMed[1], Mohd Fazrin Mohd Rohani, MMed[1], Ahmad Shahir Mawardi, MMed[2], Siti Zarina Amir Hassan, MMed[1]

[1]Department of Nuclear Medicine, Hospital Kuala Lumpur, Malaysia, [2]Department of Neurology, Hospital Kuala Lumpur, Malaysia, Kamalia Kamarulzaman and Mohd Fazrin Mohd Rohani contributed equally to this work

SUMMARY

Dementia, a major neurodegenerative disorder, presents a diagnostic challenge due to its gradual onset and overlapping symptoms among various types. This case series highlights the role of F-18 FDG PET imaging in distinguishing between different dementia types by illustrating their specific metabolic patterns. We evaluated four patients with suspected dementia using F-18 FDG PET-CT at our center. Each patient underwent F-18 FDG PET-CT imaging following a standardized preparation protocol, and images were analyzed qualitatively and quantitatively using Cortex ID software for Z-score and 3D-SSP assessments. F-18 FDG PET imaging revealed specific hypometabolic patterns in different types of dementia, namely Alzheimer's disease, frontotemporal dementia, corticobasal syndrome and vascular dementia, aiding in accurate diagnosis and differentiation. The integration of metabolic imaging with anatomical correlation and statistical mapping enhances diagnostic precision and supports tailored therapeutic strategies. F-18 FDG PET is a valuable diagnostic tool for identifying dementia types through detailed metabolic analysis. It facilitates early and precise diagnosis, guiding effective treatment planning and improving disease management.

INTRODUCTION

Dementia is a primary neurodegenerative disorder caused by the progressive deterioration of neuronal structure and interconnectivity, manifesting as a gradual decline in higher cognitive functions and memory loss, which leads to occupational and societal dysfunction.[1] The most common type of dementia is Alzheimer's disease (AD), followed by vascular dementia, dementia with Lewy bodies (DLB), and frontotemporal dementia (FTD).[1] The assessment of a patient presenting with cognitive impairment entails a comprehensive medical history, detailed physical and neurological examinations, standardized cognitive testing, and targeted laboratory investigations to identify potential underlying etiologies, such as hypothyroidism, major depressive disorder, or the use of pharmacological agents, including anticholinergics or benzodiazepines, which may contribute to cognitive dysfunction. Anatomical imaging with computed tomography (CT) and magnetic resonance imaging (MRI) has also become standard practice in identifying structural, inflammatory, demyelinating, or vascular etiologies.[2] However, neuropathological confirmation remains the definitive standard for diagnosing dementia.[3]

Dementia presents a diagnostic challenge due to its gradual onset and significant symptom overlap among various types. While there is some commonality among dementia syndromes, each differs in clinical progression, complications, and management. Accurate early diagnosis guides timely interventions and therapeutic strategies, including non-pharmacologic treatments. For instance, cholinesterase inhibitors and memantine are effective for AD but not for FTD.[4] Early diagnosis also aids families in understanding the likely course of the disease and may help reduce overall healthcare costs. The most commonly used positron emission tomography (PET) tracer for dementia is Fluorine-18 fluorodeoxyglucose (F-18 FDG) PET, in which the uptake reflects not only local neuronal and synaptic activity but also remote effects, such as deactivation of projection neurons without direct local neuronal damage. A well-known example of this phenomenon is crossed cerebellar diaschisis. This case series demonstrates the utility of F-18 FDG PET in distinguishing between four different types of dementia commonly evaluated at our center.

CASE PRESENTATION

Patient preparation and study procedures followed the European Association of Nuclear Medicine (EANM) procedure guidelines for brain PET imaging using F-18 FDG.[5] Patients were required to fast for 4 to 6 hours and to avoid caffeine, alcohol, or drugs that may affect cerebral glucose metabolism. Blood glucose levels had to be below 10 mmol/L before patients were injected with 0.1 mCi/kg or 3.7 MBq/kg of F-18 FDG, as elevated glucose levels may interfere with brain FDG uptake. Post-injection, the patients were placed in a quiet, dimly lit room, advised not to vocalize, and instructed to keep their eyes open. Image acquisition was performed using a dedicated PET-CT scanner, the General Electric (GE) Discovery MI Digital Ready. Imaging began 30 minutes post-injection, starting with a CT scan of the head (120kV, 10mAs), followed by a PET scan of the same bed position. The CT data was used for morphological correlation and attenuation correction. The reconstructed multiplanar images in axial, coronal, and sagittal views (CT, PET, and fused PET-CT) were then reviewed on a dedicated GE Advantage Workstation (ADW 4.7).

This article was accepted: 25 March 2025
Corresponding Author: Mohd Fazrin Mohd Rohani
Email: fazrinrohani@gmail.com

Image interpretation was conducted both qualitatively and semiquantitatively using Cortex ID software, which includes the creation of Z-score and 3D-SSP images to assess areas of reduced tracer uptake or hypometabolism. The Z-score represents the standard deviation from a normal age-matched database of patients. In normal subjects, FDG uptake is prominent in the caudate nucleus, putamen, thalamus, and cortical gray matter (Figure 1). The diagnosis of dementias and their types are based on specific spatial patterns, severity, and extent of reduced FDG uptake, which can be reproducibly visualized using statistical mapping technology. The different patterns of FDG uptake in the brain were analyzed alongside MRI findings and categorized based on cortical hypometabolic involvement.

Case 1: Alzheimer's Disease
A 40-year-old woman presented with a 2-year history of forgetfulness and a strong family history of young-onset dementia. She had no history of diabetes, hypertension, or any other comorbidities, nor any past surgical history or prior medication. There was no history of headache, fever, trauma, loss of consciousness, dizziness, or weight loss. The patient experienced low mood and declined in activities of daily living. General examination was unremarkable. Her Mini-Mental State Examination (MMSE) score was 16/30. All baseline laboratory investigations were insignificant, and CSF examination was normal. MRI showed progressive generalized cerebral volume loss with focal predilection for the bilateral parietotemporal and precuneus regions. Blood sugar level at the time of F-18 FDG injection was 4.3mmo/L. F-18 FDG PET scan demonstrated a large area of hypometabolism in the bilateral frontotemporoparietal cortices, bilateral precuneus, and posterior cingulate cortices. These findings were consistent with Alzheimer's dementia (Figure 2A).

Case 2: Frontotemporal dementia
A 58-year-old woman presented with progressive dysphasia, bulbar palsy, and right-sided body weakness, which later progressed to the left side over one year, accompanied by progressive cognitive decline. No history of behavioural changes or vulgarity of speech.

The patient was neither a smoker nor an alcoholic, and there was no history of trauma or fever. Her MMSE score was 21/30. MRI of the brain showed non-specific T2/FLAIR hyperintense foci in the juxtacortical left parieto-occipital region, indicative of small vessel disease. Blood sugar level at the time of F-18 FDG injection was 4.9mmo/L. F-18 FDG PET scan demonstrated diffuse FDG hypometabolism in the bilateral frontotemporal and parietal cortices. These findings were consistent with frontotemporal dementia (FTD) or FTD-Motor neuron disease (Figure 2B).

Case 3: Corticobasal syndrome-Corticobasal degeneration
A 54-year-old gentleman presented with a one-year history of memory decline, visual hallucinations, Parkinsonian features of bradykinesia, childish behaviour, and disinhibition. He also reported to have slow volume speech. His MMSE score was 18/30. T2/FLAIR-weighted MRI of the brain showed an old lacunar infarct in the genu of the left internal capsule, with the status of ventricles and subarachnoid spaces consistent with age. Blood sugar level at the time of F-18 FDG injection was 6.0mmo/L. F-18 FDG PET demonstrated asymmetrical FDG hypometabolism predominantly on the left side, affecting the bilateral frontal, parietal, temporal, and posterior cingulate cortices, as well as the thalamus and midbrain. There was also the presence of right cerebellar diaschisis. These findings were consistent with corticobasal syndrome-corticobasal degeneration type (Figure 3A).

Case 4: Vascular dementia
A 54-year-old gentleman presented with short-term memory loss and a sudden onset of left-sided visual hallucinations over the past 6 months. There has been a progressive 'step-wise' deterioration in memory with MMSE score, dropping from 26 to 22 within 6 months. An MRI of the brain using T2/FLAIR weighting revealed multifocal old infarcts with a hemorrhagic component and severe small vessel disease, indicative of vascular dementia. Blood sugar level at the time of F-18 FDG injection was 6.6mmo/L. Additionally, F-18 FDG PET scan showed hypometabolism in the bilateral frontal cortices and the right anterior striatum (including the caudate head and ventral striatum), which, in conjunction with the MRI findings, further supports the diagnosis of vascular dementia (Figure 3B).

DISCUSSION

The brain relies on glucose for energy, and neuronal activity correlates with glucose metabolism. F-18 FDG, a glucose analog with fluorine-18 replacing a hydroxyl group, is used in PET-CT imaging to map brain metabolism. Glucose is transported into the brain by GLUT1 and GLUT3, phosphorylated by hexokinase to glucose-6-phosphate, and metabolized to ATP.[5] However, F-18 FDG accumulates in the brain as it cannot proceed beyond glucose-6-phosphate due to the lack of glucose-6-phosphatase.[5] Dementia causes neuron loss, gliosis, and reduced synaptic connections, leading to hypometabolism visible on F-18 FDG PET-CT. The specific patterns of hypometabolism help to differentiate types of neurodegenerative dementia.[4] In addition, based on patterns and severity of FDG uptake changes together with the statistical mapping analysis, it provides diagnostic clues and supports clinical evaluation, potentially reducing overall healthcare costs for the patient. F-18 FDG PET scan provides a comprehensive assessment by minimizing the need for repeated anatomical or laboratory testing, reduces the time spent on prolonged clinical investigations, and lowers indirect costs such as patient travel, lost workdays, and additional consultations.

PET-CT combines metabolic imaging with anatomical correlation from non-contrast CT. Image interpretation requires recognizing spatial distribution and magnitude of FDG uptake changes, which can be subtle and diffuse. Therefore, visual analysis is complemented by quantitative methods. PET images are standardized using stereotactic coordinates and compared to age-matched databases to create Z-score maps.[5] This approach improves diagnostic performance of readers.[5] PET scan can reveal changes in F-18 FDG uptake in regions affected either directly or indirectly. To accurately differentiate dementing disorders, careful

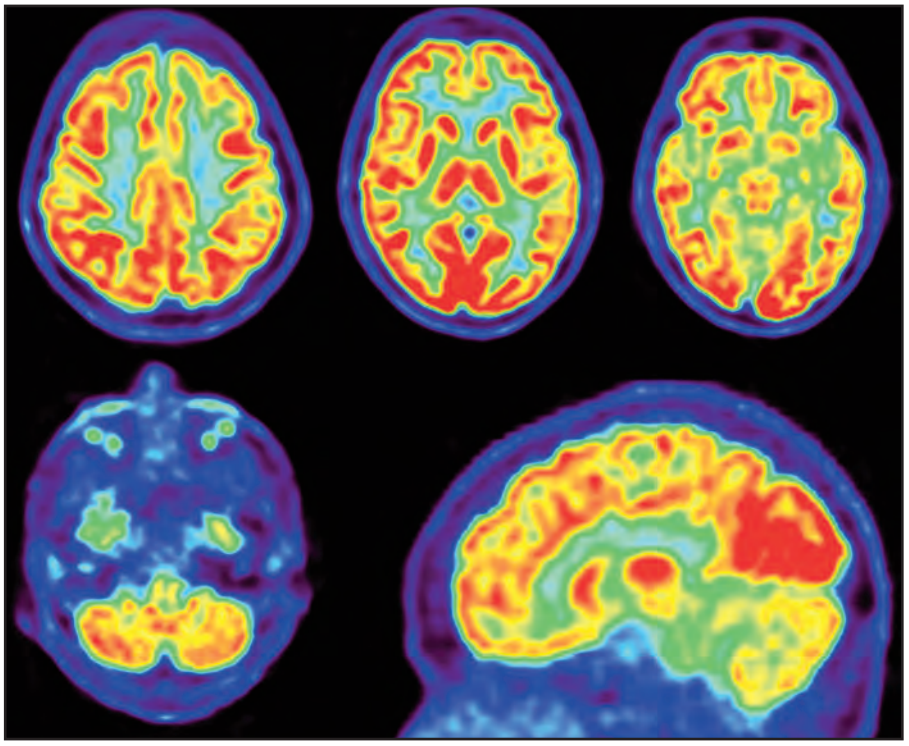

Fig. 1: Selected transaxial and sagittal F-18 FDG PET images showed a normal FDG metabolism distribution in the brain. Red regions indicate the highest FDG uptake, primarily in the subcortical putamen, caudate nucleus, and thalamus, with high uptake also in the cortical grey matter (frontal, parietal, and occipital areas) compared to the temporal cortex, especially the medial temporal region and hippocampus. Green regions represent intermediate uptake, while blue regions show the lowest FDG uptake

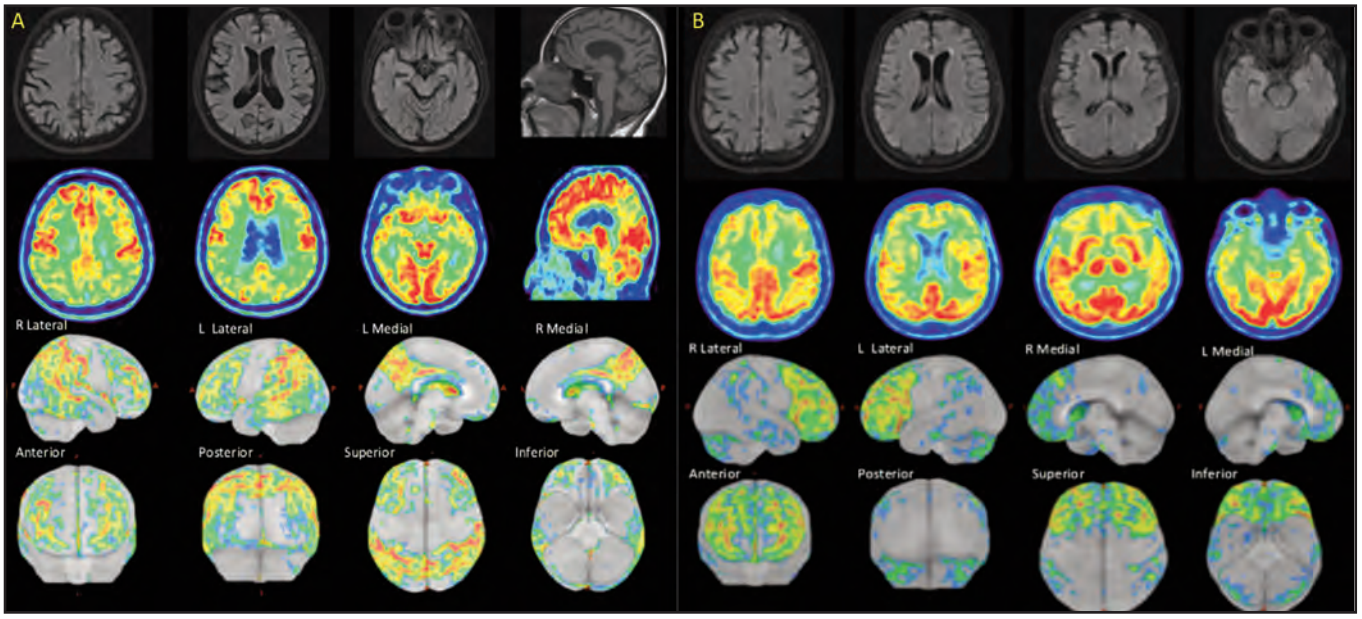

Fig. 2: A&B (Alzheimer's Disease & Frontotemporal Dementia). (2A) Transaxial and sagittal T2/FLAIR images (top row) revealed progressive generalized cerebral volume loss, particularly in the bilateral parietotemporal regions and precuneus. Transaxial F-18 FDG PET images (second row) and Z score maps referencing the pons (third and fourth rows) showed significant hypometabolism in the bilateral frontotemporoparietal cortices, precuneus, and posterior cingulate cortices. (2B) T2/FLAIR weighted images (top row) revealed non-specific hyperintense foci in the left parieto-occipital region, suggesting small vessel disease. F-18 FDG PET images (second row) and Z score maps (third and fourth rows) showed diffuse FDG hypometabolism in the bilateral frontotemporal and parietal cortices

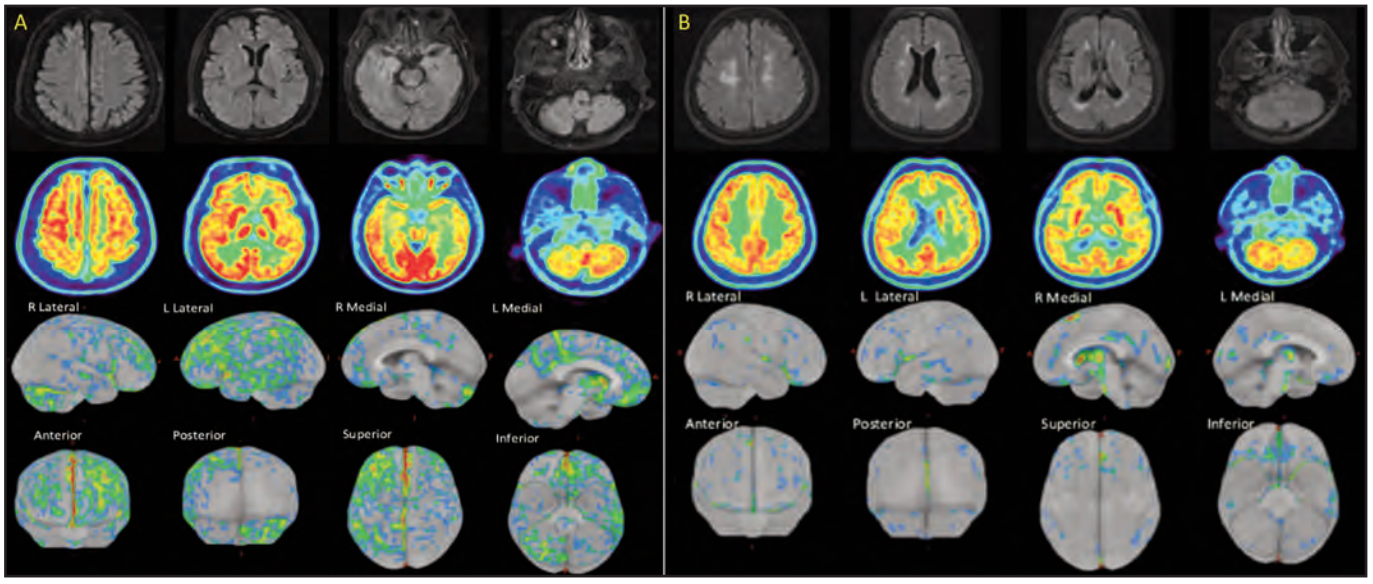

Fig. 3: A&B (Corticobasal Degeneration & Vascular Dementia). (3A) T2/FLAIR images (top row) showed an old lacunar infarct in the left internal capsule's genu. Ventricles and subarachnoid spaces were age-appropriate. F-18 FDG PET images (second row) and Z score maps (third and fourth rows) revealed asymmetrical FDG hypometabolism predominantly on the left, affecting the bilateral frontal, parietal, temporal, and posterior cingulate cortices, as well as the thalamus and midbrain. Right cerebellar diaschisis was also noted. (3B) T2/FLAIR images (top row) showed multifocal old infarcts with hemorrhagic components and severe small vessel disease, suggesting vascular dementia. F-18 FDG PET images (second row) and Z score maps (third and fourth rows) revealed FDG hypometabolism in the bilateral frontal cortices and right anterior striatum (caudate head and ventral striatum).

Table I: Typical brain FDG PET patterns of hypometabolism in neurodegenerative disorders

BRAIN REGION	DISORDERS			
	Alzheimer Disease	Frontotemporal dementia	Corticobasal syndrome	Vascular dementia
Frontal lobe	Early disease: Normal Advanced disease: Decreased	Decreased	Decreased asymmetrically	Normal or decreased, depending on the extent and location of ischemic damage
Anterior temporal lobe	Normal	Decreased	Normal	Normal or minimally affected
Parietal/Posterior temporal lobes	Decreased	Early disease: Normal Advanced disease: Decreased	Normal or asymmetrically decreased	Normal or patchy hypometabolism; often asymmetrical
Anterior cingulate gyrus	Normal	Decreased	Decreased	Normal or decreased, depending on the extent and location of ischemic damage
Posterior cingulate gyrus	Decreased	Early disease: Normal Advanced disease: Decreased	Decreased asymmetrically	Normal
Precuneus	Decreased	Early disease: Normal Advanced disease: Decreased	Normal or asymmetrically decreased	Normal
Basal ganglia	Normal	Normal (typical) or decreased	Decreased asymmetrically; thalamus may also be decreased	Decreased in some cases, reflecting subcortical vascular injury
Primary sensory motor cortex	Normal	Normal (typical) or decreased	Decreased asymmetrically	Normal or decreased, depending on the extent and location of ischemic damage.
Occipital lobe	Normal Lateral occipital decreased asymmetrically (in Posterior cortical Atrophy variant of AD)	Normal	Normal	Normal Unless directly affected by ischemia

assessment of both the spatial distribution and the extent of the regional uptake alteration should be made. Table I summarizes the typical brain FDG PET patterns of hypometabolism in various neurodegenerative disorders.

In specific dementia types as shown in this case series, the classic hypometabolic pattern of Alzheimer's disease on FDG PET is initially observed in the posterior cingulate gyrus during the early stages of AD.[3] This hypometabolic pattern may extend to the precuneus, and parietotemporal association cortex. Frontal association cortex involvement is seen in advanced cases.[6] FDG PET has the ability to detect AD even before noticeable symptoms appear and the degree of hypometabolism correlates with the severity of dementia.[6] However, in a clinical subtype of AD with behavioural variant (bvAD), frontal lobe involvement may be evident at an early stage.[4] This early involvement can make it challenging to distinguish bvAD from behavioural variant of frontotemporal dementia.[4] Findings in AD can be relatively symmetric or asymmetric. The metabolic activity in the primary sensory motor and primary visual cortices, as well as in the anterior cingulate gyrus, basal ganglia, thalamus, pons and cerebellum, remains intact in bvAD.[3,4] However, in the case of posterior cortical atrophy (PCA) variant of AD, occipital lobe hypometabolism is a common finding with asymmetrical lateral occipital involvement.[3]

Characteristically, the behavioral variant of frontotemporal dementia (bvFTD), or classic Pick's disease, demonstrates hypometabolism in the frontal association cortex, anterior temporal lobe, anterior cingulate gyri, and insula, with sparing of the motor cortex, similar to the findings in our patient (Figure 2B).[3] Additionally, the hypometabolic region may extend to involve the caudate nucleus and thalamus. In the early stages of the disease, hypometabolic changes are seen in the frontal cortex, and over time, these changes may extend into the temporal and parietal lobes.[3] Hemispheric metabolic asymmetry is common in FTD cases.[4] The degree of hypometabolism worsens with time, correlating with disease progression.[7] Crossed cerebellar diaschisis may be observed in FTD, although this finding may also be seen in AD and CBS.[4] As temporoparietal involvement may also be seen in AD, the strongest distinguishing features for FTD are the involvement of the anterior temporal cortex and anterior cingulate gyrus, with diagnostic specificities reported as 79.3% and 93.1%, respectively.[3]

Corticobasal syndrome (CBS) is a rare neurodegenerative disorder marked by asymmetric akinetic-rigid syndrome, uncontrollable limb movements (often termed "alien limb syndrome"), higher-order sensory deficits, and cognitive impairment.[8] This condition includes several neuropathologic subtypes, such as corticobasal degeneration (CBS-CBD), Alzheimer's disease (CBS-AD), and progressive supranuclear palsy (CBS-PSP), with CBD being the most frequently diagnosed, followed by AD and PSP.[8] In CBS, asymmetrical FDG hypometabolism is typically observed in the frontal, temporal, and parietal cortices, as well as the precentral gyrus.[8] The distinct underlying pathologies within CBS significantly influence the pattern of FDG-PET metabolism, making it a crucial diagnostic biomarker. For example, typical posterior temporoparietal or medial-frontal patterns are seen in CBS-AD or CBS-PSP respectively, and frontoparietal cortex, thalamus and caudate nucleus in CBS-CBD cases. Specifically, the pathologic diagnosis of CBS-CBD was associated with asymmetric hypometabolism of perisylvian frontotemporal cortex, frontoparietal association cortex, caudate nucleus and thalamus contralateral to the more affected limbs as well as the caudate nucleus and the motor cortex in the less affected hemisphere.[8]

Progressive cerebrovascular disorders can lead to diminished cerebral blood flow, which may result in significant cognitive decline and the development of vascular dementia.[9] This condition encompasses a range of clinicopathologic processes, including large-vessel strokes, multiple smaller infarcts, microangiopathy, subcortical arteriosclerotic encephalopathy, amyloid angiopathy, and cerebral autosomal dominant arteriopathy with subcortical infarcts and leukoencephalopathy (CADASIL).[3] Typically, vascular dementia is associated with stroke-related damage, characterized by periods of cognitive stability interspersed with abrupt declines in function.[9] Additionally, subcortical white matter disease due to small vessel pathology often causes a gradual cognitive decline over many years.[9] Neuroimaging findings in subcortical vascular dementia commonly reveal leukoaraiosis, including extensive periventricular rims and patchy deep white matter hyperintensities.[10] While some degree of leukoaraiosis is common in individuals over 75, its extent can be indicative of vascular dementia. F-18 FDG PET imaging in those with leukoaraiosis may show global or frontal hypometabolism.[10] The distribution of hypometabolism reflects underlying ischemia, infarction, and encephalomalacia.

In addition to F-18 FDG, several other PET radiotracers are used in dementia evaluation. Amyloid imaging agents like F-18 Florbetaben and F-18 Flutemetamol detect beta-amyloid plaques, while tau tracers such as F-18 Flortaucipir target tau protein tangles. In addition to that, dopaminergic tracers like F-18 Fluorodopa assess dopamine function in conditions like Parkinson's disease dementia. However, a detailed description of these radiotracers is beyond the scope of this article.

CONCLUSION

F-18 FDG PET is a key diagnostic tool for cognitive impairment, revealing early and distinct patterns of synaptic and neuronal dysfunction. It aids in early diagnosis, assesses disease severity, and predicts cognitive decline. Statistical mapping enhances FDG PET's ability to differentiate types of dementia, which is crucial for prognosis and treatment planning. Early and accurate diagnosis supports effective therapeutic strategies and better disease management.

REFERENCES

1. Brown RKJ, Bohnen NI, Wong KK, Minoshima S, Frey KA. Brain PET in suspected dementia: patterns of altered FDG metabolism. Radiographics 2014; 34(3): 684-701.
2. Sarikaya I, Sarikaya A, Elgazzar AH. Current status of 18F-FDG PET brain imaging in patients with dementia. J Nucl Med Technol 2018; 46(4): 362-7.

3. Dave A, Hansen N, Downey R, Johnson C. FDG-PET Imaging of Dementia and Neurodegenerative Disease. Semin Ultrasound CT MR 2020; 41(6): 562-71.
4. Minoshima S, Cross D, Thientunyakit T, Foster NL, Drzezga A. 18F-FDG PET Imaging in Neurodegenerative Dementing Disorders: Insights into Subtype Classification, Emerging Disease Categories, and Mixed Dementia with Copathologies. J Nucl Med 2022; 63(Supplement 1): 2S-12S.
5. Arbizu J, Morbelli S, Minoshima S, Barthel H, Kuo P, Weehaeghe DV, et al. SNMMI Procedure Standard/EANM Practice Guideline for Brain [18F] FDG PET Imaging, Version 2.0. Journal of Nuclear Medicine 2024; 124.268754.
6. Pabla HS, Gokulakrishnan PR, Murali A, Sai PM, et al. Role of PET-CT in Aiding Diagnosis of Various Neurological Conditions–A Case Series. Journal of Evolution of Medical and Dental Sciences 2021; 10(07): 440-7.
7. Ricci M, Cimini A, Chiaravalloti A, Filippi L, Schillaci O. Positron Emission Tomography (PET) and Neuroimaging in the Personalized Approach to Neurodegenerative Causes of Dementia. Int J Mol Sci 2020; 21(20): 1-18.
8. Pardini M, Huey ED, Spina S, Kreisl WC, Morbelli S, Wassermann EM, et al. FDG-PET patterns associated with underlying pathology in corticobasal syndrome. Neurology 2019; 92(10): e1121.
9. Borja AJ, Hancin EC, Zhang V, Revheim ME, Alavi A. Potential of PET/CT in assessing dementias with emphasis on cerebrovascular disorders. Eur J Nucl Med Mol Imaging 2020; 47(11): 2493-8.
10. Mendez MF, Ottowitz W, Brown C V., Cummings JL, Perryman KM, Mandelkern MA. Dementia with leukoaraiosis: clinical differentiation by temporoparietal hypometabolism on (18)FDG-PET imaging. Dement Geriatr Cogn Disord 1999; 10(6): 518-25.