Tasteless thalamus: an isolated case of dysgeusia post thalamic stroke

Kalaiarasan Gemini, MD[1], Presaad Pillai, MBBS[1,2]

[1]Neurology Unit, Department of Medicine, Queen Elizabeth Hospital, Sabah, Malaysia, [2]Neurology Unit, Department of Medicine, Queen Elizabeth Hospital II, Sabah Malaysia

SUMMARY

Dysgeusia, an altered or unpleasant taste sensation, is a rare but distressing neurological symptom often overlooked in clinical practice. We present a 33-year-old healthy gentleman, who presented with left sided limb heaviness, slurred speech and facial asymmetry upon awakening. Initial assessment revealed right sided third-cranial nerve palsy, contralateral mild motor and sensory impairment with appendicular ataxia. Imaging showed a right thalamic infarct without large vessel occlusion. Notably, dysgeusia was not reported on presentation but was retrospectively identified three months later during follow-up, when the patient recalled altered taste sensation since the index event. His blood investigations including young stroke workup were normal. Taste perception involves complex neural pathways which includes the thalamus and cortices. Dysgeusia is an underrecognized sequalae of thalamic strokes due to its subtle presentation which is often overshadowed by more troubling symptoms. Our case supports the association between thalamic infarct and gustatory dysfunction with MRI finding correlating with the deficits. Our case highlights the need for greater awareness among clinicians regarding rare stroke manifestations and emphasizes the value of comprehensive history taking and neurological examination.

INTRODUCTION

Dysgeusia refers to a disorder characterized by a persistent, unpleasant, abnormal, or altered taste sensation.[1] Due to its rarity, it is often overlooked by healthcare professionals which can be distressing for the patient. Up to 30% of patients in an observational study were found to experience dysgeusia post stroke. However, it was not reported as a singular symptom post stroke but rather grouped with other neurological deficits. Multiple areas of the central nervous system can be implicated in impaired taste perception, including cerebral cortical, subcortical, thalamic, or brainstem regions.[2] The most frequent infarct location resulting in dysgeusia is localised in the frontal lobe (52%), followed by the thalamus (6%). Lesions at these areas can result in a range of taste disturbances including ageusia, hypoageusia or dysgeusia.[3] Here, we present an intriguing case of a patient who developed dysgeusia following an ischemic stroke, a symptom that was initially overlooked during the acute phase of the event.

CASE PRESENTATION

A 33-year-old male, an active smoker with no known comorbidities, presented with left-sided upper and lower limb heaviness upon waking, associated with facial asymmetry and slurred speech. He reported no other neurological deficit at this time. He presented to the Emergency Department 12-hours later, where he was noted to have right-sided-third cranial nerve palsy, contralateral mild motor weakness, sensory impairment and appendicular ataxia. Cranial nerves that influence taste sensation including facial nerves, glossopharyngeal nerves, vagus nerves and olfactory nerves were intact on examination.

His National Institutes of Health Stroke Scale (NIHSS) score was 3 points, reflecting ataxia involving the left side of the body and moderate loss of sensation. A non-contrast CT brain revealed an established infarct in the right thalamus and the CT angiography did not demonstrate large vessels occlusion. At this point, he did not report dysgeusia, however, this aspect of his medical history was not specifically explored by the treating medical team. He was admitted to the ward, where symptoms significantly improved with intensive rehabilitation. He was discharged ambulating with minimal residual diplopia and was able to return to work one month later.

During his clinic review 3 months after index event, the patient reported an altered sense of taste affecting both sides of his tongue. Upon further exploration of his presenting history, he recalled that the dysgeusia had been present from the onset of the stroke. Objective testing with sweet, sour and bitter food revealed that patient was unable to distinguish them, though he could still differentiate hot and cold sensations. No new or residual neurological deficits were noted on assessment. He had not been prescribed medications commonly known to alter taste, such as angiotensin-converting enzyme inhibitors, antibiotics or antihistamines.

His blood investigations were within normal limits, including haemoglobin, calcium, thyroid function tests, homocysteine, connective tissue screening, antiphospholipid syndrome screening, tumour markers, and lactate dehydrogenase. The patient reported some ongoing improvement in his sense of taste during the 6-month review and will continue to be followed up. An MRI was performed 8 months after index event (Figure 1 & 2).

This article was accepted: 01 March 2025
Corresponding Author: Kalaiarasan Gemini
Email: kalai9210@gmail.com

Table I: Causes of Dysguesia

Division	Causes
Local Cause Damage to the nerves of taste sensation	 Direct Trauma (burns, laceration, surgery) Infection such as Ramsey Hunt or Varicella Zoster Infection or labyrinthitis Mononeuritis multiplex due to DM, Infection such as HIV, Lyme disease, Autoimmune condition such as Polyarteritis nodosa, Eosinophilic granulomatosis polyangiitis Neoplasm causing nerve impingement Radiation therapy
Dietary Deficiencies	Zinc deficiency
Systemic Conditions	Pernicious anemia Crohn disease Hypothyroidism Amyloidosis
Neoplasm	Sarcoidosis Cerebellopontine angle tumour (meningioma or neurinoma) Base of skull neoplasm (chondromas, chondrosarcomas) Head and neck cancers (nasopharyngeal cancer, lymphoma)
Medication Antibiotics Neurology medication Cardiovascular medication Antipsychotics	 Ampicillin, macrolides, quinolones Antiparkinsonism, CNS stimulants, migraine medication Antihypertensive medication, diuretics, antiarrhythmics Tricyclic antidepressants
Aging	

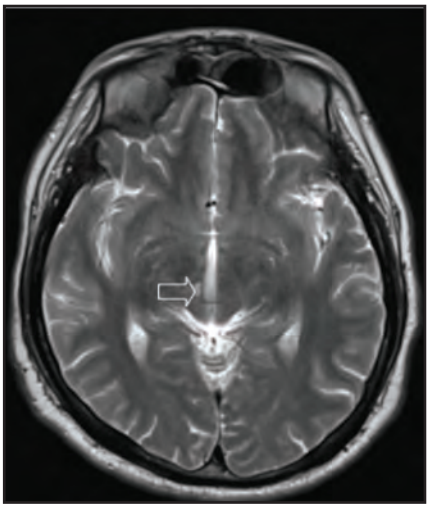

Fig. 1: T2-weighted MRI of the brain demonstrating hyperintensity of the right thalamus (white arrow) suggestive of a chronic infarct

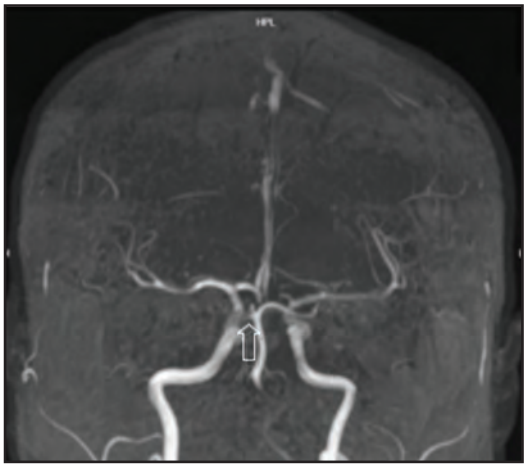

Fig. 2: MRA time-of-flight (TOF) demonstrating flow void (white arrow) over right proximal (P1 segment) Posterior Cerebral Artery suggestive of a focal occlusion

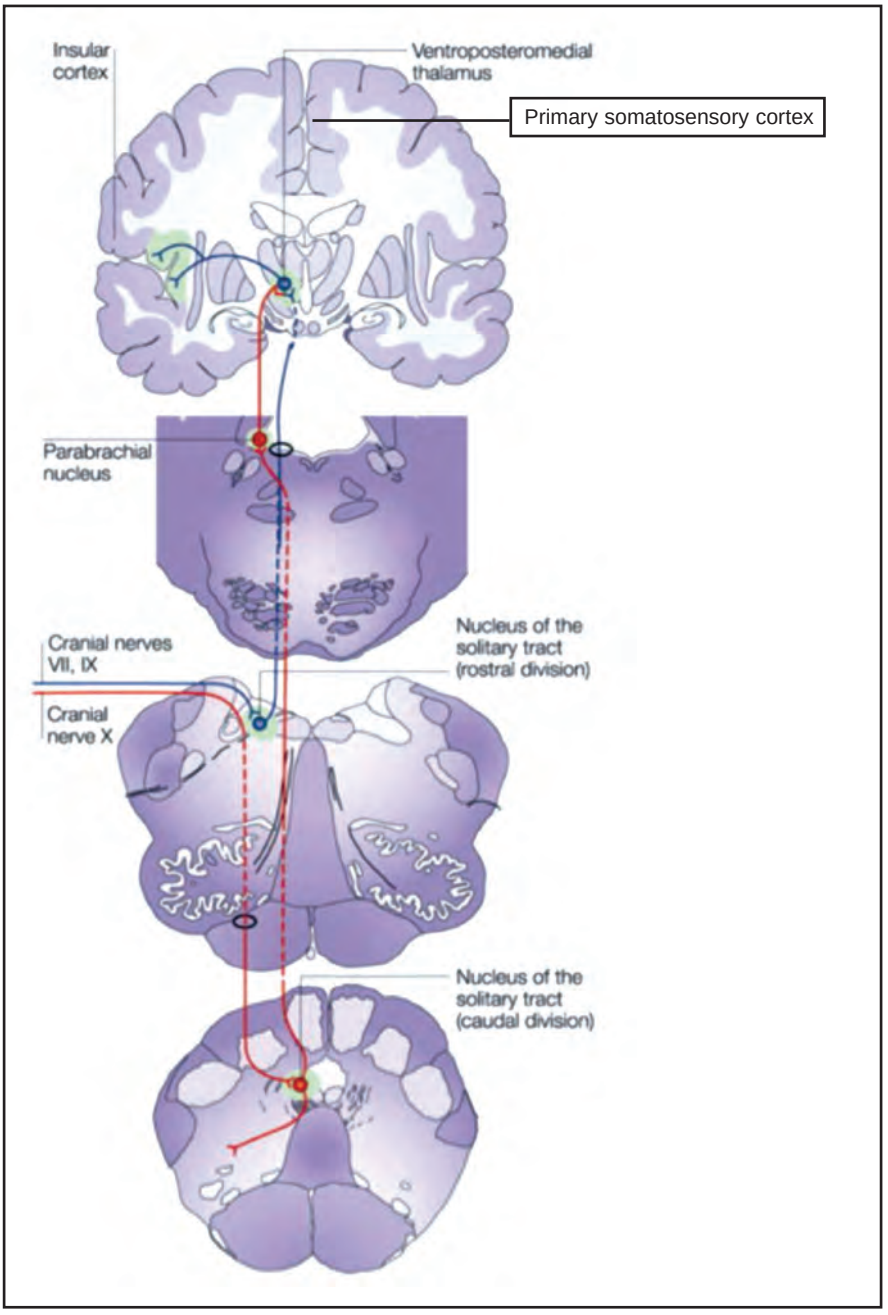

Fig. 3: Anatomical overview of the central taste pathways
(Adapted from (Oliveira-Maia AJ, Roberts CD, Simon SA, and Nicolelis MA. Gustatory and reward brain circuits in the control of food intake. Advances and technical standards in neurosurgery 2011; 36:31-59) with permission from the publisher Springer Nature)

DISCUSSION

We present a young gentleman with symptoms of thalamic and brainstem stroke, characterized by persistent dysgeusia despite resolution of other symptoms. Taste perception is a complex process involving various types of sensory input and multisensory integration, where the brain processes and integrates the sensory inputs from different modalities to form a unified perception and appropriate response.[4]

The perception of taste is influenced by multiple senses, including visual, smell, and touch. The involvement of both ipsilateral and decussated pathways, in activating bilateral cerebral cortex is well documented.[5] Several case reports have documented dysgeusia secondary to infarcts in specific locations, namely pons, cortex and thalamic nuclei, with a particular focus on thalamic infarcts as a cause of bilateral hypogeusia.[6] A Korean case report details an acute left unilateral thalamic infarction leading to bilateral loss of taste. However, the PET scan revealed only a unilateral left insular hypometabolism instead of a bilateral cortical involvement, even though the dysgeusia was noticed on both sides of the tongue. It was postulated that the smaller area of infarct and the possibility of left hemisphere being dominant in taste perception could explain these findings.[7]

In our case, the patient had an infarct involving the right thalamus and right midbrain which likely resulted in taste alteration. Tastant signals from cranial nerves VII, IX, and X reach the rostral nucleus tractus solitarius (rNTS) in the medulla, and are then relayed via the central tegmental tract to the ventroposterior medial nucleus of the thalamus (VPMpc), which then projects to the primary gustatory cortex. This cortex connects to somatosensory regions corresponding to the face and oral cavity and sends signals to the amygdala, hypothalamus and midbrain. Additionally, it projects to the orbitofrontal cortex (secondary taste cortex), where gustatory and olfactory inputs influence flavour perception and satiety. Cortical taste areas also provide feedback to the rNTS and PBN for top-down modulation of taste processing (Figure 3).[8]

Spontaneous recovery of symptoms following the index event for all causes of dysgeusia is documented to be progressive, with the earliest improvement typically seen after 6 months.[6] This is similar to our case as the patient notices improvement in the taste sensation 6 months post index event. Table I shows the list the common causes associated with dysgeusia. However, our patient belonged to a young age group, had no associated comorbidities and was not on any medication leading us to consider the possibility of the aetiology being due to the primary infarct determining the recovery period. Notably, our patient only reported symptoms three months after the primary event which is not surprising as dysgeusia is often overlooked. During follow-up, other potential causes of dysgeusia were thoroughly investigated but not identified.

Currently, there are no targeted treatments for this disabling symptom although the gustatory reward pathway has been well documented.[9] Among the mixed evidence exist on treatments, the use of carbamazepine in a study for stroke-related dysgeusia reports improvement in half of the patients with dysgeusia, however further trials are needed to substantiate its effectiveness.[10]

Our case highlights the rare manifestation of significant dysgeusia resulting from a thalamic infarction is a young, healthy individual. It emphasizes the importance of a thorough history during the initial presentation and the need for a focused, goal-directed rehabilitation program tailored for dysgeusia, as well as further research into targeted pharmacotherapy for this debilitating yet overlooked symptom.

CONSENT

The consent for publication and the usage of MRI images has been obtained from the patient.

FUNDING

No funding was provided for this publication.

REFERENCES

1. Cynthia S, Linda B. Chapter 18 - Prevention Strategies for Oral Components of Systemic Conditions. In: David PC, Connie CM, Editors. Mosby Elsevier Press. Prevention in Clinical Oral Health Care Mosby; 2008: 244-63.
2. Josef GH, Christina S, Christoph JGL, et al. Taste Disorders in Acute Stroke: A Prospective Observational Study on Taste Disorder in 102 Stroke Patients. American Stroke Association Journal 2005; 36(8): 1690-4.
3. Heckmann JG, Heckmann SM, Lang CJG, and Hummel T. Neurological Aspects of Taste Disorders. Archives of neurology 2003; 60(5): 667-71.
4. Barry ES, Terrence RS, and Benjamin AR. Multisensory Integration and the Society for Neuroscience: Then and Now. The Journal of Neuroscience 2020; 40(1): 3-11.
5. M Ganesh K, Jay Prakash, Aparna Tripathy and Preethi Concessao. Taste Pathway: What Do We Teach? Journal of Clinical and Diagnostic Research 2015; 9(1): CL01.
6. Paula MJ, Anthonia HCMLS, and Peter JK. Delayed Dysosmia and Dysgeusia after Thalamic Infarction. Journal of the Neurological Sciences 2015; 348(1-2): 286-7.
7. Kim JE, Song H, Jeong JH, Choi KG, Na DL. Bilateral Ageusia in a Patient with a Left Ventroposteromedial Thalamic Infarct: Cortical Localization of Taste Sensation by Statistical Parametric Mapping Analysis of PET Images. Journal of Clinical Neurology 2007; 3(3): 161-4.
8. Oliveira-Maia AJ, Roberts CD, Simon SA, and Nicolelis MA. Gustatory and reward brain circuits in the control of food intake. Advances and technical standards in neurosurgery 2011; 36:31-59.
9. de Araujo IE and Simon SA. The Gustatory Cortex and Multisensory Integration. International Journal of Obesity 2005; 33(2): 34-43.
10. Etoh S, Kawahira K, Ogata A, Shimodozono M, and Tanaka N. Relationship between dysgeusia and dysesthesia in stroke patients. Inter J of Neurosci 2008; 118(1): 137-47.