Streptococcus suis spinal infection: a case report highlighting an emerging pathogen

Teh Kai Hean, MS Ortho, T Mardhiah TN, MD, Koh Ee Theng, MD, Chan Sook Kwan, MS Ortho, Foo Choong Hoon, MS Ortho

Department of Orthopaedic Surgery, Hospital Queen Elizabeth, Sabah, Malaysia

SUMMARY

Being a multiracial country, Malaysia has been well positioned as a food paradise, serving a wide range of foods, including pork. While Streptococcus suis (S. suis), a facultative anaerobic gram-positive coccus, commonly colonizes the upper respiratory tract, gastrointestinal tract, and genital organs of various animals, especially pigs. Recently, S. suis infections have emerged as a concern in several states, particularly Sabah. This report details the case of a patient who developed a cervical spine infection, outlining the clinical presentation, suspected mode of acquisition, and outcome. Given the ongoing public health threat posed by zoonotic infections like S. suis, priorities should include accurate epidemiological surveillance, regulation of pig farming and slaughtering practices, and continued promotion of safe pork handling and consumption.

INTRODUCTION

Although often overlooked, *Streptococcus suis (S. suis)* is a zoonotic pathogen of significant concern. It has been responsible for large outbreaks of sepsis in China and is a leading cause of bacterial meningitis in adults in Vietnam and Hong Kong, ranking as the most common and third most common cause, respectively.[1] Humans typically acquire *S. suis* infections through contact with pigs, either during slaughter or by handling and consuming undercooked pork products.[2]

Two cases of *S. suis* meningitis with concurrent sepsis have been reported in Sabah, Malaysia. Both patients received a 2-week course of intravenous antibiotic therapy and experienced clinical recovery.[3] However, one patient developed otological complications, including reduced hearing and vertigo. Herein, we report a case of *S. suis* cervical pyogenic spondylodiscitis, including a discussion of the suspected transmission route, clinical manifestations, and outcome.

CASE PRESENTATION

A 71-year-old woman complained of persistent posterior neck pain that persisted even at rest and throughout the night. The pain was accompanied by intermittent fever. She denied experiencing headaches or radicular pain. It is noteworthy that she frequently handles and prepares raw pork for her husband and had recently sustained a minor, improperly managed cut on her thumb while doing so.

Although her initial cervical radiograph (Figure 1) demonstrated disseminated idiopathic skeletal hyperostosis (DISH), no obvious features suggestive of spondylodisciitis changes. Her blood investigations showed elevated septic parameters, including increased white blood cell count (WCC), erythrocyte sedimentation rate (ESR), and C-reactive protein (CRP). Subsequent magnetic resonance imaging (MRI) of the cervical spine revealed spondylodisciitis changes affecting the C4, C5, and C6 vertebrae (Figure 2). Blood culture was positive for *Streptococcus suis* and Echocardiography demonstrated mitral valve endocarditis. The patient was treated aggressively with six weeks of intravenous ceftriaxone, resulting in significant clinical improvement. Follow-up cervical radiographs revealed fusion of C5/C6, and repeat echocardiography showed resolution of the endocarditis.

DISCUSSION

Significant geographical differences are observed in the epidemiology of *S. suis* infection. In Western regions like Europe and North America, cases are primarily concentrated among individuals with occupational exposure to pigs, such as abattoir workers, butchers, and pig breeders. Conversely, Asian regions often report higher infection rates, linked to cultural practices involving the consumption of raw or undercooked pork products, including blood, organs, and meat.[1] In this case, we hypothesize that the patient likely acquired the *S. suis* infection through the improperly managed cut on her thumb, which occurred while she was handling raw pork. A similar case of Streptococcus suis infection was recently reported in Sabah, Malaysia, involving a butcher who had an injured thumb prior to becoming infected.[2] This underscores the importance of proper wound care, regardless of size, before handling raw food. Taking this precaution can help prevent potentially serious zoonotic infections.

Human *S. suis* infections commonly manifest as meningitis or septicemia. Other reported manifestations include endocarditis, arthritis, cellulitis, spondylodiscitis, rhabdomyolysis, pneumonia, peritonitis, uveitis, and endophthalmitis.[1] In this case, the patient presented with both cervical spondylodiscitis and mitral valve endocarditis,

This article was accepted: 11 February 2025
Corresponding Author: Teh Kai Hean
Email: jasontehkaihean@gmail.com

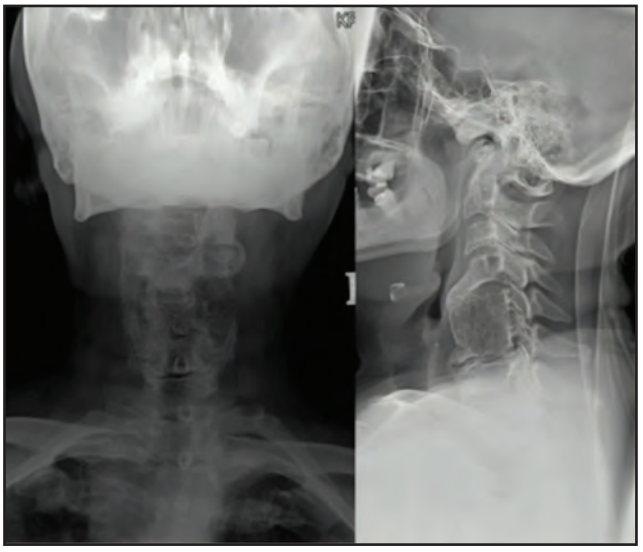

Fig. 1: Cervical radiograph demonstrating bridging osteophytes involving C4, C5, C6 and C7, suggesting disseminated idiopathic skeletal hyperostosis (DISH)

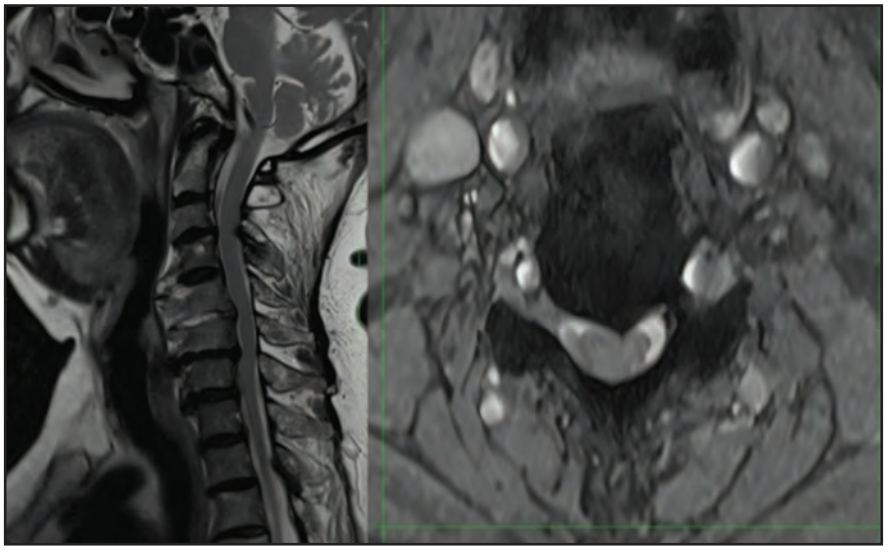

Fig. 2: MRI depicting sagittal and axial (C5/C6 level) views of the cervical spine, revealing C5/C6 discitis, vertebral body edema (anterior), and a small paravertebral collection without epidural abscess formation

the first case reported in Malaysia. This contrasts with two previously reported cases from Sabah, which both presented with meningitis.[2]

Malaysia's National Antimicrobial Guideline, issued by the Ministry of Health, recommends intravenous cloxacillin administered every four hours as the preferred empirical therapy for spinal infections.[3] This primarily targets potential *Staphylococcus aureus* infection. IV cefazolin is considered a second-line empirical therapy option. However, it's important to note that empirical therapy should generally be withheld unless the patient presents with sepsis or neurological compromise. In such cases, a CT-guided biopsy or aspiration is recommended.[3]

In this case, empirical antimicrobial therapy was initiated due to the patient's septic state and subsequently tailored based on blood culture results. While CT-guided biopsy can be a valuable diagnostic tool, it was not pursued initially due to several factors. Studies have shown a relatively low positive yield (approximately 33%) from image-guided biopsies in such cases.[4] Additionally, there are inherent risks associated with the procedure, including potential injury to surrounding structures and exposure to ionizing radiation.[4] However, we acknowledge that CT-guided biopsy may be warranted in specific scenarios. These include immunocompromised patients where atypical organisms, such as Candida species, are a concern; cases with clinical or MRI findings suggestive of tuberculous spondylodiscitis; instances where the diagnosis of spondylodiscitis remains uncertain based on clinical and imaging data; and situations where there is no clinical improvement after six weeks of targeted antibiotic therapy.

Following the Malaysian national antimicrobial guidelines, intravenous antibiotic therapy can be transitioned to oral administration after a minimum of two weeks in cases with good clinical response and oral antibiotic bioavailability.[3] The total duration of antibiotic treatment, whether IV or oral, should be a minimum of six to twelve weeks. Factors influencing treatment duration include the presence of an undrained paravertebral abscess, infection with drug-resistant organisms, and the extent of bone destruction.[3] Our patient received a six-week course of intravenous ceftriaxone for the concurrent diagnoses of uncomplicated cervical spondylodiscitis and native valve endocarditis.

While MRI is imaging modality of choice for diagnosing spondylodiscitis, its utility in post-treatment monitoring remains unclear. Research indicates that MRI often reveals ongoing or worsening bone and disc abnormalities, such as changes in bone enhancement/edema volume, disc height, and signal intensity, even in patients showing clinical improvement.[5] This persistence of bone signal changes on MRI, despite positive clinical responses, could be attributed to the rich vascularization of bone tissue or the proliferation of granulation tissue.[5] Therefore, routine follow-up imaging is not typically advised for patients exhibiting favorable clinical and laboratory results. However, MRI may be selectively employed in cases where unfavorable clinical and laboratory response. When assessing treatment response in such cases, changes observed in soft tissues, such as the size and signal characteristics of psoas, paravertebral, or epidural abscesses, may provide a more dependable indication compared to bone and disc findings.[5]

CONCLUSION

To our knowledge, this case study presents the first documented instance of Streptococcus suis cervical spondylodiscitis in Malaysia. This finding underscores the critical importance of personal protective measures, such as wearing gloves and masks when handling raw pork, to mitigate the risk of zoonotic transmission. Furthermore, it highlights the potential necessity of image-guided cervical tissue biopsy in cases lacking positive blood culture results. Notably, this case also demonstrates the effectiveness of antibiotic treatment alone in managing *S. suis* cervical spondylodiscitis in patients without neurological complications or spinal instability.

ACKNOWLEDGEMENT

No acknowledgement.

CONSENT

Informed consent was secured from the patient.

CONFLICT OF INTEREST

All the authors declare that they have no conflicts of interest to disclose.

FUNDING

No grant funding was secured for this publication.

REFERENCES

1. Huong VT, Ha N, Huy NT, Horby P, Nghia HD, Thiem VD, et al. Epidemiology, clinical manifestations, and outcomes of Streptococcus suis infection in humans. Emerg Infect Dis 2014; 20(7): 1105-14.
2. Rajahram GS, Hameed AA, Menon J, William T, Tambyah PA, Yeo TW. Case report: two human Streptococcus suis infections in Borneo, Sabah, Malaysia. BMC Infect Dis 2017; 17(1): 188.
3. National Antimicrobial Guideline (4th ed.) Ministry of Health Malaysia. 2024
4. Kasalak O, Wouthuyzen-Bakker M, Dierckx RAJO, Jutte PC, Kwee TC. Time to Reconsider Routine Percutaneous Biopsy in Spondylodiscitis? AJNR Am J Neuroradiol 2021; 42(4): 627-31.
5. Ahn KS, Kang C.H., Hong SJ, Kim BH, Shim E. The correlation between follow-up MRI findings and laboratory results in pyogenic spondylodiscitis. BMC Musculoskelet Disord 2020; 21, 428: 1-8