Official Journal of the
Malaysian Medical Association

MJM Case Reports Journal

Volume: 5

Issue No: 2

August 2026

ISSN 2948-3859

MJM Case Reports

Official Journal of the Malaysian Medical Association

Volume 5 Number 2 August 2026

EDITORIAL BOARD

International Advisory Board
Laureate Professor Dr Nicholas Talley
Assoc Prof Dr Mahesh Choolani

Advisor
Prof Datuk Dr Lekhraj Rampal

Editor in Chief
Prof Victor Hoe Chee Wai

Editors

Prof Dr Andee Dzulkarnaen
Prof Dr Chew Keng Sheng
Dr Liew Boon Seng
Prof Dato' Dr NKS Tharmaseelan
Prof Dr Shatriah Ismail
Dr Ravindran Vashu
Prof Dr Irfan Mohamad
Assoc Prof Dr Navin Kumar Devaraj
Assoc Prof Dr Sanjiv Rampal
Lekhraj Rampal

Editorial Manager
Ms Mahaletchumy Alagappan

ISSN 2948-3859

The MJM Case Reports Journal is published three times a year.

All articles which are published represent the opinion of the authors and are not necessarily those of the Malaysian Medical Association unless otherwise expressed.

Copyright reserved © 2026
Malaysian Medical Association

Advertisement Rates:
Enquiries to be directed to the Secretariat.

Secretariat Address:
Malaysian Medical Association
4th Floor, MMA House, 124, Jalan Pahang, 53000 Kuala Lumpur.
Tel: (03) 4042 0617, 4041 8972, 4041 1375 Fax: (03) 4041 8187
E-mail: info@mma.org.my / mjm@mma.org.my
Website: www.mma.org.my

Medical Journal of Malaysia Case Reports

MJM Case Reports

INSTRUCTION TO AUTHORS

Requirements
All submission must be in English. All authors are encouraged to follow the MJM format and ICMJE and COPE guidelines. The case reports (maximum five patients/cases) must follow these requirements:

- Case reports, excluding abstract and references, should not exceed 2,000 words
- A maximum of two (2) tables; three (3) photographs; and up to ten (10) references.
- It shall adhere to the stipulated *MJM Case Reports* format
- There should be no more than seven (7) authors. All authors must have made an individual contribution to the writing of the article and not just involved in the patient's care.
- Patient's details are anonymised as much as possible and appropriate consent/permission obtained
- The case has never been published or has currently been submitted elsewhere for publication

Manuscript text should be submitted as Microsoft Word documents. Tables and flow-charts should be submitted as Microsoft Word documents. Images should be submitted as separate JPEG files (minimum resolution of 300 dpi).

Submissions must conform to the International Committee of Medical Journal Editors Recommendations for the Conduct, Reporting, Editing, and Publication of Scholarly Work in Medical Journals. The Editorial Board reserves the right to reject manuscripts that do not conform to this and policies of *MJM Case Reports*. Neither the Editorial Board nor the Publishers accept responsibility for the views and statements of authors expressed in their contributions.

Authors are advised to adhere closely to the Instructions to Authors. Manuscripts not meeting all the requirements will not be considered for publication and be returned to the authors for correction. Manuscripts should be submitted online through *MJM Case Reports Editorial Manager*.

All submissions must be accompanied by a completed Author Declaration Form, Copyright Transfer Form and Conflict of Interest Form duly signed by all authors. (Forms can be download here).

Article Processing Charge
The *MJM Case Reports* Article Processing Charge (APC) is a non-refundable administrative fee. The current rate takes into account the administrative process required for each submission, and this is a new journal. Hence, the fee will be reviewed from time to time. Payment of the APC does not guarantee acceptance of the manuscript. Submitted manuscripts will only be sent for reviews once the APC has been successful completed.

MMA Member - RM 400.00
Non-Member/ Overseas - RM 500.00

Preparing your manuscript

Manuscripts should be divided into individual section headings and contain the following information. It should not exceed 2000 words (excluding title page, abstract and references).

Title page:
The title page should clearly state the title of the case report without the use of any abbreviations, include full name(s) of the author(s), degrees (limited to one degree or diploma), and affiliations. All the authors' affiliations shall be provided after the authors' names. Indicate the affiliations with a superscript number at the end of the author's degrees and at the start of the name of the affiliation. If the author is affiliated to more than one (1) institution, a comma should be used to separate the number for the said affiliation.

Do provide preferred abbreviated author names for indexing purpose, e.g.L Rampal (for Lekhraj Rampal), BS Liew (for Liew Boon Seng), B Abdullah (for Baharudin Abdullah), Hoe VC (for Victor Hoe Chee Wai).

Please indicate the corresponding author and provide the affiliation, full postal address and email.

Summary:
The abstract should provide a background to the case, summarise its key points, highlight its novelty, learning outcome and implication for clinical practice. It should not be longer than 250 words.

Keywords:
Keywords allows appropriate indexing of the published article to aid future searching. Three to five keywords related to the case report should be provided.

Introduction:
The introduction provides a background and overview of the problem that will be highlighted in the case report. It also aims to summarise the relevant literature pertaining to the topic. It ends with an introduction to the patient/clinical condition that will be discussed in the following section.

Case presentation:
This section provides details of the case. The following is a suggested order of the case presentation.

- Case history – demographic details and medical history
- Physical examination results
- Results of relevant tests or investigations
- Treatment plan
- Outcome of the treatment plan

Discussion:
This section expands on the background written in the introduction. It will focus on the importance of the case and its novelty. Relevant literature should be cited to put this case in the context of the wider published papers.

Conclusion:
The case report ends with a summary of the key points and how it adds to our understanding of specific disease or condition.

Acknowledgements:
This section acknowledges the contribution of others who assisted in the production of the case report manuscript but do not fulfil authorship criteria.

Declarations:
A statement confirming ethical approval and patient (or carer/guardian) consent for publication must be provided. Any funding information should be provided here. Any competing interests by the authors with the manuscript must be declared in this section.

Abbreviations:
If abbreviations are used in the manuscript, they should be defined in the text at first use in the abstract and main text sections, unless they are standard unit of measurements. No abbreviations should be used in the title in the Title Page. Abbreviations should be kept to a minimum.

Formatting of text:
Numbers one to ten in the text are written out in words unless they are used as a unit of measurement, except in figures and tables. Use single hard-returns to separate paragraphs. Do not use tabs or indents to start a paragraph. Do not use the automated formatting of your software, such as hyphenation, endnotes, headers, or footers (especially for references). Submit the manuscript in plain text only and removed all 'field codes' before submission.

Do not include line numbers. Include only page numbers.

References:
MJM Case Reports, follows the Vancouver numbered referencing style. Citations to someone else's work in the text, should be indicated by the use of a number. In citing more than one article in the same sentence, you will need to include the citation number for each article. A hyphen should be used to link numbers which are inclusive, and a comma used where numbers are not consecutive. The following is an example where works 1,3,4,and 5 have been cited in the same place in the text.

- Several effective drugs are available at fairly low cost for treating patients with hypertension and reducing the risk of its sequelae.[1,3-5]

The list of all of the references that are cited in the article should be presented in a list labelled as 'References'. This reference list appears at the end of the paper. Authors are responsible for the accuracy of cited references and these should be verified by the author(s) against the original documents before the manuscript is submitted. It is important that the author should never place in the list of references a document that he or she has not seen. The journals' names should be abbreviated according to the style used in the Index Medicus. All authors when six or less should be listed; when seven or more list only the first six and add et al.

If you are citing the author's name in your text, you must insert the citation number as well.

- Jewell BL[8] underlined that as focus in the SARS-CoV-2 pandemic shifts to the emergence of new variants of concern (VOC), characterising the differences between new variants and non-VOC lineages will become increasingly important for surveillance and maintaining the effectiveness of both public health and vaccination programme.

If you are citing more than one author's name in your text and you want to cite author names in your text, use 'et al.' after the first author.

- Example: Rampal et al.[9] highlighted that the. disregard of the manuscript guidelines and instruction to authors of the journal you submit, is one of the common reasons for 'Rejection' of the article.

Example of references:
Rampal L, Liew BS, Choolani M, Ganasegeran K, Pramanick A, Vallibhakara SA, et al. Battling COVID-19 pandemic waves in six South-East Asian countries: A real-time consensus review. Med J Malaysia 2020; 75(6): 613-25.

NCD Risk Factor Collaboration (NCD-RisC). Worldwide trends in hypertension prevalence and progress in treatment and control from 1990 to 2019: a pooled analysis of 1201 population-representative studies with 104 million participants. Lancet 2021; 11; 398(10304): 957-80.

Tables:
All tables and figures should have a concise title explaining its content and should not occupy more than one printed page. They should be numbered consecutively with Arabic numerals (e.g. Table 1)., and placed after the sections of the manuscript which they reflect, particularly the results which they describe on separate pages. Cite tables in the text in consecutive order. Indicate table footnotes with lower-case letters in superscript font. Place the information for the footnote beneath the body of the table.

Photographs:
Clinical Photographs should conceal the subject's identity. Images should be submitted as separate JPEG files (minimum resolution of 300 dpi). Proof of permission and/or consent from the patient or legal guardian must be submitted with the manuscript. A statement on this must be included as a footnote to the relevant photograph.

Colour reproduction:
Illustrations and diagrams are normally reproduced in black and white only. Colour reproductions can be included if so required and upon request by the authors. However, a nominal charge must be paid by the authors for this additional service; the charges to be determined as and when on a per article basis.

Editorial policy
The journal follows ICMJE and COPE guidelines with regards to concerning its editorial policies on publication ethics, scientific misconduct, consent and peer review criteria. Authors are encouraged to follow the CARE guidelines (for CAse REports).

CONTENTS Page

Case Reports

- Cardiac sarcoidosis presenting as complete heart block and heart failure: Importance of multidisciplinary approach 97
  Izzatul Nadzirah Ismail, Arvindran Alaga, Vijayendran Rajalingam, Saravanan Krishinan
- Melioidosis-associated rasmussen aneurysm in a patient with progressive CKD: Successful management with bronchial artery embolization and adapted eradication therapy 102
  You Hui Wen, Muhammad Danish Syahmi Saha, Noorlina Nordin, Salinawati Bakin, Adib Amir, You Hui Wei
- The blisters and beyond: Adult case of hand, foot, and mouth disease with a surprise twist 107
  Choon Khim Teh, Norazlida Ibrahim, Nor Fadzillah Abd Jalil, Ahmad Tajudin Liza-Sharmini
- Myelin oligodendrocyte glycoprotein antibody-associated disease (MOGAD) masquerading as a quiet optic neuropathy: A case of bilateral vision loss and hearing deficit 117
  Shim Ni Lim, Wan Hazabbah Wan Hitam, Jaya Vani Ettikan, Jack Son Wee, Hayati Abdul Aziz
- Beyond the tear: Acute pericarditis emerging from esophageal perforation 115
  Yi Han Tan, Nurazim Sidi, Mohammad Shukri Jahit, Ainul Syahrilfazli Jaafar
- A large primary dermatofibrosarcoma protuberans of the right upper eyelid: A case report and literature review 119
  Zulkifli Abdul-Azim, A-Rahim Haslinda, Husain Norhalwani, Abdul-Rahim Norhafizah, Ismail Shatriah
- Scurvy-induced severe pulmonary hypertension in a child with autism spectrum disorder: A rare and reversible cause 125
  Nur Zulaika Madon, Putri Yubbu, Mohd Amin Itam
- How immunity shapes mpox severity: Insights from Sarawak Malaysia 128
  Wei Shan Tan, Siti Ayesha Siddiqa Saifuddin, Ingrid Pao Lin Ting, Hock Hin Chua, Min Moon Tang
- Haemorrhagic hamartomatous polyp of the palatine tonsil 132
  Hari KS Krishnan, Azwan Halim B Abdul Wahab, Asmah Hanim Bt Hamdan
- Falsarthrobacter nasiphocae PD-associated peritonitis: A rare pathogen in PD-associated peritonitis 136
  Yi Liang Lim, Gan Wee Fu, YL Lim, WF Gan
- Delayed antiviral therapy in adult varicella: Severe infection and aesthetic implications 139
  Boon Khang Soh, Wei Fai Leong, Wan Aznita Wan Abdullah, Shin Chian Chua, Zhi Xian Cindy Ngu
- Mosaic turner syndrome (45,X/46,XY) presenting as delayed puberty and ambiguous genitalia in an adolescent 143
  Elise Wen Yun Yap, Su Fen Chia, Albert Chao Chiet Tan
- Unravelling invasive fungus: A case report of rhino-orbital mucormycosis in a patient with diabetic ketoacidosis 148
  Muhammad Syazani I, Nazrina H, Lizawati RH, Julieana M
- Severe junctional epidermolysis bullosa in a rural infant: Challenges of diagnosis and management in primary care 151
  Flecia Kundayis, Erna Sazrina Sahirin
- Management challenges of bilateral eye cytomegalovirus (CMV) retinitis in a patient with HIV and multidrug-resistant virological failure: A case report 155
  Nur Azureen Mohd Ali, Julieana Muhammed, Farhana I, Nazrina H

CONTENTS Page

- The great mimicker in the tropics: A case of neuromelioidosis presenting diagnostic challenges in rural Sarawak 158
  Kok Yin Yee, Wong Tze Cheng, Lim Han Hua
- Small cell neuroendocrine carcinoma of Vagina: A rare case report 162
  Nur Khairiyah AR, Lim Yi Jie, Muhammad Noor Asyraf Z, Sim Wee Wee
- Good's syndrome complicated with bronchiectasis with pulmonary hypertension 165
  Chun Fei Yap, Keen Tien Boey, Yi Fan Goh, Say Thin Chu, Jiunn Sheng Chin
- Spotlight on retinoblastoma-related cataracts: A case series 169
  Asma Abdul Razak, Chan Li Yen, Evelyn Tai Li Min, Jamalia Rahmat
- Not every chronic cough is tuberculosis: Congenital diaphragmatic hernia mimicking active tb in an indigenous patient — a diagnostic dilemma in primary care 173
  Hezlin Md Zin, Zahidatul Husna Ali, Siti Maryam Mohd Sallehuddin
- From unresectable to curative resection: Conversion surgery for metastatic oesophagogastric junction gastrointestinal stromal tumour after systemic tyrosine kinase inhibitor therapy 177
  Choon Hui Gan, Kelvin Voon, Ikhwan Sani Mohamad, Premnath Nagalingam
- Common yet rare: dengue fever immediately after coronary artery bypass grafting: A case report 181
  Nazurah Badrul Zaman, Mohd Zamrin Dimon, Mafeitzeral Mamat, Engku Naim Engku Mohd Nasir, Rasidah Senian
- Patch-type kaposi sarcoma as an initial sign of hiv infection with syphilis coinfection: A case report 183
  Nyoman Suryawati, Handelia Phinari, Herman Saputra
- Long-term type 2 diabetes mellitus remission in non-obese patients using a structured low carbohydrate diet programme: A case series of three Malaysian patients 187
  Manvir Singh Gill
- Late complication of bladder outlet obstruction following mid urethral sling with concurrent detrusor underactivity: A case report 191
  Nurul Hikmah MN, Zalina Nusee
- A rare case of placenta praevia percreta of an unscarred uterus in a systemic lupus erythematosus patient 194
  Janisha Silva Raju, Ravichandran Jeganathan
- Clostridium tetani bacteremia without classical tetanus: A lesson from Malaysia 198
  Muhammad Hashemi Dahalan Md Razip, Gan Wee Fu
- Culture-proven Streptococcus viridans endophthalmitis in a healthy child: Challenges in determining the source of infection 203
  Derrick Chuah Jun Quan, Grace Tan Zhen Wen, Akmal Haliza Zamli, Shahidatul-Adha Mohamad
- Pulse corticosteroid therapy in post-keratoplasty graft rejection: A strategy to restore vision 207
  Muhammad Syazani I, Julieana Muhammed
- Bilateral ocular toxoplasmosis in an elderly immunocompetent patient: A rare case of sequential vision loss 210
  Nurul Syafiela Zainuddin, Nor Akmal Bahari, Safinaz Mohd Khialdin

Acknowledgement 214

Cardiac sarcoidosis presenting as complete heart block and heart failure: Importance of multidisciplinary approach

Izzatul Nadzirah Ismail, MRCP (IRE)[1], Arvindran Alaga, FRCP (Edin)[1], Vijayendran Rajalingam, MRCP (UK)[2], Saravanan Krishinan, MRCP (IRE)[2]

[1]Respiratory Department, Hospital Sultanah Bahiyah, Alor Setar, Kedah, [2]Cardiology Department, Hospital Sultanah Bahiyah, Alor Setar, Kedah

SUMMARY

Introduction: Cardiac sarcoidosis is uncommon but causes significant morbidity and mortality. Unfortunately, achieving a definitive diagnosis is challenging. Case presentation: Two gentlemen are presented who complained of syncope due to complete heart block and heart failure. Blood investigations were non-diagnostic, while echocardiography showed poor ejection fraction. Cardiac MRI showed infiltrative heart disease with mediastinal lymphadenopathies. Biopsies of the lymph nodes and lung parenchyma were done through a flexible bronchoscope with endobronchial ultrasound (EBUS). Result: Histopathology showed non-caseating granulomas suggestive of sarcoidosis. Treatment with corticosteroid therapy and dual-chamber pacemaker insertion resulted in resolution of symptoms. Conclusion: Cardiac sarcoidosis should be suspected in patients with conduction problems or non-ischaemic cardiomyopathy. A multidisciplinary team approach is important for definitive diagnosis and proper management. EBUS-FNA provides a minimally invasive and effective method for tissue confirmation.

INTRODUCTION

Sarcoidosis is a systemic inflammatory disease caused by the accumulation of non-caseating granulomas that can occur in various organs. The lung is the most common organ affected, but approximately 5% of patients may have cardiac involvement. Cardiac sarcoidosis is uncommon but deadly. Non-caseating granulomas of sarcoidosis lead to inflammation of the pericardium, endocardium and, most commonly, the myocardium. Progression from focal inflammation to scar formation in the left ventricular free wall and the papillary muscles may result in the development of cardiomyopathies, arrhythmias, and even sudden cardiac death.[1]

Two cases of cardiac sarcoidosis are presented to highlight the importance of multimodal imaging together with biopsy to obtain the diagnosis in highly suspicious patients.

CASE PRESENTATION

Case 1

A 69-year-old Indian gentleman with underlying type 2 diabetes mellitus, hypertension and dyslipidaemia presented to the cardiology team with multiple syncopal attacks in 2018. Full blood counts, renal profiles, electrolyte levels and thyroid function tests were normal. Magnetic resonance imaging (MRI) and magnetic resonance angiography (MRA) of the brain and coronary angiogram were normal. Electrocardiogram (ECG) revealed complete heart block (Figure 1A), and echocardiogram (ECHO) showed dilated right atrium, right ventricle, and left atrium with reduced ejection fraction of 40%. He underwent dual-chamber pacemaker insertion for symptomatic complete heart block. The patient has been well since then with no subsequent syncopal episodes.

However, the patient developed worsening failure symptoms in 2020. Repeated ECHO demonstrated a worsening ejection fraction of 32% with thick left and right ventricles, and ECG showed multiple premature ventricular complexes. Cardiac MRI revealed parietal pericardial enhancement with late gadolinium enhancement (LGE) suggestive of infiltrative heart disease (Figure 1B), while computed tomography (CT) of the thorax showed mediastinal lymphadenopathy (Figure 1C). The patient underwent a positron emission tomography (PET) scan, which revealed metabolically active lesions at the cardiac, mediastinal lymph nodes and spleen.

The patient was referred to the pulmonology team, who performed transbronchial needle aspiration (TBNA) of the lymph node at station 7 using Olympus Vizishot-2 (22G Needle) by linear-endobronchial ultrasound (L-EBUS, BF-UC190F-Olympus, Tokyo, Japan). The patient underwent EBUS-TBNA, during which four passes were performed on the selected node, with 10 to 12 revolutions per pass. Histopathology (HPE) of the lymph node showed chronic granulomatous inflammation – the presence of multiple naked granulomas with occasional Schaumann bodies suggestive of sarcoidosis (Figures 1D and 1E). He was treated with a tapering dose of oral prednisolone (20 mg once daily (OD) for 2 weeks, 15 mg OD for 2 weeks and currently on 10 mg OD) as well as antifailure medications. Subsequent follow-up demonstrated resolution of symptoms and improvement in ejection fraction to 50%.

Case 2

A 54-year-old Indian gentleman working as a barber presented with a near-syncopal episode in December 2013 to the cardiology team. ECG showed complete heart block (Figure 2A). Blood investigation showed normal full blood counts, renal profile, electrolytes and thyroid function test.

This article was accepted: 4 February 2026
Corresponding Author: Izzatul Nadzirah
Email: izzatnadz@gmail.com

Cardiac MRI (Figure 2B) showed thickened myocardium with parietal enhancement and LGE over the lateral, inferoseptal and inferior walls in the midcavity and left ventricle with small pericardial effusion. A coronary angiogram showed normal coronaries, and a dual-chamber pacemaker was inserted in view of his complete heart block. He had not started on any medications then. He was subsequently lost to follow-up for device checks.

In September 2018, he presented again with reduced effort tolerance and bilateral lower limb swelling. ECG showed atrial fibrillation, and ECHO revealed thickened visceral pericardium, pericardial effusion and poor ejection fraction. Investigations for connective tissue disease, tuberculosis, and other infective causes were all negative. Serum angiotensin-converting enzyme (ACE) was also normal. Chest x-ray (CXR) showed bilateral hilar lymphadenopathy (Figure 2C). CT thorax (Figure 2D) demonstrated multiple mediastinal lymphadenopathies and small, calcified granulomas in the right upper lobe. The patient was referred to the pulmonology team, who proceeded with TBNA of the lymph node at station 7 and transbronchial lung biopsy (TBLB) by L-EBUS. Four passes were performed during EBUS-TBNA for the selected node, with 10 to 12 revolutions per pass. HPE of the lymph node and lung parenchyma revealed granulomatous inflammation suggestive of sarcoidosis (Figures 2E and 2F). Ophthalmology assessment revealed bilateral chronic anterior uveitis. He was then diagnosed with sarcoidosis with multiorgan involvement (heart, lung, eye).

The patient was treated with a tapering dose of oral prednisolone (20mg OD for 2 weeks, 15mg OD for 2 weeks, then 10mg OD) and antifailure medications. He succumbed three months later to severe pneumonia, attributed to immunosuppression resulting from prolonged corticosteroid use.

DISCUSSION

Sarcoidosis is an uncommon chronic systemic inflammatory and infiltrative disorder characterised by non-caseating granulomata. A diagnosis of sarcoidosis is based on compatible clinical and radiological findings, histological evidence of non-caseating granulomas and the exclusion of other causes of granulomatous disease. Sarcoidosis is common among adults less than 40 years old and peaks between 20 and 29 years of age, with a modest female predominance.[2] However, both our cases were above the age group, and both were males.

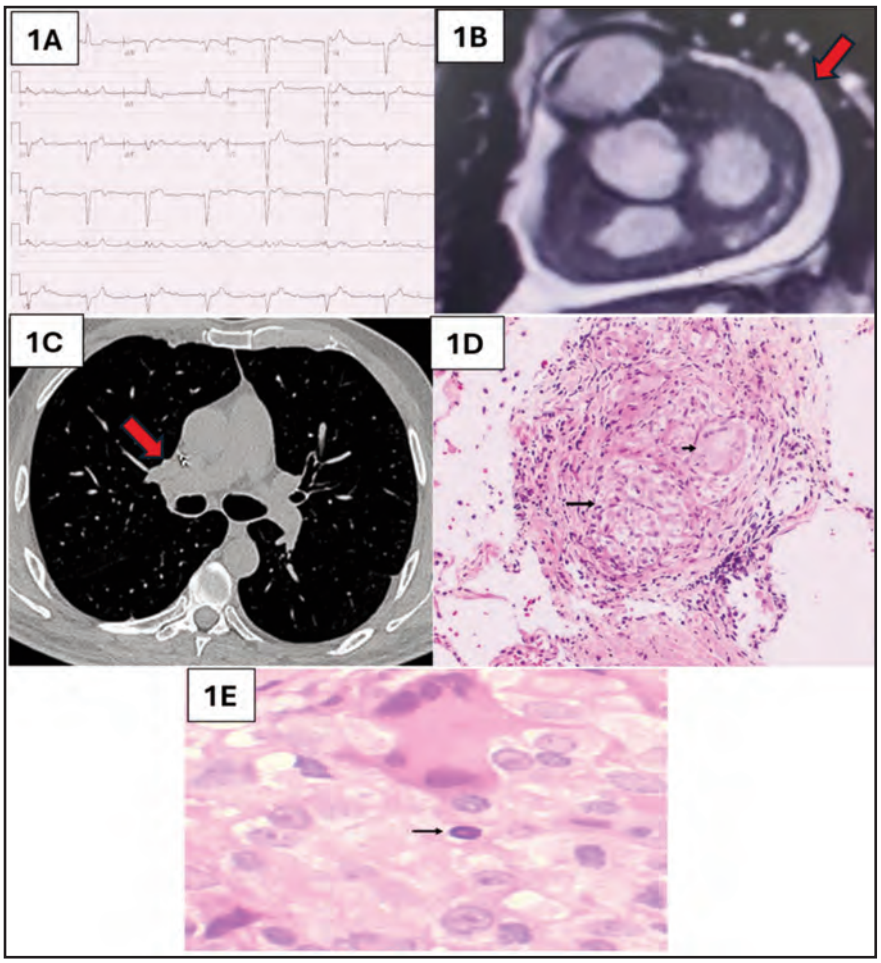

Fig. 1: ECG showing complete heart block (1A), Cardiac MRI showing enhanced parietal pericardium with LGE (1B), CT thorax showing mediastinal lymphadenopathy (1C), HPE lymph node showing naked granuloma with Langhans type multinucleated giant cell (1D) and Schaumann body (1E).

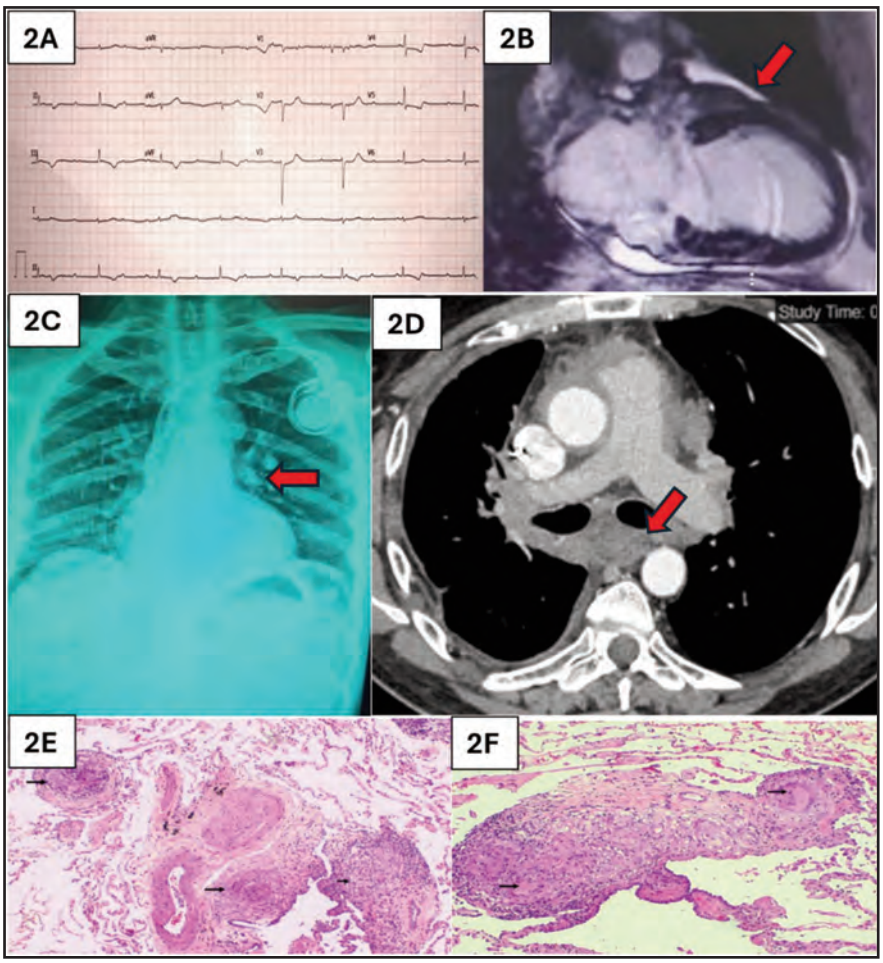

Fig. 2: ECG showing complete heart block (2A), CMRI showing enhanced parietal pericardium with LGE (2B), CXR showing bilateral hilar lymphadenopathy (2C), CT Thorax showing mediastinal lymphadenopathy (2D), EBUS-TBNA HPE showing small tight granulomas within the lung interstitium (2E) and naked granulomas with Langhans type multinucleated giant cells (2F).

A subset of cases involves the heart, which is calculated to be around 5% of patients with systemic disease. Cardiac manifestations vary from conduction abnormalities, ventricular arrhythmias, atypical chest pain, pericarditis, ventricular aneurysms, and congestive cardiac failure to sudden cardiac arrest.[3] The most common sites of involvement in the heart are the interventricular septum base (causing conduction abnormality and heart block), the left free wall (causing aneurysms, heart failure and arrhythmias) and the papillary muscles (causing heart failure).[3] Both of our patients presented with recurrent syncope due to complete heart block and heart failure symptoms.

Cardiac MRI is a striking diagnostic non-invasive method due to its ability to identify small regions of myocardial damage, even with preserved left ventricular systolic function.[1] Presence of LGE on cardiac MRI is the best independent predictor of fatal events, though bigger studies are needed to determine the sensitivity and specificity of screening processes for uncovering asymptomatic cardiac involvement. There is no specific pattern of LGE that is pathognomonic for cardiac sarcoidosis. Hence, images must be interpreted in the context of the patient's history and other relevant investigations under the expertise of a trained cardiologist and/or radiologist.

ACE is produced by epithelioid cells of activated macrophages. Serum ACE levels are often elevated, which may correlate with the total granuloma burden and disease severity but are not specific for sarcoidosis. However, a normal serum ACE level should not exclude the diagnosis, as seen in Case 2. Serum ACE can also be elevated in leprosy, histoplasmosis, hyperthyroidism and lymphoma. ECHO may reveal some abnormalities which may provide a clue to the diagnosis, but it is not specific either. Some of the positive ECHO findings are basal thinning of the ventricular septum, ventricular aneurysm and reduced left ejection fraction.

The most reliable method of diagnosis is via a tissue biopsy of any obvious lesions either from endomyocardium, lymph nodes or other organs. However, because of the scattered nature of the lesions, the diagnostic rate achieved with biopsy in cardiac sarcoidosis is low. Thus, a negative biopsy does not rule out cardiac sarcoidosis. Since the procedure is invasive and not without significant risk, it is done only in selected cases.[3] As illustrated by both cases above, both patients had lesions in the lungs which can be biopsied more safely

Table I: Diagnostic Guidelines for Cardiac Sarcoidosis (JCS 2016 guideline)

Clinical findings defining cardiac involvement

Cardiac findings should be assessed based on the major criteria and the minor criteria. Clinical findings that satisfy the following 1) or 2) strongly suggest the presence of cardiac involvement.

1. Two or more of the five major criteria (a) to (e) are satisfied.
2. One in the five major criteria (a) to (e) and two or more of the three minor criteria (f) to (h) are satisfied

Criteria for cardiac involvement

1. Major criteria

a. High-grade atrioventricular block (including complete atrioventricular block) or fatal ventricular arrhythmia (e.g., sustained ventricular tachycardia, and ventricular fibrillation)
b. Basal thinning of the ventricular septum or abnormal ventricular wall anatomy (ventricular aneurysm, thinning of the middle or upper ventricular septum, regional ventricular wall thickening)
c. Left ventricular contractile dysfunction (left ventricular ejection fraction less than 50%) or focal ventricular wall asynergy
d. 67Ga citrate scintigraphy or 18F-FDG PET reveals abnormally high tracer accumulation in the heart
e. Gadolinium-enhanced MRI reveals delayed contrast enhancement of the myocardium

2. Minor criteria

f. Abnormal ECG findings: Ventricular arrhythmias (non-sustained ventricular tachycardia, multifocal or frequent premature ventricular contractions), bundle branch block, axis deviation, or abnormal Q waves
g. Perfusion defects on myocardial perfusion scintigraphy (SPECT)
h. Endomyocardial biopsy: Monocyte infiltration and moderate or severe myocardial interstitial fibrosis

Diagnostic guidelines for cardiac sarcoidosis

Histological diagnosis group (those with positive myocardial biopsy findings)

1. Cardiac sarcoidosis is diagnosed histologically when endomyocardial biopsy or surgical specimens demonstrate non-caseating epithelioid granulomas.
2. Clinical diagnosis group (those with negative myocardial biopsy findings or those not undergoing myocardial biopsy) The patient is clinically diagnosed as cardiac sarcoidosis (1) when epithelioid granulomas are found in organs other than the heart, and clinical findings strongly suggestive of the above-mentioned cardiac involvement are present; or (2) when the patient shows clinical findings strongly suggestive of pulmonary or ophthalmic sarcoidosis; at least 2 of the five characteristic labouratory findings of sarcoidosis; and clinical findings strongly suggest the above-mentioned cardiac involvement.

Characteristic labouratory findings of sarcoidosis

1. Bilateral hilar (or mediastinal) lymphadenopathy
2. High serum angiotensin-converting enzyme (ACE) activity or elevated serum lysozyme levels
3. High serum soluble interleukin-2 receptor (sIL-2R) levels
4. Significant tracer accumulation in 67Ga citrate scintigraphy or 18F-FDG PET
5. A high percentage of lymphocytes with a CD4/CD8 ratio of > 3.5 in BAL fluid

Diagnostic guidelines for isolated cardiac sarcoidosis

Prerequisite

1. No clinical findings characteristics of sarcoidosis are observed in any organs other than the heart (The patient should be examined in detail for respiratory, ophthalmic, and skin involvements of sarcoidosis. When the patient is symptomatic, other aetiologies that can affect the corresponding organs must be ruled out.).
2. 67Ga scintigraphy or 18F-FDG PET reveals no abnormal tracer accumulation in any organs other than the heart.
3. A chest CT scan reveals no shadow along the lymphatic tracts in the lung or hilar and mediastinal lymphadenopathy (minor axis >10mm).

1. Histological diagnosis group
   Isolated cardiac sarcoidosis is diagnosed histologically when endomyocardial biopsy or surgical specimens demonstrate non-caseating epithelioid granulomas.
2. Clinical diagnosis group
   Isolated cardiac sarcoidosis is diagnosed clinically when the criterion (d) and at least three other criteria (a) to (e) are satisfied

compared to an invasive endomyocardial biopsy. Overall, EBUS-TBNA has sensitivity up to 89% with good diagnostic yield (86%) and negative predictive value (79%). 4EBUS-TBNA is also generally safe for adults, even those above 70 years old. EBUS-TBNA has also shown superiority compared to mediastinoscopy, as it is safer, less invasive and able to sample stations that are difficult to reach by mediastinoscopy, such as hilar and posterior carinal nodes. EBUS-TBNA was preferred for both cases in view of poor ejection fraction, which was deemed high risk for mediastinoscopy under general anaesthesia. Transbronchial cryobiopsy of mediastinal lymph nodes can be utilised in cases of suspected sarcoidosis to yield bigger samples. Endoscopic ultrasound (EUS) fine needle aspiration (FNA) and EBUS FNA also provide high diagnostic yield in sarcoidosis.

On microscopic examination, the granulomas are composed of epithelioid cells and multinucleated giant cells which are characteristically non-caseating. Commonly there are small numbers of surrounding lymphocytes and plasma cells (tight or naked granuloma). The giant cells may contain asteroid bodies, Schaumann bodies or other microcalcifications which are classically seen but not pathognomonic for sarcoidosis.[3] This was clearly demonstrated in both cases.

Sarcoidosis is mainly diagnosed via biopsy (heart or other organs) with other supportive findings such as bilateral hilar lymphadenopathy, high serum ACE level or a CD4/CD8 ratio of >3.5 in bronchoalveolar lavage fluid.[5] Cardiac sarcoidosis is diagnosed based on the Japanese (JCS 2016) guideline for the diagnosis of cardiac sarcoidosis (Table I)5. The guideline defines cardiac sarcoidosis when two or more major criteria are fulfilled or one major and two or more minor criteria.[5] Both our cases fulfilled the criteria of cardiac sarcoidosis based on the guideline. As illustrated by both cases, the diagnosis of cardiac sarcoidosis was challenging at initial presentation, as it requires a high index of suspicion and can only be confirmed via biopsy, which is difficult to obtain, especially in a case of isolated cardiac sarcoidosis.

Immunosuppression with corticosteroids remains the standard therapy for the acute inflammatory phase of cardiac sarcoidosis, but there is an evolving role for steroid-sparing agents. Systemic corticosteroids remain the first-line therapy owing to their efficacy in achieving an excellent clinical response within a shorter timeframe. Non-steroidal agents such as methotrexate, azathioprine, mycophenolate mofetil, leflunomide, cyclosporine or cyclophosphamide may be considered if treatment fails or if patients develop adverse reactions to systemic corticosteroids.[1]

Since cardiac arrhythmias in cardiac sarcoidosis may be fatal, permanent pacemakers (PPM) or implantable cardiac defibrillators (ICD) play an important role in management. Current guidelines recommend ICD implantation in cardiac sarcoidosis patients with sustained ventricular tachycardia, post cardiac arrest, and LVEF of 35% or less, while PPM is suggested for those patients with high atrioventricular blocks. Both our patients had dual-chamber pacemakers inserted, as both initially presented with symptomatic complete heart block.

This case series highlights that cardiac sarcoidosis should be considered in any patient presenting with conduction abnormalities, especially complete heart block or non-ischaemic cardiomyopathy. A multidisciplinary team approach is invaluable for establishing a definitive diagnosis. EBUS-FNA provides a high diagnostic yield in cases of sarcoidosis.

REFERENCES

1. Afriyie-Mensah JS, Awindaogo FR, Tagoe END, Ayetey H. Cardiac sarcoidosis: Two case reports. Clinical Case Report 2021; 9: e04270.
2. Crouser ED, Maier LA, Wilson KC, Bonham CA, Morgenthau AS, Patterson KC, et al. Diagnosis and detection of sarcoidosis. An official American Thoracic Society clinical practice guideline. American Journal of Respiratory Critical Care Medicine 2020; 201: e26-e51.
3. Wan Muhaizan WM, Swaminathan M, Daud MS. Cardiac sarcoidosis: two cases with autopsy findings. Malaysian Journal of Pathology. 2004; 26(1): 59-63.
4. Dugdale I, Tan SL, Niazi M, Lal A, Niazi MBK. Diagnostic yield and safety of EBUS-TBNA: single centre experience over 10 years. European Respiratory Journal 2023; 62(67): 1793.
5. Terasaki F, Azuma A, Anzai T, Ishizaka N, Ishida Y, Isobe M, et al. JCS 2016 Guideline on Diagnosis and Treatment of Cardiac Sarcoidosis. Circulation Journal 2019; 83: 2329-88.

CASE REPORT

Melioidosis-associated rasmussen aneurysm in a patient with progressive CKD: Successful management with bronchial artery embolization and adapted eradication therapy

You Hui Wen, MMed (Internal Medicine)[1], Muhammad Danish Syahmi Saha, MBBS[1], Noorlina Nordin, MMed (Internal Medicine)[2], Salinawati Bakin, MMed (Radiology)[3], Adib Amir (FRCR, UK)[4], You Hui Wei, PhD[5]

[1]Department of Internal Medicine, Hospital Bentong, Pahang, Malaysia, [2]Infectious Disease Unit, Hospital Tengku Ampuan Afzan, Pahang, Malaysia, [3]Interventional Radiology Unit, Hospital Kuala Lumpur, Malaysia, [4]Interventional Radiology Unit, Hospital Sultanah Bahiyah, Kedah, Malaysia, [5]School of Economics and Management, Xiamen University Malaysia

SUMMARY

Melioidosis, caused by Burkholderia pseudomallei, is endemic in Southeast Asia and often complicated by comorbidities such as chronic kidney disease (CKD). Rasmussen aneurysm is a rare but life-threatening vascular complication, typically linked to tuberculosis but occasionally seen in destructive lung infections. A 52-year-old man is reported with poorly controlled diabetes, stage 5 CKD, and prior pulmonary tuberculosis, admitted with fever and productive cough. Blood cultures grew B. pseudomallei, confirming melioidosis. While on renal dose-adjusted ceftazidime, he developed haemoptysis; CT angiography revealed a right upper lobe Rasmussen aneurysm, successfully managed with bronchial artery embolization. Antimicrobial therapy required adaptation due to hyperkalaemia and transaminitis from trimethoprim-sulfamethoxazole (TMP-SMX), prompting temporary switch to amoxicillin-clavulanate. Following dialysis initiation and biochemical stabilisation, TMP-SMX was safely reintroduced and completed for 12 weeks per 2020 Darwin guidelines. The patient remained stable without recurrence at follow-up. This case illustrates the complexity of managing melioidosis in the setting of advanced CKD, the need for tailored antimicrobial strategies, and the lifesaving role of early vascular imaging and intervention in Rasmussen aneurysm. Multidisciplinary coordination across district and tertiary care was important to the favourable outcome.

INTRODUCTION

Melioidosis, caused by *Burkholderia pseudomallei*, is a Gram negative bacillus endemic in Southeast Asia, including Malaysia. It manifests variably, from asymptomatic exposure to fulminant septicemia, and commonly affects individuals with risk factors like diabetes mellitus, chronic kidney disease, and environmental exposure to soil or water.[1] Our patient had multiple such risk factors, including poorly controlled diabetes and CKD.

Pulmonary involvement is frequent, yet haemoptysis is an uncommon presentation, when present, it may signify vascular complications such as Rasmussen aneurysm.[2] Though classically associated with cavitary tuberculosis, similar vascular lesions can occur in destructive lung disease regardless of etiology.

Treatment follows a biphasic approach, with an IV intensive phase followed by oral eradication therapy, typically guided by the Darwin melioidosis protocol. The duration of IV therapy varies based on disease severity and focus, while oral trimethoprim-sulfamethoxazole for at least 12 weeks is recommended during eradication phase.[3] CKD complicates this approach, as it necessitates renal-adjusted dosing, close monitoring for adverse effects (e.g. hyperkalaemia, hepatotoxicity), and occasional substitution of TMP-SMX when intolerance arises.[4]

CASE PRESENTATION

A 52 year old Malay man, current smoker with a 30 pack year history, presented to Hospital Bentong, a district hospital in Pahang with fever and productive greenish cough for two days. He reported previous employment in plantation-based manual labour involving frequent contact with wet soil, a known risk factor for melioidosis exposure. His background includes insulin dependent diabetes mellitus (DM) (poorly controlled), hypertension, dyslipidemia, stage 5 chronic kidney disease (CKD), and a right below knee amputation in 2020 due to diabetic foot ulcer. He completed a 6 month course of anti-tuberculous therapy for pulmonary tuberculosis in 2017.

He had previously been admitted to our centre for evaluation of renal anaemia and acute on chronic kidney disease. He presented with lethargy and haemoglobin of 6.6 g/dL (baseline ≈8.7 g/dL). He denied bleeding, supplement use, constitutional symptoms, chronic cough, or TB contact. At admission, creatinine was 746 µmol/L (eGFR 6.7 mL/min/1.73 m²). He received one unit of packed red cells. Iron studies showed iron and folic acid deficiency. Kidney function improved to creatinine 457 µmol/L (eGFR 12 mL/min/1.73 m²) by discharge.

This article was accepted: 12 March 2026
Corresponding Author: You Hui Wen
Email: hwyou0707@gmail.com

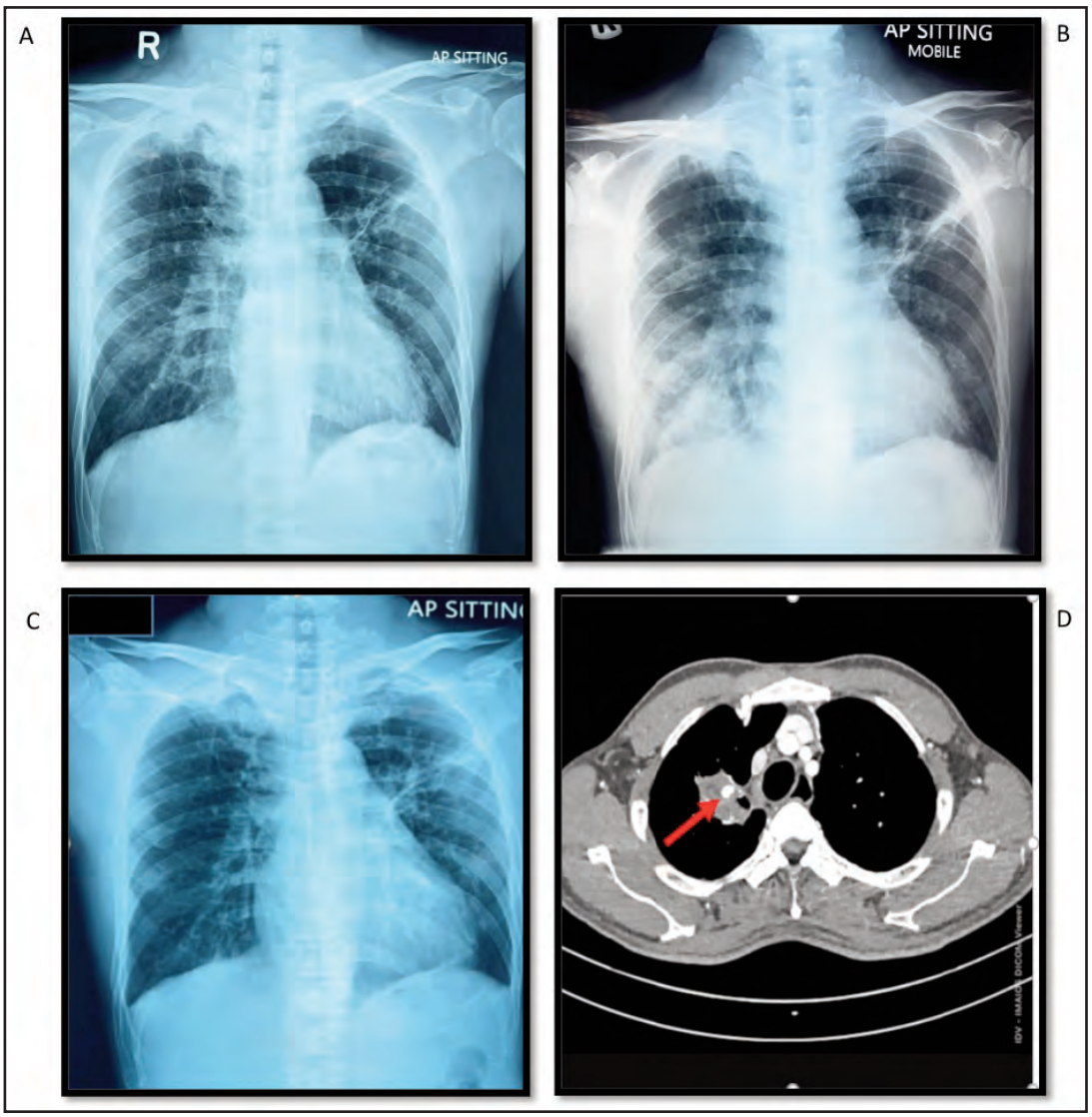

Fig. 1: Serial imaging of the chest demonstrating disease progression and response to treatment.
(A) Initial chest radiograph (CXR) at first presentation shows right upper zone haziness.
(B) CXR during current admission reveals persistent right upper zone haziness with new right lower zone consolidation.
(C) CXR on Day 5 of admission demonstrates radiological improvement following intravenous Ceftazidime therapy.
(D) Axial CT thorax angiography identifies an arterial enhancing lesion (0.6 × 0.9 × 0.6 cm, AP × W × CC), consistent with an aneurysm arising from a segmental branch of the right lobar pulmonary artery.

There was haziness in the right upper zone on the Chest radiograph (Figure. IA) which raised the concern for TB reactivation. Empirical amoxicillin-clavulanate was initiated. TB work-up (three sputum AFB smears, GeneXpert, culture), Mantoux test, HIV, HBsAg, and HCV was negative. After 5 days, he was discharged stable and observed at CKD clinic.

Three months following his initial presentation, the patient re-presented with fever (39.0 °C), productive cough, and bilateral lower limb oedema. He appeared septic but remained alert. He was tachypneic (respiratory rate 22 breaths per minute) and maintained a SpO_2 of 96% on a 60% Venturi mask. Physical examination revealed bilateral basal crepitations, more prominent on the right, along with minimal pitting pedal oedema. Chest radiography (Figure 1B) showed right lower zone consolidation and right hilar prominence. Differential diagnoses at admission included community-acquired pneumonia, reactivation of pulmonary tuberculosis, and bronchogenic carcinoma.

Empirical treatment was initiated with intravenous amoxicillin-clavulanate, basal-bolus insulin, felodipine, antipyretics, cough suppressants, oral sodium bicarbonate, and pantoprazole. Given the presence of bilateral lower limb oedema and advanced chronic kidney disease, intermittent low-dose intravenous frusemide was administered for volume control with prompt clinical and radiographic response. Blood cultures obtained on day 1 grew *Burkholderia pseudomallei*, sensitive to ceftazidime, confirming a diagnosis of pulmonary melioidosis. Amoxicillin-clavulanate was discontinued, and renal dose-adjusted IV ceftazidime (2 g



Fig. 2: Angiographic images demonstrating pre- and post-embolization findings of the right superior intercostal and right intercostobronchial arteries.
(A) Right superior intercostal artery, pre-embolization – abnormal vascularity with evidence of shunting.
(B) Right superior intercostal artery, post-embolization – complete occlusion of the abnormal vascularity and shunting.
(C) Right intercostobronchial artery, pre-embolization – abnormal hypervascularity with shunting.
(D) Right intercostobronchial artery, post-embolization – complete occlusion of the abnormal hypervascularity and shunting.

once daily) was initiated on day 3 in accordance with the Darwin guidelines for melioidosis management.

By day 5, his respiratory status improved, allowing oxygen to be discontinued. A follow-up chest radiograph (Figure 1C) demonstrated significant radiological improvement. Abdominal ultrasound on day 6 showed no evidence of intra-abdominal abscesses. Formal transthoracic echocardiography was not performed, as there were no clinical features suggestive of overt cardiac failure, and the patient demonstrated rapid clinical and radiological improvement following antimicrobial therapy and volume optimisation.

On day 12, eradication therapy with oral trimethoprim-sulfamethoxazole (TMP-SMX) was commenced while intravenous ceftazidime was continued. TMP-SMX was discontinued within 24 hours due to hepatotoxicity and hyperkalaemia with metabolic acidosis. Supportive management with oral calcium polystyrene sulfonate and sodium bicarbonate was provided, and eradication therapy was deferred until clinical parameters had stabilised.

Despite clinical improvement of respiratory symptoms, and after TMP-SMX had already been discontinued, on day 14 of ongoing IV ceftazidime therapy (completing a 14-day intensive phase), the patient developed new-onset haemoptysis with a drop in haemoglobin from 8.3 to 7.6 g/dL, requiring transfusion of one unit of packed red blood cells. A CT thorax angiogram (Figure 1D) performed in week 4 revealed multiple cavitating lesions with surrounding consolidation in the apical segment of the right upper lobe. Notably, a 0.6 × 0.9 × 0.6 cm arterially enhancing lesion consistent with a Rasmussen aneurysm was seen, arising

from a branch of the right upper lobe pulmonary artery. There was no radiological evidence of tuberculosis reactivation, and chronic changes were attributed to prior TB infection.

Due to persistent haemoptysis and concern for aneurysmal rupture, the patient underwent successful bronchial artery embolization in week 5, performed by the Interventional Radiology team at Hospital Kuala Lumpur (Figure 2A–IID). Selective catheterization of the abnormal right intercostobronchial artery and right superior intercostal artery was performed, and the feeding vessel to the aneurysm was occluded with polyvinyl alcohol particles (350–500 µm), achieving complete stasis. Haemoptysis resolved immediately, and no post-procedural complications occurred.

The patient completed a total of 28 days of intravenous ceftazidime treatment in the ward. The prolonged intensive phase was chosen due to bacteraemia, cavitating pulmonary disease, and the development of a vascular complication. Following biochemical stabilisation and after discussion with the infectious disease team at HTAA Kuantan via remote consultation, eradication therapy was reinitiated on day 28 using oral amoxicillin-clavulanate (1875 mg once daily) as a temporary bridging alternative pending biochemical stabilisation.

One week later, the patient experienced deterioration in renal function and hemodialysis was initiated via a right internal jugular catheter. This intervention resulted in normalisation of serum potassium and correction of metabolic acidosis, which allowed the safe reintroduction of TMP-SMX as eradication therapy (Table. I). The patient subsequently completed a full 3-month course of eradication therapy with TMP-SMX without further complications. At follow-up, he remained clinically stable and asymptomatic, with no signs of disease recurrence.

DISCUSSION

Melioidosis, caused by Burkholderia pseudomallei, is endemic to Southeast Asia and northern Australia. Pneumonia and bacteraemia are among its most frequent clinical manifestations.[5] In Malaysia, the disease disproportionately affects individuals with underlying comorbidities especially diabetes mellitus, present in over half of all cases, and chronic kidney disease (CKD), which is associated with a threefold increase in infection risk.[6]

Our patient carried several high-risk features, including poorly controlled diabetes, advanced CKD, and a past history of pulmonary tuberculosis. The combination of pneumonia and bacteraemia placed him at particularly high risk for complications. Local and regional studies have shown that bacteraemic melioidosis can carry mortality rates up to 65%, particularly when complicated by acute kidney injury.6 Both CKD and bacteraemia are known to independently increase the risk of AKI, which is strongly associated with ICU admission and higher mortality.[7]

Diagnosing pulmonary melioidosis can be challenging given its nonspecific symptoms and overlap with TB or malignancy. In our patient, early blood cultures were key to confirming the diagnosis and starting the right treatment, highlighting the importance of prompt cultures and clinical suspicion in endemic areas.

Although in melioidosis pneumonia and bacteraemia without a focus, adding trimethoprim-sulfamethoxazole has not been part of the initial intensive therapy, however, commencement during the intensive phase was necessitated in this case to enable monitoring of adverse events. Trimethoprim-sulfamethoxazole (TMP-SMX) remains the first-line agent for melioidosis eradication; however, its use in advanced CKD is complicated by risks of hyperkalaemia and hepatotoxicity, both of which our patient experienced early in the course.[3] This necessitated a temporary switch to amoxicillin-clavulanate as an alternative agent, albeit one associated with a higher relapse rate. Dosing, however, presents a clinical dilemma in patients with renal impairment.

Although standard renal dosing guidelines typically call for reducing amoxicillin-clavulanate in patients with CKD to minimise toxicity, the consensus statements by Cheng et al. and Chierakul et al. highlight a different priority in melioidosis ensuring adequate drug levels to effectively eradicate the infection, even if higher than standard doses are required.[8] A practical approach was adopted in this patient by administering 1875 mg once daily before dialysis to strike a balance between therapeutic efficacy and safety, particularly given the limitations of a district hospital setting. A particularly rare but life-threatening complication in this case was the development of a Rasmussen aneurysm, a pseudoaneurysm of a pulmonary artery branch adjacent to cavitary lung lesions. Though classically associated with tuberculosis, similar vascular lesions may occur in necrotizing pneumonias, including melioidosis. When ruptured, it can cause massive haemoptysis and carry a mortality rate exceeding 50%.[9] In this case, early detection via CT angiography and prompt bronchial artery embolization were lifesaving.

In Malaysia, melioidosis case fatality rates range from 33% to 54%, with delays in diagnosis and treatment often contributing to recurrence or death.6 Several poor prognostic indicators were identified in this patient, including bacteraemia, leukocytosis, chronic kidney disease, and metabolic acidosis, all of which have been associated with worse outcomes.[10] Despite this, early diagnosis, tailored antimicrobial therapy, and a flexible treatment plan helped avoid adverse outcomes.

This case highlights the complexity of managing melioidosis in patients with severe CKD, especially in resource-limited or district hospital settings. Antimicrobial adjustments, managing renal-related complications, and coordinating referrals to tertiary centres required close collaboration between internal medicine, infectious disease, nephrology, and interventional radiology teams. Remote consultation proved invaluable in decision-making when subspecialty support was not readily available on site. It highlights that

with careful monitoring and interdisciplinary coordination, even high-risk patients with multiple comorbidities can achieve favourable outcomes, even outside of tertiary academic centres.

This case highlights the multidimensional challenges of managing melioidosis in a patient with advanced chronic kidney disease and complex comorbidities in a district hospital setting. From diagnostic uncertainty to antimicrobial toxicity, and the rare complication of a Rasmussen aneurysm, this case demonstrates the importance of early microbiological confirmation, tailored therapy, and timely escalation of care. Despite resource limitations, coordinated collabouration across district and tertiary hospitals, including remote infectious disease consultation and interventional radiology, enabled a favourable outcome. In melioidosis-endemic regions, this case reinforces how timely clinical recognition, personalised antibiotic choices, and adaptable care approaches can make a critical difference for vulnerable patients with underlying CKD. Ultimately, the success of this case reflects not only medical management, but also the strength of interdisciplinary teamwork and continuity of care across levels of the healthcare system.

REFERENCES

1. Cham CY, Choo KS, Rajahram GS, Chang CY. Mycotic aneurysm due to Burkholderia pseudomallei: a case report from Malaysia. Cureus 2025; 17(1): 1-4.
2. Shih SY, Tsai IC, Chang YT, Tsan YT, Hu SY. Fatal haemoptysis caused by a ruptured Rasmussen's aneurysm. Thorax. 2011; 66(6): 553-4.
3. Sullivan RP, Marshall CS, Anstey NM, Ward L, Currie BJ. Review and revision of the 2015 Darwin melioidosis treatment guideline; paradigm drift not shift. PLoS Negl Trop Dis 2020; 14(9).
4. Currie BJ, Janson S, Meumann E, Martin GE, Ewin T, Marshal CS. The 2024 revised Darwin melioidosis treatment guideline. North Territ Dis Control Bull 2023; 30(4): 3-12.
5. Currie BJ. Melioidosis: evolving concepts in epidemiology, pathogenesis, and treatment. Semin Respir Crit Care Med 2015; 36(1): 111-25.
6. Zueter A, Yean CY, Abumarzouq M, Rahman ZA, Deris ZZ, Harun A. The epidemiology and clinical spectrum of melioidosis in a teaching hospital in a north-eastern state of Malaysia: a fifteen-year review. BMC Infect Dis 2016; 16(1): 333.
7. Prabhu RA, Shaw T, Rao IR, Kalwaje Eshwara V, Nagaraju SP, Shenoy SV, Mukhopadhyay C. Acute kidney injury and its outcomes in melioidosis. J Nephrol 2021; 34(6): 1941-8.
8. Chierakul W, Wangboonskul J, Singtoroj T, Pongtavornpinyo W, Short JM, Maharjan B, et al. Pharmacokinetic and pharmacodynamic assessment of co-amoxiclav in the treatment of melioidosis. J Antimicrob Chemother. 2006; 58(6): 1215-20.
9. AM AC. Life-threatening haemoptysis secondary to Rasmussen's aneurysm in an HIV patient. Arch Bronconeumol 2016; 52(8): 439-40.
10. Chayangsu S, Suankratay C, Tantraworasin A, Khorana J. The predictive factors associated with in-hospital mortality of melioidosis: a cohort study. Medicina 2024; 60(4): 654.

Appendix

Table I: Selected Laboratory Parameters during Hospitalization

Biochemical and Hematological Parameters	Admission (Day 1)	TMP-SMX initiation (Day 12)	Post TMP-SMX toxicity	CTA thorax (Week 4)	Post BAE (Week 6)	Post Dialysis (Week 7)
Hemoglobin (g/dL)	8.3	8.0	7.6 ↓ after haemoptysis	8.3	8.4	8.9
White Blood Cell ×10³/µL	14.8	6.9	7.0	6.9	12.7	8.9
Platelets×10³/µL	320	241	236	193	130	183
Erythrocyte sendimentation rate (mm/HR)	>140	-				-
Serum urea (mmol/L)	19.8	30.3	31.0	33.4	39.2↑	12.0 ↓
Serum creatinine (µmol/L)	417 (eGFR ~14 mL/ min/1.730	445 (eGFR ~14 mL/ min/1.73)	443 (eGFR ~14 mL/ min/1.73)	499 (eGFR ~12 mL/ min/1.73)	869 ↑ (eGFR ~5.6 mL/ min/1.73)	450 ↓
Serum Potassium (mmol/L)	3.6	5.3	5.7 ↑	3.6	4.6	3.5
AST (U/L)	32	56	166 ↑	23		23
ALT (U/L)	16	53	120 ↑	19		29
CRP (mg/L)	117.3	51.65		5.0		
Microbiological Culture						
Blood culture	Positive for B. pseudomallei	Repeat cultures negative	-	-	-	-
Sputum AFB/ GeneXpert/ Culture	Negative	-	-	-	-	-
Other test: HIV, HBsAg, HCV	Negative	-	-	-	-	-
PH	7.369	-	7.325	7.25	7.10 ↓	7.30
Bicarbonate	19	-	15	14.3	8.3 ↓	18

The blisters and beyond: Adult case of hand, foot, and mouth disease with a surprise twist

Choon Khim Teh, MBBS[1,2], Norazlida Ibrahim, DrOphth (UKM)[3], Nor Fadzillah Abd Jalil, MMed (Ophth)[3], Ahmad Tajudin Liza-Sharmini, MMed PhD[1,2]

[1]Department of Ophthalmology and Visual Science, School of Medical Sciences, Universiti Sains Malaysia, Kubang Kerian, Kelantan, Malaysia, [2]Hospital Pakar Universiti Sains Malaysia, Kubang Kerian, Kelantan, Malaysia, [3]Department of Ophthalmology, Hospital Melaka, Melaka, Malaysia

SUMMARY

Hand, foot, and mouth disease (HFMD) is a highly contagious viral illness caused by coxsackievirus. HFMD primarily affects children and is rarely seen in adults. Unilateral acute idiopathic maculopathy (UAIM), a rare inflammatory disorder of the retinal pigment epithelium (RPE), has been associated with HFMD. This case report describes a rare occurrence of UAIM in an adult patient with HFMD. A 36-year-old man with underlying hypertension, presented with sudden onset, painless and non-progressive central vision loss of the right eye. There was a history of self-limiting fever associated with an acute maculopapular rash and blisters over bilateral palms and soles. He had history of contact with his one-year-old son, who was diagnosed with HFMD recently. His visual acuity was counting finger OD and 6/9 OS on presentation at the eye clinic. There was right central scotoma on confrontation test. Fundus examination showed an irregular yellowish-greyish macular lesion. The retinal pigmented epithelium (RPE) was thickened with hyperreflectivity debris on the apical end and disruption of ellipsoid zone subfoveal area on optical coherence tomography (OCT). Fundus fluorescein angiography (FFA) showed early phase of patchy area of irregular hypofluorescent subfoveal area, with surrounding hyperfluorescent at the late phase. He was treated with tapering dose of oral prednisolone for two months. On follow-up, his vision improved to 6/9 with marked resolution of maculopathy. Acute maculopathy is rare in HFMD and challenging to diagnose in adults. Higher index of suspicious and multimodal imaging aids in the diagnosis.

INTRODUCTION

Hand, foot, and mouth disease (HFMD) is a highly contagious viral illness caused by coxsackievirus from the enterovirus family. The species responsible for HFMD belongs to enterovirus species A, with enterovirus A71 accounting for more than 90% of cases. The remaining cases are mainly caused by coxsackievirus A16.[1] HFMD primarily affects children and is rarely seen in adults. Diagnosis of HFMD is mainly based on clinical presentation but involvement of the eye is rare. There have been reports of unilateral acute idiopathic maculopathy (UAIM) associated with HFMD.[2,3] UAIM is a rare inflammatory disease of the retinal pigment epithelium (RPE) that affects healthy young adults, without any preference for sex or race. It is commonly observed on ophthalmic imaging as a disruption of the retinal pigment epithelium (RPE), accompanied by an exudative detachment of the neurosensory retina, affecting central vision. Papillitis, retinal hemorrhages, and mild vitritis, have also been reported.[2]

CASE PRESENTATION

A 36-year-old man with well-controlled hypertension presented with sudden-onset, painless, and non-progressive central vision loss in his right eye for five days. He presented to the emergency department on the first day of symptom onset and was referred to the eye clinic for further assessment following review by the ophthalmology medical officer. Three weeks prior to this, he experienced a self-limiting low-grade fever lasting for five days, accompanied by an acute maculopapular rash and blisters on both palms and soles but no oral ulcers. During this episode, he did not seek medical attention but practised self-isolation. He had history of recent contact with his one-year-old son, who had been diagnosed with HFMD and successfully treated.

At presentation, he was afebrile, with a blood pressure of 110/80mmHg. There were no visible maculopapular rashes, blisters, or oral ulcers. His visual acuity was counting fingers in the right eye (OD) and 6/9 in the left eye (OS), with no relative afferent pupillary defect. A confrontation test revealed a right central scotoma. Anterior segment examination and intraocular pressure in both eyes were within normal limits. Fundus examination of the right eye revealed an irregular yellowish-grey macular lesion (Fig. 1a). The optic disc was pink with well-defined margin and a cup-disc ratio of 0.3. There was no evidence of papillitis, retinitis, macular detachment, retinal hemorrhages, or hypertensive retinopathy. Both anterior and posterior segments of the left eye were unremarkable.

Spectral domain optical coherence tomography (SD-OCT) showed thickening of the retinal pigment epithelium (RPE), hyperreflective debris at the apical end, and disruption of the ellipsoid zone in the subfoveal area (Fig. 2a). This was consistent with RPE inflammation but without evidence of subretinal or intraretinal fluid. Fundus fluorescein angiography (FFA) revealed a patchy area of irregular hypofluorescence in the subfoveal region during the early

This article was accepted: 19 March 2026
Corresponding Author: Liza Sharmini Ahmad Tajudin
Email: liza@usm.my

Table I: Summary of reported cases of unilateral acute maculopathy associated with adult onset of hand, foot, and mouth disease.

Reference	Number of case(s)	Age	Sex	Duration of onset (Days)	Eye	Initial VA (Snellen chart)	Final VA (Snellen chart)	OCT finding	Treatment
Yen et al., 2023[3]	1	23	M	5	OS	6/48	6/60	Heterogeneous hyperreflective thickening of the outer retina and RPE in the foveal region with loss of ellipsoid zone	Nil
Duman et al., 2016[4]	1	24	M	3	OS	6/60	6/6	Disruption of the IS-OS junction and hyperreflective debris at the apical end of RPE	Nil
Yannuzzi et al., 1991[5]	9	15-45	4 M 5 F	2-5	NR	6/18- CF	6/6- 6/60	Subfoveal NSR detachment with thickened RPE	Nil *
Miguel et al., 2011[6]	1	25	M	NR	OD	6/6 †	6/5	Thickened RPE and hyperreflective RPE lesion protruding into IS-OS junction	Oral corticosteroid
Agrawal et al., 2015[7]	1	35	F	1	OD	6/24	6/6	Dumb-bell-shaped lesion with disruption of the IS-OS junction and hyperreflective debris at the apical end of RPE	Oral corticosteroid
Demirel et al., 2014[8]	1	30	M	3	OD	6/15	6/7.5	Subfoveal NSR detachment with with mild intraretinal cystic changes. Disruption of IS-OS junction and RPE layer	Nil
Jung et al., 2012[9]	1	27	F	1	OD	6/60	6/6	Subfoveal NSR detachment with disruption of IS-OS junction and hyperreflective debris at the apical end of RPE	Nil
Hughes et al., 2012[10]	1	19	F	3	OD	CF	6/6	Subfoveal NSR detachment with disruption of IS-OS junction and hyperreflective in the subretinal space with irregularity of the RPE	Nil
Our case	1	36	M	5	OD	CF	6/9	Disruption of the ellipsoid zone and hyperreflective debris at the apical end of thickened RPE	Oral corticosteroid

NR: Not reported, NSR: Neurosensory retina, CF: Counting finger.
* One patient was treated with oral corticosteroid and a nearly instant recovery in vision was observed.
† Good VA due to very early stage of the disease, absence of serous macular detachment and slight eccentricity of the RPE lesion.

phase (Fig. 3a), with surrounding hyperfluorescence in the late phase, suggesting the potential of exudative detachment (Fig. 3b). However, no microbiological confirmation of coxsackievirus was sought from vitreous or aqueous samples. A clinical diagnosis of unilateral acute idiopathic maculopathy (UAIM) associated with HFMD was established. The patient was treated with a tapering dose of oral prednisolone (1 mg/kg) over two months due to poor visual acuity at presentation. After one month of steroid therapy, his vision improved to 6/9. There was marked improvement in macular lesion (Fig. 1b) and resolution of maculopathy on OCT findings (Fig. 2b). The left eye remained unaffected throughout the follow-up period.

DISCUSSION

Coxsackievirus is a human enterovirus that spreads primarily via oral ingestion of virus shed from the gastrointestinal or upper respiratory tract of infected hosts, or through vesicular fluid and oral secretions. The virus is most contagious during the first week of illness, with symptoms typically manifesting several days after exposure. Once ingested, the virus multiplies in the lymphoid tissues of the lower intestine and pharynx, subsequently spreading to regional lymph nodes. Although rare, viral dissemination to various organs — including the eyes, heart, liver, skin and central nervous system — may result in encephalitis, polio-like syndrome, acute transverse myelitis, Guillain-Barre syndrome, benign intracranial hypertension, and acute cerebellar ataxia.

Most patients with HFMD experience a mild illness and recover within seven to ten days without complications. Classic HFMD is characterized by low-grade fever, malaise, a maculopapular rash or blisters on the hands, soles, and buttocks, and painful ulcerative lesions in the throat, mouth, and tongue. While fever typically resolves within two days, rashes and sores may take up to a week to heal. Notably, many patients with HFMD present with only one or two of these symptoms as in this case.[1]

Unilateral acute idiopathic maculopathy (UAIM) is an inflammatory maculopathy involving the outer retina, retinal pigment epithelium (RPE), and choroid without specific aetiology. Studies have demonstrated that Coxsackievirus B3 can directly infect the RPE in vitro, with its proteins triggering host immune responses.[3,4] Immune-mediated damage is another proposed mechanism underlying the pathogenesis of UAIM.[4] UAIM typically presents with sudden central vision loss, often preceded by a

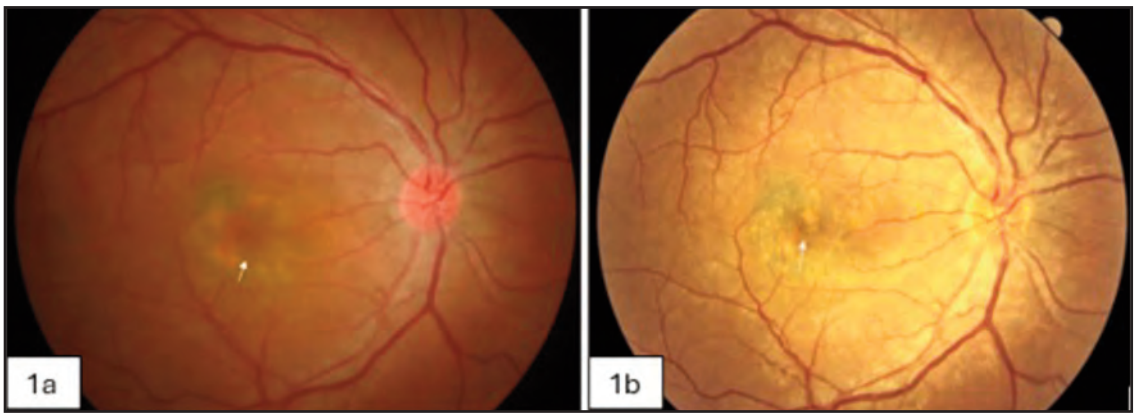

Fig. 1: 1a show irregular yellowish-greyish macular lesion (arrow). 1b show yellowish-greyish macular lesion (arrow) become smaller and more discrete at 12th week

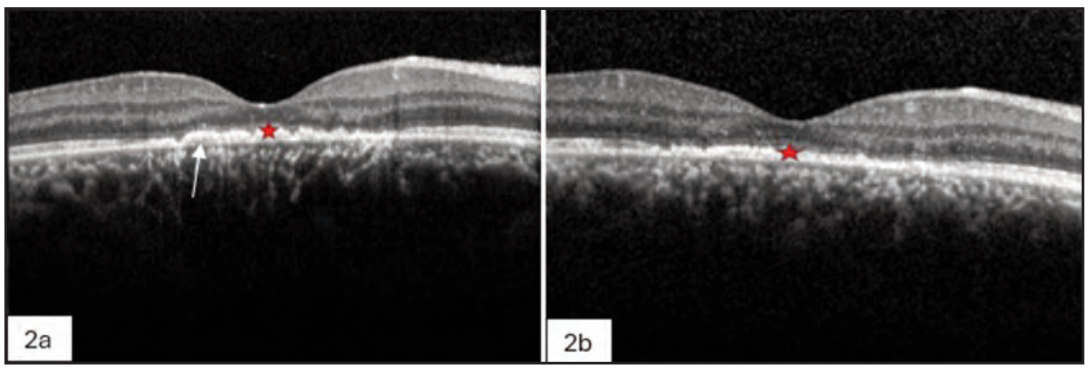

Fig. 2: 2a show thickened RPE with hyperreflectivity debris (arrow) on the apical end of and disruption of ellipsoid zone at the subfoveal area (star). 2b show reduced thickening of RPE and more prominent ellipsoid zone (star) at 12th week

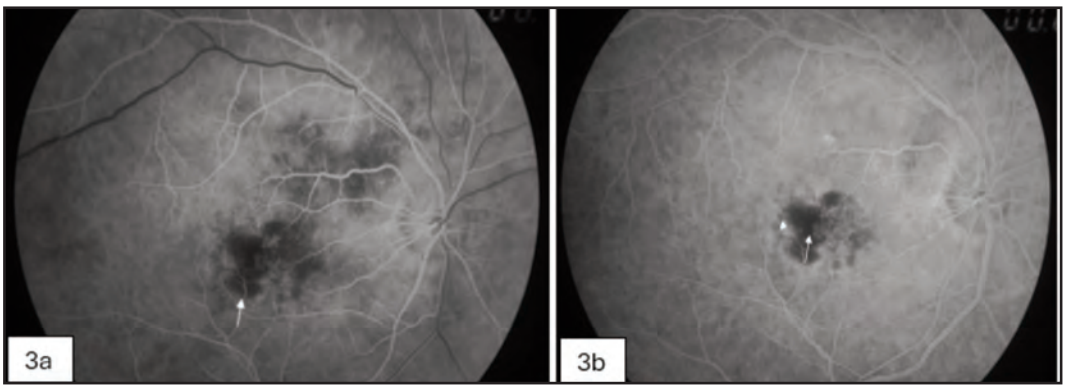

Fig. 3: 3a show early irregular patchy area of hypofluorescent (arrow) at the subfoveal area (16 second). 3b show late irregular hypoflorescent area (arrow) surrounding the hyperfluorescent area (arrow head) (23 second)

prodromal illness. Most patients experience significant visual recovery within several weeks. UAIM was first described by Yannuzzi et al. in 1991. He described nine patients with sudden, unilateral severe visual loss, macular serous detachment, and central scotoma.[5] Seven of these patients had a brief viral or flu-like illness preceding their ophthalmic symptoms.

There was reported case of UAIM without an initial systemic illness, during pregnancy and post vaccination such as COVID-19 vaccination.[6] This clinical variability makes the diagnosis of UAIM challenging. The important differentials include central serous chorioretinopathy (CSCR), Vogt–Koyanagi–Harada disease and placoid syphilitic retinitis, which can usually be differentiated from UAIM by their characteristic pattern in FFA.

To date, a total of 17 cases of UAIM associated with HFMD have been reported including the present report (Table I). These cases involved young adults aged 15–45 years, with a slight male predominance (male-to-female ratio of 9:8). Similar to the present case, visual symptoms were acute,

lasting between one to five days with involvement of unilateral macular. It is hypothesised that the clinical manifestations of HFMD-related UAIM depend on the disease stage. In the early phase, subfoveal neurosensory retinal detachment results in visual disturbance. Over time, the detachment resolves, leaving thickened RPE and ellipsoid zone disruption, which gradually normalise as the disease progresses. Reduction in hyperreflective debris and improvement in visual acuity further support this proposed progression. Other reported findings include intraretinal hemorrhages, papillitis, and vitreous cells.

Changes of the macula in UIAM can be monitored by fundus photographs and other imaging modalities in ophthalmology including OCT, FFA, fundus autofluorescence (FAF) and indocyanine green angiography (ICGA). Agrawal et al. described FAF findings, noting a complex heterogeneous pattern of hyper- and hypo-autofluorescence with clear demarcation lines. As the disease resolved and visual acuity improved, FAF showed increased hypo-autofluorescence, indicating RPE loss. ICGA revealed irregular heterogeneous patches of hypofluorescence corresponding to the macular lesions. However, such retinal alterations are not unique to Coxsackievirus; similar findings have been reported in association with other viral pathogens, including Dengue virus.[7]

In the present case, HFMD was diagnosed clinically. The definitive diagnosis can be done by serological detecting the presence of coxsackievirus but not essential in the management of HFMD. UAIM shares some clinical features with CSCR, making it an important differential diagnosis in cases of subfoveal detachment with fever and flu-like symptoms. Most reported cases of CSCR and UAIM resolve spontaneously within three to 12 weeks of follow-up.

The prognosis of UAIM is generally favourable, with most cases resolving spontaneously without treatment within weeks to months. Treatment is usually initiated if the presenting visual acuity is poor and extensive maculopathy as demonstrated in Table I. Although rare, extensive maculopathy may cause permanent foveal atrophy with residual central scotoma, and in some cases complicated by choroidal neovascularization and macular scarring, resulting in long-term visual impairment. Oral prednisolone may expedite recovery in patients with significant visual loss. In our patient, corticosteroid therapy was tapered over two months, with final visual acuity improving to 6/9 after 12 weeks of follow-up.[2,4]

In summary, HFMD-associated UAIM is a self-limiting condition with good visual recovery. Early recognition of ocular involvement and timely referral from primary care are essential, as vision-threatening differential diagnoses cannot be reliably excluded at initial presentation. This case illustrates that Coxsackievirus, beyond its well-known manifestations in hand, foot, and mouth disease, can also affect the eyes. Prompt ophthalmic assessment is therefore essential, as it enables appropriate management and supports favorable visual recovery.

REFERENCES

1. Mirand A, Henquell C, Archimbaud C, Ughetto S, Antona D, Bailly JL, et al. Outbreak of hand, foot and mouth disease/herpangina associated with coxsackievirus A6 and A10 infections in 2010, France: a large citywide, prospective observational study. Clin Microbiol Infect 2012; 18(5): E110-8.
2. Freund KB, Yannuzzi LA, Barile GR, Spaide RF, Milewski SA, Guyer DR. The expanding clinical spectrum of unilateral acute idiopathic maculopathy. Arch Ophthalmol 1996; 114(5): 555-9.
3. Yen CY, Fang IM. Unilateral acute idiopathic maculopathy related to hand-foot-mouth disease: Case report and literature review. Taiwan J Ophthalmol 2023; 14(1): 133-6.
4. Duman R, Duman N, Kutluksaman B, Çetinkaya E, İnan S, İnan ÜÜ. A review of unilateral acute idiopathic maculopathy related to hand, foot and mouth disease with a representative case. Int Ophthalmol 2016; 36(3): 445-52.
5. Yannuzzi LA, Jampol LM, Rabb MF, Sorenson JA, Beyrer C, Wilcox LM Jr. Unilateral acute idiopathic maculopathy. Arch Ophthalmol 1991; 109(10): 1411-6
6. de la Fuente MA, Cuadrado R. Unilateral acute idiopathic maculopathy: angiography, optical coherence tomography and microperimetry findings. J Ophthalmic Inflamm Infect 2011; 1(3): 125-7.
7. Agrawal R, Bhan K, Balaggan K, Lee RW, Pavesio CE, Addison PK. Unilateral acute maculopathy associated with adult onset hand, foot and mouth disease: Case report and review of literature. J Ophthalmic Inflamm Infect 2015; 5(1): 2.
8. Demirel S, Batioğlu F, Özmert E, Batioglu F. Unilateral acute maculopathy related to hand, foot, and mouth disease: OCT and fluorescein angiography findings of a very rare disease. Eur J Ophthalmol 2014; 24(1): 131-3.
9. Jung CS, Payne JF, Bergstrom CS, Cribbs BE, Yan J, Hubbard GB 3rd, Olsen TW, Yeh S. Multimodality diagnostic imaging in unilateral acute idiopathic maculopathy. Arch Ophthalmol 2012; 130(1): 50-6.
10. Hughes EH, Hunyor AP, Gorbatov M, Ho IV. Acute idiopathic maculopathy with coxsackievirus infection. Retin Cases Brief Rep 2012; 6(1): 19-21.

Myelin oligodendrocyte glycoprotein antibody-associated disease (MOGAD) masquerading as a quiet optic neuropathy: A case of bilateral vision loss and hearing deficit

Shim Ni Lim[1,2], Wan Hazabbah Wan Hitam[1], Jaya Vani Ettikan[2], Jack Son Wee[3], Hayati Abdul Aziz[2]

[1]Department of Ophthalmology & Visual Science, School of Medical Sciences, Health Campus, Universiti Sains Malaysia, Kubang Kerian, Kelantan, Malaysia, [2]Department of Ophthalmology, Hospital Sultanah Aminah, Johor Bahru, Johor, Malaysia, [3]Department of Neurology, Hospital Sultanah Aminah, Johor Bahru, Johor, Malaysia

SUMMARY

Myelin oligodendrocyte glycoprotein antibody-associated disease (MOGAD) is a demyelinating disorder causing oligodendropathy, often presenting with severe optic disc swelling. We describe a diagnostically challenging case lacking this hallmark feature, instead presenting as a quiet bilateral optic neuropathy with rare concurrent auditory involvement. A 38-year-old man presented with profound, sequential, painless bilateral vision loss over two weeks, accompanied by hearing impairment. Visual acuity was reduced to hand movements in the right eye and vague light perception in the left eye. No relative afferent pupillary defect was detected. Anterior segment examination was unremarkable. Fundus examination appeared deceptively normal, showing only subtle temporal pallor. Pure tone audiometry confirmed bilateral sensorineural hearing loss. Serum and cerebrospinal fluid tested positive for anti-MOG antibodies. Optical coherence tomography was initially normal, while visual evoked potentials showed delayed P100 latencies. Magnetic resonance imaging revealed extensive T2/FLAIR hyperintensities involving the posterior visual pathway, brainstem and cranial nerve. The patient received high-dose intravenous methylprednisolone followed by plasma exchange and intravenous immunoglobulin due to inadequate response. He was discharged on tapering oral corticosteroids and commenced on mycophenolate mofetil for long-term immunosuppression. At discharge, vision remained poor. At eight months, vision improved to 6/45 (right eye) and 6/60 (left eye), with optic nerve atrophy and partial recovery of hearing. This case highlights an atypical MOGAD presentation without optic disc oedema, complicated by rare auditory involvement. Early recognition and timely treatment are vital to preserve neurological and visual function.

INTRODUCTION

Myelin oligodendrocyte glycoprotein antibody-associated disease (MOGAD) is a recently defined demyelinating disorder of central nervous system, increasingly recognized for its broad clinical and radiological spectrum. The estimated global incidence ranges from 1.6 to 4.8 per million per year, with a prevalence of 1.3 to 2.5 per 100,000 population.[1] In Malaysia, the prevalence is reported as 0.12 per 100,000 persons.[2]

MOGAD typically presents with optic neuritis (ON), transverse myelitis, and acute disseminated encephalomyelitis (ADEM). MOGAD-associated optic neuritis (MOGAD-ON) commonly manifest as severe, often bilateral vision loss with prominent optic disc oedema and significant periorbital pain. Ancillary testing such as optical coherence tomography (OCT) often demonstrates marked retinal nerve fibre layer (RNFL) thickening in the acute phase.[1,3]

The expanding recognition of atypical presentations underscores significant diagnostic challenges. Atypical cases lacking characteristic features may lead to delayed diagnosis and suboptimal outcomes. A rare case of MOGAD is described herein presenting as a bilateral, painless optic neuropathy without disc oedema, accompanied by bilateral sensorineural hearing loss — an association seldom reported.

CASE PRESENTATION

A 38-year-old previously healthy man presented with progressive, painless bilateral visual loss over two weeks. The symptoms began with blurring of vision in the left eye, which he initially noticed as peripheral visual loss while typing a report at work and progressed to generalized visual loss. He did not seek immediate medical attention and self-medicated with over-the-counter eye drops. One week later, blurring of vision developed in the right eye. Concurrently, he developed bilateral hearing loss, worse on the left, without other otologic symptoms. There was no photopsia, heat-induced worsening of vision, ocular pain, or neurological deficits. There was no history of recent illness, vaccination, or high-risk behaviours.

The patient was alert with no meningism or focal neurological deficits. Visual acuity was markedly reduced to hand movement in the right eye and vague light perception in two quadrants in the left eye. Pupillary reactions were sluggish bilaterally, without a relative afferent pupillary

This article was accepted: 12 March 2026
Corresponding Author: Wan Hazabbah Wan Hitam
Email: hazabbah@usm.my

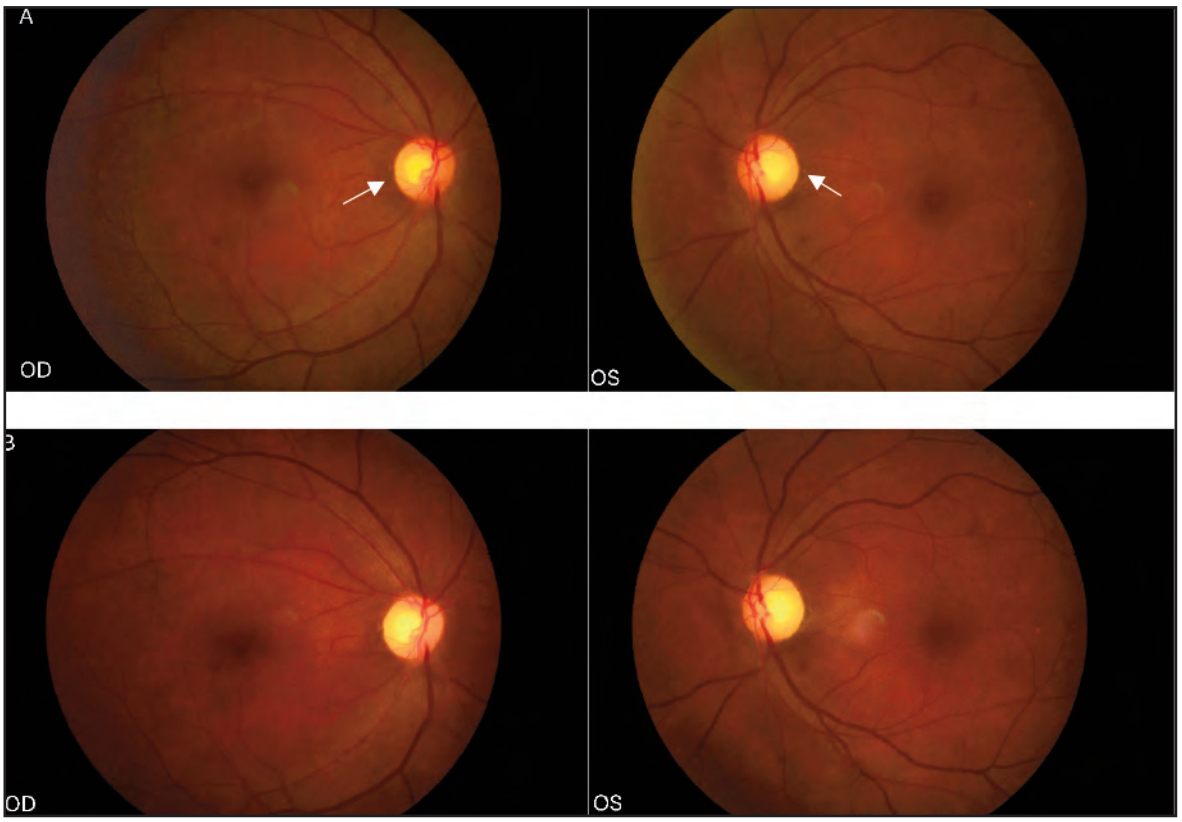

Fig. 1: Fundus photographs at initial presentation and eight-months follow-up. (A) Temporal optic disc pallor (white arrow) at presentation. (B) Partial optic nerve atrophy at eight months

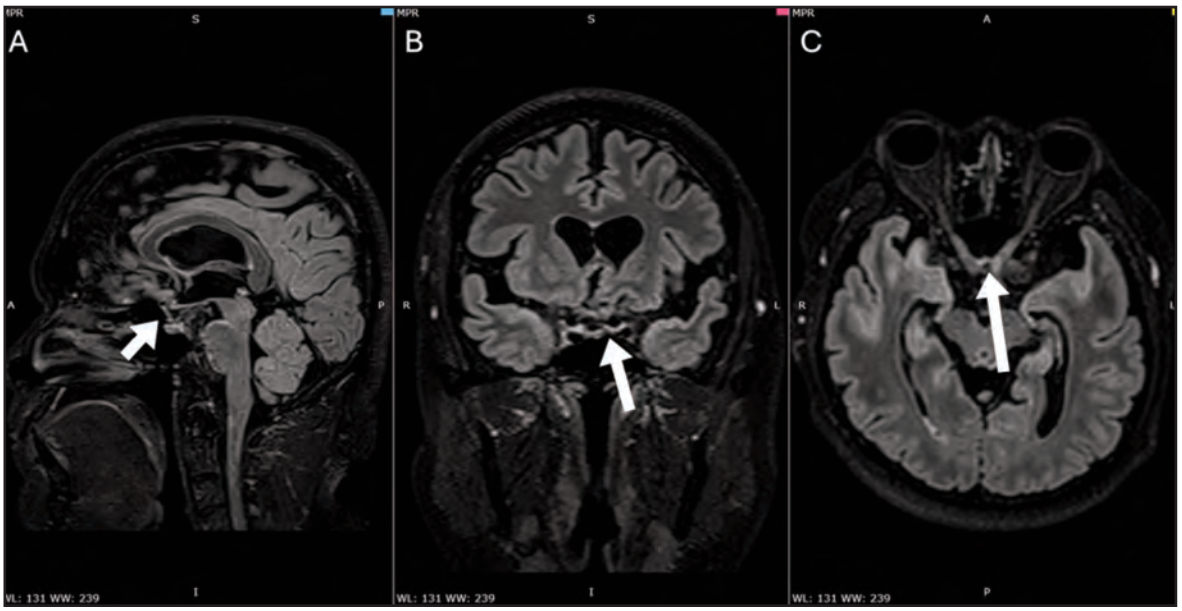

Fig. 2: T2/FLAIR MRI brain and orbit images showing hyperintensity in the optic chiasm (arrow)

defect. Anterior segment examination was unremarkable. Fundus examination showed subtle bilateral temporal optic disc pallor without disc oedema, haemorrhages, or signs of intraocular inflammation (Figure 1A). Extraocular movements were full. Colour vision and visual field could not be assessed due to profound vision loss. Pure tone audiometry confirmed left mild-to-profound and right mild-to-moderate high frequency sensorineural hearing loss.

Given the subacute, progressive bilateral visual loss, inflammatory optic neuropathy — including optic neuritis — was considered. Other differential diagnoses included compressive, infiltrative, and hereditary causes (e.g., Leber hereditary optic neuropathy). In view of the "quiet" fundus appearance despite profound vision loss, extensive investigations were performed.

Serum anti-MOG antibodies were positive as detected by the Euroimmun indirect immunofluorescence assay. Cerebrospinal fluid (CSF) analysis showed anti-MOG antibodies at a titre of 1:40, with normal opening pressure and no pleocytosis. Serum aquaporin-4 antibodies and genetic testing for LHON were negative. Infective and autoimmune screens were unremarkable. Cerebrospinal fluid (CSF) polymerase chain reaction (PCR) testing was performed to exclude infectious aetiologies of optic neuropathy and brainstem involvement. Pathogens tested included herpes simplex virus, varicella-zoster virus, cytomegalovirus, enterovirus, human parechovirus, Streptococcus agalactiae, Streptococcus pneumoniae, Haemophilus influenzae, Neisseria meningitidis, Listeria monocytogenes, Escherichia coli, Cryptococcus neoformans, and Mycobacterium tuberculosis. All CSF PCR assays and cultures were negative. Oligoclonal bands could not be tested due to insufficient sample volume.

Magnetic resonance imaging (MRI) demonstrated confluent T2/FLAIR hyperintensities involving the optic nerves, optic chiasm, and post-chiasmatic tracts (Figure 2) with additional lesions in the brainstem and cranial nerve III, IV, and V. Contrast-enhanced CT was normal. Visual evoked potentials showed prolonged P100 latency. OCT revealed normal RNFL thickness (right: 91 µm; left: 100 µm).

Intravenous methylprednisolone (1 g/day for five days) was initiated two weeks after symptom onset. Owing to an inadequate response, the patient underwent five cycles of plasma exchange followed by intravenous immunoglobulin (IVIG) at 0.4 g/kg/day for five days. Visual acuity remained at counting fingers in the right eye and hand movement in the left eye at the time of discharge. High-dose oral prednisolone was continued, with gradual tapering commencing after one month and commenced on mycophenolate mofetil for relapse prevention.

At eight months, visual acuity improved to 6/45 (right eye) and 6/60 (left). Fundus examination showed optic atrophy (Figure 1B). RNFL thinned to 72 µm (right) and 74 µm (left). Repeat audiometry showed residual bilateral mild-to-moderate sensorineural hearing loss with subjective improvement.

DISCUSSION

MOGAD is mediated by autoantibodies against the MOG protein on oligodendrocytes, leading to demyelination via complement activation and antibody-dependent cellular cytotoxicity. Histopathologically, $CD4^+$ T-cell–predominant infiltration with macrophages and complement deposition is typically observed.[1,4] The precise trigger remains uncertain, with infection or vaccine-related molecular mimicry being the most widely proposed mechanism.[1]

This case demonstrates a rare presentation of MOGAD-ON with severe bilateral vision loss without disc oedema or pain. Normal acute-phase RNFL thickness may mislead clinicians toward non-inflammatory aetiologies. Although RNFL >118 µm may help distinguish MOGAD-ON from MS-related optic neuritis5; normal RNFL measurements do not exclude MOGAD, as highlighted here.

MOGAD-ON commonly presents with marked optic disc oedema; however, this feature is not invariably present. The absence of optic disc oedema in the patient likely attributable to predominant retrobulbar involvement affecting the posterior optic nerve, optic chiasm and post-chiasmatic pathways, as demonstrated on MRI. Furthermore, delayed presentation may have allowed acute inflammatory oedema to subside before clinical evaluation, resulting in early optic disc pallor.

Sensorineural hearing loss in MOGAD is exceedingly rare; a Korean cohort reported a 4.2% prevalence.[6] Auditory dysfunction may reflect demyelination of central auditory pathways or involvement of the vestibulocochlear nerve.[7-8] MRI in this patient supported both mechanisms.

MOGAD-ON typically shows longitudinally extensive optic nerve lesions.[1,3-4] Cranial nerve involvement and brainstem lesions, as seen here, indicate multifocal disease. According to the 2023 international MOGAD diagnostic criteria,[9] low-positive MOG-IgG titres require compatible clinical and radiologic findings — all of which were fulfilled in this case.

High-dose corticosteroids are first-line therapy.[1] Steroid-refractory cases may benefit from plasma exchange or intravenous immunoglobulin (IVIG).[1,3] Early treatment improves outcomes; conversely, delays worsen RNFL loss and visual prognosis.[3] Despite timely therapy, recovery was limited, likely due to posterior pathway involvement.

Long-term, slow steroid tapering (>6 months at ≥20 mg/day) reduces relapse risk.[3] Steroid-sparing agents, including mycophenolate mofetil, further reduce relapse frequency when used in conjunction with low-dose corticosteroids.[3-4] Our patient remained relapse-free on dual therapy.

Visual prognosis in MOGAD is typically better than in NMOSD-ON.[10] Poor prognostic factors include bilateral onset, delayed treatment and brainstem involvement.[3,10] Persistent antibody positivity may indicate an elevated relapse risk, but is not a reliable predictor of prognosis.[1,4]

The prognosis for auditory recovery in MOGAD remains uncertain, owing to the rarity of reported cases. Available

data suggest that auditory recovery in MOGAD is often incomplete, even with prompt immunotherapy, unlike that of visual recovery.[6]

This case highlights several important diagnostic challenges. Profound bilateral visual loss without optic disc oedema with concurrent auditory symptoms are atypical for classic MOGAD-ON. The relatively normal fundus appearance and normal acute-phase RNFL thickness broadened the differential diagnoses and necessitated extensive investigations before a definite diagnosis was established. Furthermore, delayed presentation contributed to the late initiation of high dose immunotherapy. Collectively, these atypical clinical features and delayed presentation likely contributed to delayed diagnosis and late initiation of treatment and may explain the limited visual recovery observed in the patient despite aggressive immunotherapy.

CONCLUSION

This case expands the ophthalmic spectrum of MOGAD, demonstrating that it may present as severe bilateral painless optic neuropathy without disc oedema, alongside rare auditory involvement. A high index of clinical suspicion for MOGAD is essential in atypical optic neuropathy presentations, even when fundus and OCT findings are unremarkable. Early neuroimaging and serological testing are crucial for accurate diagnosis and timely treatment, thereby preventing irreversible neurological and visual disability.

REFERENCES

1. Jeyakumar N, Lerch M, Dale RC, Ramanathan S. MOG antibody-associated optic neuritis. Eye 2024; 38: 2289-301.
2. Ong ZM, Arip M, Ching YM, Kumar L, Terumalay S, Sim SH, et al. The prevalence, demographics, clinical features, neuroimaging, and inter-ethnic differences of MOGAD in Malaysia with global perspectives. Mult Scler Relat Disord 2022; 67: 104168.
3. Nowacka B, Lubiński W, Kaźmierczak B. Myelin oligodendrocyte glycoprotein (MOG) antibody-associated optic neuritis: A case report and literature review. Int Med Case Rep J 2024; 17: 391-9.
4. Sechi E, Cacciaguerra L, Chen JJ, Mariotto S, Fadda G, Dinoto A, et al. Myelin oligodendrocyte glycoprotein antibody-associated disease (MOGAD): A review of clinical and MRI features, diagnosis, and management. Front Neurol. 2022; 13: 885218.
5. Chen JJ, Sotirchos ES, Henderson AD, Vasileiou ES, Flanagan EP, Bhatti MT, et al. OCT retinal nerve fiber layer thickness differentiates acute optic neuritis from MOG antibody-associated disease and multiple sclerosis: RNFL thickening in acute optic neuritis from MOGAD vs MS. Mult Scler Relat Disord 2022; 58: 103525.
6. Kwon S, Choi S, Chung YH, Min JH. Sensorineural hearing loss in seropositive neuromyelitis optica spectrum disorder and myelin oligodendrocyte glycoprotein antibody-associated disorder. Acta Neurol Scand 2024; 6724448.
7. Jarius S, Kleiter I, Ruprecht K, Asgari N, Pitarokoili K, Borisow N, et al. MOG-IgG in NMO and related disorders: A multicenter study of 50 patients. Part 3: Brainstem involvement—frequency, presentation and outcome. J Neuroinflammation 2016; 13: 281.
8. Cobo-Calvo A, Ayrignac X, Kerschen P, Horellou P, Cotton F, Labauge P, et al. Cranial nerve involvement in patients with MOG antibody-associated disease. Neurol Neuroimmunol Neuroinflamm 2019; 6(2): e543.
9. Banwell B, Bennett JL, Marignier R, Kim HJ, Brilot F, Flanagan EP, et al. Diagnosis of myelin oligodendrocyte glycoprotein antibody-associated disease: International MOGAD panel proposed criteria. Lancet Neurol 2023; 22: 268-82.
10. Akaishi T, Himori N, Takeshita T, Misu T, Takahashi T, Takai Y, et al. Five-year visual outcomes after optic neuritis in anti-MOG antibody-associated disease. Mult Scler Relat Disord 2021; 56: 103222.

Beyond the tear: Acute pericarditis emerging from esophageal perforation

Yi Han Tan, MB BCh BAO[1], Nurazim Sidi, MBBS[2], Mohammad Shukri Jahit, MMed Surg[2], Ainul Syahrilfazli Jaafar, MBChB[1]

[1]Department of Surgery, National University of Malaysia, Jalan Yaacob Latif, Bandar Tun Razak, Cheras, Wilayah Persekutuan Kuala Lumpur, [2]Department of Surgery, National Cancer Institute, Jalan P7, Presint 7, Putrajaya, Malaysia

SUMMARY

Boerhaave Syndrome is a rare and potentially fatal condition occurring at about 3.1 per million people annually. It typically occurs after a sudden rise in oesophageal pressure due to persistent vomiting and coughing.[1-2] Pericardial syndrome, a rare complication, can further complicate the management of Boerhaave Syndrome. A 36-year-old man, arrived at the Emergency Department following a massive haematemesis episode and two days of epigastric pain. Clinical examination revealed Mackler's Triad —vomiting, chest pain, and subcutaneous emphysema—suggesting Boerhaave syndrome. An oesophagogastroduodenoscopy (OGDS) demonstrated a distal esophageal perforation, and a contrasted CT scan confirmed this defect along with extensive pneumomediastinum and massive subcutaneous emphysema. He underwent emergency left thoracotomy for repair of the oesophageal perforation and thoracic cavity washout. Postoperatively, ECG demonstrated widespread concave ST elevation, and he remained tachycardic with elevated septic markers. Echocardiogram and contrasted CT thorax identified a moderate pericardial effusion, leading to open pericardial drainage, as a pericardial catheter could not be safely placed. After a lengthy recovery, OGDS reassessment at two weeks showed healed mucosa over the repaired perforation. He was discharged after five weeks in hospital. Pericarditis with pericardial effusion is a rare complication of Boerhaave Syndrome, with few cases documented so far. The primary treatment focuses on controlling the source to prevent further contamination, managing sepsis with antibiotics, and draining the effusion to avoid cardiac tamponade. Pericarditis is a rare but life-threatening complication of Boerhaave Syndrome. Hence, prompt diagnosis and timely management are paramount to a good outcome.

INTRODUCTION

Boerhaave syndrome involves spontaneous, vertical tears in the distal oesophagus, often following forceful or repeated vomiting, severe coughing, or blunt injury. These tears lead to a sudden increase in intraluminal pressure against a closed cricopharyngeus muscle. The condition has a reported global incidence of approximately 3.1 cases per million annually.[1] The classic Mackler Triad—vomiting, chest pain, and subcutaneous emphysema—is traditionally associated with Boerhaave syndrome, but it appears in only half of the cases.[2] This variability in presentation can delay diagnosis; treatment delays beyond 48 hours are associated with a mortality rate of 40% to 60%.[3-4] Although rare, pericarditis with effusion is a serious complication that may further complicate management. Most reported cases of oesophageal perforation with pericarditis resulted from foreign body ingestion, and pericarditis following Boerhaave syndrome remains exceptionally uncommon.

CASE PRESENTATION

A 36-year-old male, an active smoker, presented to the emergency department after experiencing a single episode of massive haematemesis and epigastric pain. On assessment, he was tachycardic (heart rate 120 bpm) and tachypnoeic (respiratory rate 24 breaths per minute). Examination revealed epigastric tenderness and subcutaneous emphysema in both sides of the neck. Blood tests indicated elevated inflammatory markers, with a white blood count of 22 x 10^9/l, and signs of acute kidney injury. Chest radiography demonstrated widespread subcutaneous emphysema. Considering Mackler's triad – vomiting, chest pain, and subcutaneous emphysema- Boerhaave syndrome was the primary suspicion.

An urgent oesophagogastroduodenoscopy (OGDS) found a 2 cm longitudinal defect in the distal oesophagus, with slough and clot. Contrast-enhanced CT scans of the thorax, abdomen, and pelvis confirmed a focal tear in the distal oesophagus leading to a left para-oesophageal collection, extensive pneumomediastinum, and subcutaneous emphysema. The scan also revealed bilateral pleural effusions and left lung consolidation. The initial CT imaging and the first OGDS were performed at the referring centre prior to transfer; therefore, the diagnostic sequencing reflected the referring institution's practice.

The patient was treated for Boerhaave syndrome. After resuscitation, he underwent left thoracotomy, distal oesophageal repair, and on-table OGDS. Intraoperatively, on-table OGDS demonstrated a longitudinal 3cm defect in the distal left oesophagus with evidence of gastro-oesophageal reflux. Left thoracotomy was performed, 800 mL of turbid fluid was drained from the left thorax, and the defect site was repaired with a single-layer absorbable barbed suture. The air-leak test was negative on post-repair OGDS.

This article was accepted: 29 April 2026
Corresponding Author: Yi Han Tan
Email: tyhan1028@gmail.com



Fig. 1: CT scan finding of oesophageal perforation with left paraoesophageal collection, pneumomediastinum and bilateral pleural effusion

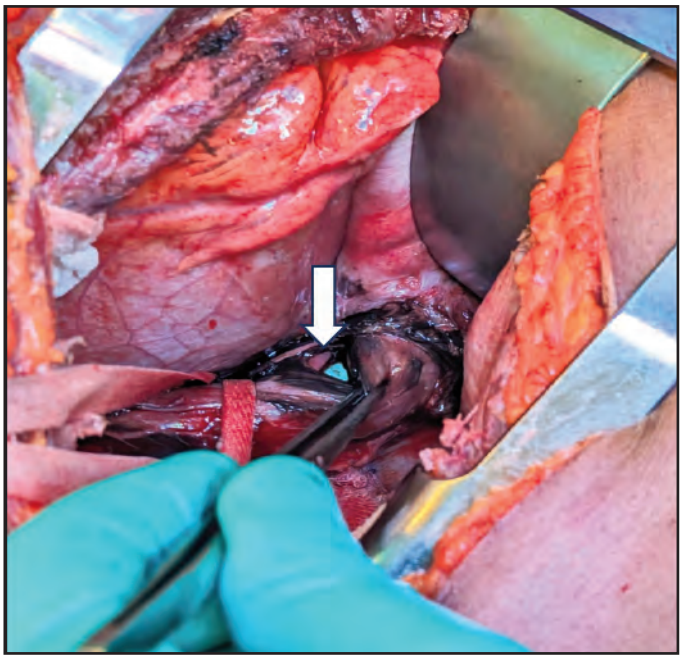

Fig. 2: Intraoperative view- Defect seen at distal oesophagus with bougie seen intraluminally (white arrow)



Fig. 3: Reassessment CT scan showed moderate pericardial effusion with left paraoesophageal collection and bilateral pleural effusion

Postoperatively, the patient was managed in the intensive care unit (ICU).

Postoperatively, the patient was maintained nil by mouth and started on total parenteral nutrition on the second day after surgery. Postoperatively, electrocardiography demonstrated widespread ST-segment elevation and persistent tachycardia with a heart rate of 110 to 130 bpm. The initial echocardiogram on day 2 post-surgery was unremarkable, with no significant findings. A follow-up echocardiogram on day 5 revealed a small pericardial effusion measuring 0.5 cm in diameter.

Despite antibiotic therapy, the patient continued to exhibit persistent fever spikes, tachycardia, elevated septic markers, and increasing inotropic requirements. He was started on antifungal therapy and carbapenem antibiotics. A contrast-enhanced thoracic CT scan revealed no leak at the repaired site but showed moderate pericardial and bilateral pleural effusions. An urgent echocardiogram confirmed a pericardial effusion, predominantly over the anterior pericardial cavity. The case was co-managed with the cardiology team for pericardiocentesis; however, owing to the absence of a safe access route, open pericardial drainage was performed, yielding 350 mL of haemoserous fluid. After the procedure, his condition improved, and septic markers decreased. A follow-up echocardiogram on day 6 demonstrated only a minimal residual pericardial effusion.

The clinical course was further complicated by ventilator-associated pneumonia and prolonged mechanical ventilation. Two weeks following repair, a tracheostomy was performed, and OGDS was reassessed. The repaired site remained intact, with no evidence of dehiscence or leakage. He was gradually weaned from ventilation and began feeding via a nasogastric tube. The patient's condition steadily improved, and he was transferred from the ICU after one month. Prior to discharge, oral diet was well tolerated, and the tracheostomy was decannulated.

DISCUSSION

The pericardium is a double-layered, fibroelastic sac that surrounds the heart, with a cavity usually containing 15 to 20 ml of serous fluid. Pericarditis is an inflammatory condition of this sac that can cause fluid accumulation, leading to pericardial effusion. When sufficiently large, the effusion may compress the cardiac chambers, restrict diastolic filling, and potentially precipitate cardiac tamponade.

Pericarditis is an uncommon yet serious complication of oesophageal perforation. It has been reported in a limited number of cases, predominantly as a consequence of oesophageal perforation caused by foreign body ingestion.[6] Only a limited number of cases of Boerhaave syndrome complicated by pericarditis have been documented.[7] Given the thoracic oesophagus's anatomical position within the mediastinum, located behind the heart, contamination with digestive content and saliva can give rise to inflammation and severe infections within deep anatomical compartments, including the mediastinum, pleural cavity, and pericardial cavity. Such infection can rapidly progress to septic shock, which carries significant morbidity and mortality and presents considerable management challenges. Thus, when performing OGDS in this context, additional precautions are necessary to prevent further contamination, as insufflation may theoretically exacerbate mediastinal soiling. In our case, repeat on-table OGDS was performed in a controlled operating theatre setting by an experienced Upper GI surgeon to define defect size and mucosal viability for operative planning, while minimizing insufflation given the risk of worsening mediastinal contamination.

In the case described above, the initial computed tomography (CT) scan did not reveal any evidence of pericardial effusion, as this was a subsequent sequela that developed following perforation. Given the widespread ST-segment elevation on electrocardiography (ECG) and persistent tachycardia, pericarditis was clinically suspected. The diagnosis was further confirmed by echocardiography performed on the fifth day post-surgery. Furthermore, microbiological cultures were negative (in the context of prior antibiotic use), and the effusion was interpreted as likely reactive or inflammatory rather than confirmed purulent pericarditis. It is recommended that pericarditis be treated with high-dose non-steroidal anti-inflammatory drugs (NSAIDS) and colchicine.[8-9] Furthermore, a gradual tapering of low-to-moderate doses of prednisolone may be prescribed if NSAIDs and colchicine are contraindicated.[10] Pharmacotherapy was not initiated at the outset owing to the presence of severe sepsis, and the clinical condition subsequently progressed to pericardial effusion with impending tamponade.

The severity of pericardial effusion can be assessed by echocardiographic examination of the right ventricle. the right heart operates under lower intracavitary pressure, it is more vulnerable to external compression; accordingly, abnormal right ventricular filling is an early indicator of cardiac tamponade.[5] Pericardiocentesis is generally considered the first-line treatment for cardiac tamponade, as it is a bedside procedure that can be performed expeditiously under ultrasound guidance. Nevertheless, if echocardiographic evaluation reveals no safe access point to the pericardial cavity, open pericardial drainage becomes necessary. In our patient's case, open pericardial drainage was performed because no safe window for pericardiocentesis was identified.

The management strategy in this patient with Boerhaave syndrome and pericarditis centred on source control via oesophageal repair, antibiotics, and drainage, in addition to nutritional support, aggressive rehabilitation, and most critically, multidisciplinary management. In cases of Boerhaave syndrome, prompt diagnosis followed by emergency surgery for source control has been the primary approach to reduce mortality and morbidity. Endoscopic stenting was considered; however, given haemodynamic instability, sepsis, and gross contamination, surgical source control with washout and drainage was deemed the most appropriate approach. The mortality rate decreases to 10–25% when treatment is initiated within 24 hours of presentation.[3-4] Subsequent ventilatory and circulatory

support provided by the anaesthesiology team, along with antimicrobial therapy tailored according to culture sensitivities, have significantly contributed to postoperative recovery. Early initiation of total parenteral nutrition (TPN) was implemented to meet daily energy and protein requirements, thereby mitigating the hypercatabolic effects of severe infection. Aggressive rehabilitation measures, including chest and limb physiotherapy and early ambulation, are essential for facilitating weaning from ventilatory support and enhancing overall functional status.

CONCLUSION

Boerhaave syndrome accounts for 15% of oesophageal perforation cases.[2] Pericarditis following Boerhaave syndrome is a rare complication that is infrequently documented in the literature. Therefore, prompt diagnosis, surgical intervention, and management of the complications are essential to achieving a favourable outcome.

REFERENCES

1. Mangeshkar S, Borkowski P, Shokrekhuda A, Barillas-Lara MI, Menegus MA. Boerhaave syndrome: an unusual myocardial infarction mimic-a case report. Eur Heart J Case Rep 2024 Jul 13; 8(7): 310.
2. Dinic BR, Ilic G, Rajkovic ST, Stoimenov TJ. Boerhaave syndrome - case report. Sao Paulo Med J 2017; 135(1): 71-5.
3. Cuccì M, Caputo F, Fraternali Orcioni G, Roncallo A, Ventura F. Transition of a Mallory-Weiss syndrome to a Boerhaave syndrome confirmed by anamnestic, necroscopic, and autopsy data: A case report. Medicine (Baltimore) 2018; 97(49).
4. Gupta NM, Kaman L. Personal management of 57 consecutive patients with oesophageal perforation. Am J Surg 2004; 187: 58-63.
5. Little WC, Freeman GL. Pericardial disease. Circulation. 2006; 113(12): 1622-32.
6. Fashandi AZ, Boys JA, Yount KW, Buerlein RC, Shami VM, Ailawadi G, et al. Isolated hemorrhagic pericardial effusion after foreign body ingestion. Ann Thorac Surg 2018; 106(3): 141-3.
7. Eltayeb M, Byrne L, Fitzgerald G, Vaughan C. Recurrent pericardial syndromes following Boerhaave's syndrome: a complex clinical presentation and case report. Eur Heart J Case Rep 2025; 9(7).
8. Imazio M, Brucato A, Trinchero R, Spodick D, Adler Y. Individualized therapy for pericarditis. Expert Rev Cardiovasc Ther 2009; 7(8): 965-75.
9. Imazio M, Bobbio M, Cecchi E, Demarie D, Demichelis B, Pomari F, et al. Colchicine in addition to conventional therapy for acute pericarditis: results of the COlchicine for acute PEricarditis (COPE) trial. Circulation 2005; 112(13): 2012-6.
10. Lotrionte M, Biondi-Zoccai G, Imazio M, Castagno D, Moretti C, Abbate A, et al. International collaborative systematic review of controlled clinical trials on pharmacologic treatments for acute pericarditis and its recurrences. Am Heart J 2010; 160(4): 662-70.

A large primary dermatofibrosarcoma protuberans of the right upper eyelid: A case report and literature review

Zulkifli Abdul-Azim, MBBCh[1,2], A-Rahim Haslinda, MMed (Ophthalmology)[2], Husain Norhalwani, MS (Ophthalmology)[2], Abdul-Rahim Norhafizah, MPath (Anatomic Pathology)[3], Ismail Shatriah, MMed (Ophthalmology)[1]

[1]Department of Ophthalmology and Visual Science, School of Medical Sciences, Universiti Sains Malaysia, Kubang Kerian, Kelantan, Malaysia, [2]Department of Ophthalmology, Hospital Raja Perempuan Zainab II, Kota Bharu, Kelantan, Malaysia, [3]Department of Pathology, Hospital Raja Perempuan Zainab II, Kota Bharu, Kelantan, Malaysia

SUMMARY

Dermatofibrosarcoma protuberans (DFSP) is a rare, slow-growing but locally aggressive dermal sarcoma. A 50-year-old woman is reported with a seven-year history of progressive right upper eyelid swelling, who had a prior benign mass removed from the same site. Imaging showed a lobulated right periorbital mass, and surgical excision identified a 4.4 × 4.2 × 3.1 cm tumour confirmed as DFSP with positive margins. Although she declined radiotherapy, there was no recurrence at 12 months. DFSP should be considered in the differential diagnosis of periorbital masses, as it can mimic benign lesions. Given its high risk of recurrence and aggressive local invasion, achieving complete surgical excision remains a challenge.

INTRODUCTION

Dermatofibrosarcoma protuberans (DFSP) is an uncommon dermal neoplasm with gradual enlargement, local aggressiveness, and frequent relapse after treatment.[1-2] DFSP typically appears as a purple or pink plaque that most commonly arises on the trunk in 50-60% of cases, on the extremities in 20-30% of cases, and with the head and neck region involved in approximately 10-15% of cases.[2-4] Among head and neck cases, periocular or ocular involvement is very rare and occurs in approximately 3.5% of cases.[2-3] The medial canthus is the most frequent site for reported periorbital DFSP cases.[3] Orbital involvement typically occurs due to local invasion from adnexal lesions or, very rarely, from distant metastases.[3]

Based on PubMed search of DFSP cases affecting the eyelid region, only three instances of DFSP originating from a previous surgical scar were identified, including the present case.[5] This case of primary DFSP originating in the right upper eyelid is presented to emphasise the need for a high index of suspicion, as DFSP can be diagnostically challenging due to its resemblance to benign lesions and its occurrence at uncommon sites.

CASE PRESENTATION

A 50-year-old woman with a background of uterine fibroids presented initially with a five-year history of progressive, painless swelling and drooping of the right upper eyelid. The lesion initially appeared as a small papule at the medial aspect of the right upper eyelid and gradually increased in size. Magnetic resonance imaging (MRI) of the orbit demonstrated a superomedial eyelid mass measuring approximately 1.7 × 2.2 × 2.2 cm. She had undergone excision of a right upper eyelid mass, and the histopathological examination was reported as a benign fibrohistiocytic lesion. She remained well postoperatively for one year, but then she subsequently defaulted on follow-up.

She now presented with a gradually enlarged eyelid mass with an estimated duration of seven years at the past surgical site. On presentation, her best-corrected vision (BCVA) was 6/9 (20/30) in the right eye and 6/6 (20/20) in the left eye, with no relative afferent pupillary defect in either eye. A firm, non-tender, immobile mass was palpated over her right upper eyelid region, which caused complete mechanical ptosis (Figure 1A). The extraocular movement was normal except for elevation in the right eye. Ocular examination was normal in both eyes.

MRI of the orbit revealed a well-defined, lobulated, enhancing soft tissue mass located anteromedially in the right periorbital region. The mass had an iso-intense signal to grey matter on T1-weighted images and a heterogeneous intermediate signal on T2-weighted images (Figs. 2A and 2B). It was located near the right eye globe, resulting in a slight inferior and posterolateral displacement (Figs. 2C and 2D). Additionally, the mass was in proximity to the frontal sinus at the front.

The patient underwent an excisional biopsy through a transcutaneous anterior orbitotomy and upper eyelid reconstruction surgery, which included wedge resection, levator advancement, and upper blepharoplasty under general anaesthesia. A large multilobulated encapsulated mass with overlying dilated vessels was carefully removed intraoperatively. The mass, measuring 4.4 x 4.2 x 3.1 cm, was rounded with a smooth outer surface and an area of irregular, papillary-like tan-whitish tissue measuring 4.0 x 2.3 cm (Figs. 3A and 3B). The cut section showed a soft tan-pink mass with an irregular border.

Microscopic examination of the specimen revealed a partially circumscribed tumour composed of spindle cells

This article was accepted: 15 May 2026
Corresponding Author: Shatriah Ismail
Email: shatriah@usm.my

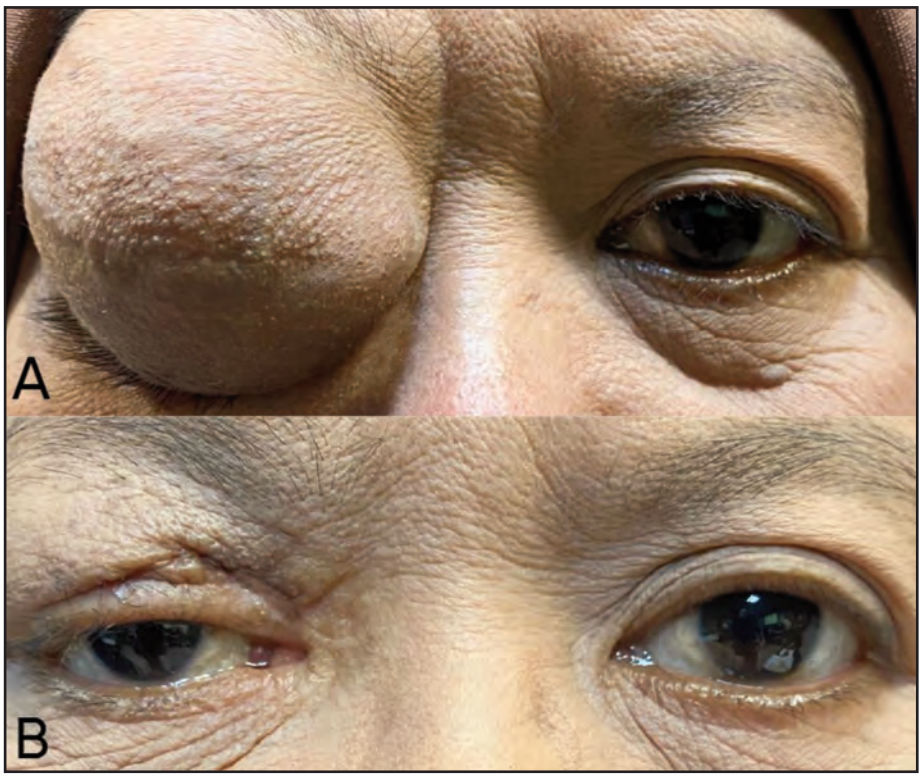

Fig. 1: A) Preoperatively, swelling due to a mass completely under the skin at the right upper eyelid, causing complete mechanical ptosis. B) Photo at 12 months post-operation showing right residual ptosis with minimal keloid formation at the previous surgical wound site.

arranged in various patterns, including diffuse sheets, cartwheels, storiform, and fascicles, with occasional mitotic figures (Figure 3C). The tumour was infiltrative and present at the irregular resected margins. Immunohistochemistry showed strong and diffuse positivity for CD34 (Figure 3D), but negativity for S100, desmin, and cytokeratin (CK AE1/AE3). Smooth muscle actin (SMA) highlighted scattered small vessels within the tumour, and the Ki-67 stain indicated a proliferative index of approximately 15%. These findings were consistent with a diagnosis of DFSP.

The patient was advised to undergo radiotherapy because of the positive surgical margins. However, she declined the recommended treatment. The ocular examination revealed residual ptosis of the right upper eyelid three months post-surgery. Hence, right upper blepharoplasty and frontalis flap were performed three months later. Currently, 12 months post-tumour excision, she exhibits mild ptosis of the right upper eyelid but, fortunately, shows no clinical signs of tumour recurrence (Fig. 1B).

Her BCVA was 6/9 (20/30) in the right eye and 6/6 (20/20) in the left. Refraction revealed marked corneal astigmatism of –3.75 dioptre in the right eye, likely secondary to chronic pressure exerted by the mass, in contrast to mild astigmatism of –0.75 dioptre in the left eye. She was counselled regarding another lid reconstruction surgery but expressed a lack of interest at this time, as she is content with her current ocular condition.

DISCUSSION

DFSP is a rare cutaneous malignant neoplasm, occurring at a rate of 0.8 to five cases per one million people annually.[1,4] It represents less than 0.1% of all malignancies and 1-6% of all soft tissue sarcomas.[1] DFSP grows slowly but is locally aggressive, as it can infiltrate subcutaneous tissues, including muscles and bones. It has a high recurrence rate with a low risk of distant metastasis in 1-4%.[2-4] Although DFSP is commonly diagnosed between the ages of 20 and 50, it can be manifested across all age groups, affecting both sexes equally.[1-2] Table I summarises the published reports of cases with DFSP of the eyelid in relation to a previous history of trauma or multiple surgical procedures, including the patient.[4,6-8] The age at presentation is reported to be in the range of 35 to 62 years of age, with both sexes equally affected.

DFSP may develop within scars from prior trauma, surgery, or vaccination, in areas exposed to ionising radiation, or may arise spontaneously.[3-4] Patel et al. published a retrospective study of 364 DFSP patients and identified that 31 patients (8.5%) acquired DFSP at the location of a prior skin biopsy or small excision, whereas six patients (1.7%) developed DFSP at the site of a previous major surgical scar.[9] Persistent inflammation was postulated to play a role in DFSP development by driving the malignant transformation of scars.[9] The present case involved primary DFSP of the right upper eyelid, which arose from a scar at the site of a previous mass excision.

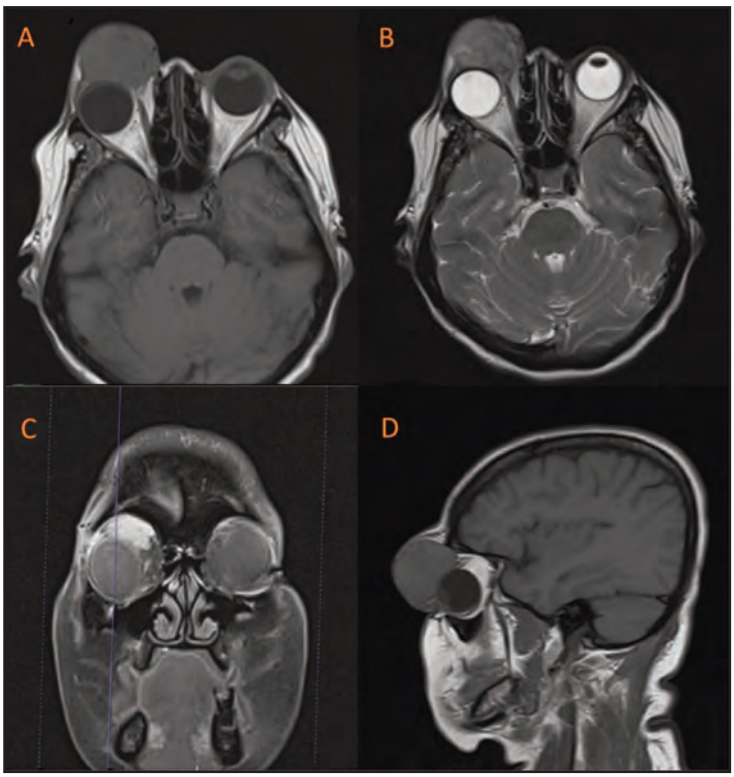

Fig. 2: The axial section of the orbital MRI scan shows a focal, well-defined soft tissue mass at the anteromedial aspect of the right periorbital region, demonstrating isointense signal on T1-weighted imaging (A) and heterogeneous intermediate signal intensity relative to grey matter on T2-weighted imaging (B). The coronal section of the MRI shows part of the mass causing displacement of the right eye globe inferolaterally (C). The sagittal section of the MRI shows the mass causing displacement of the right eye globe posteriorly (D)

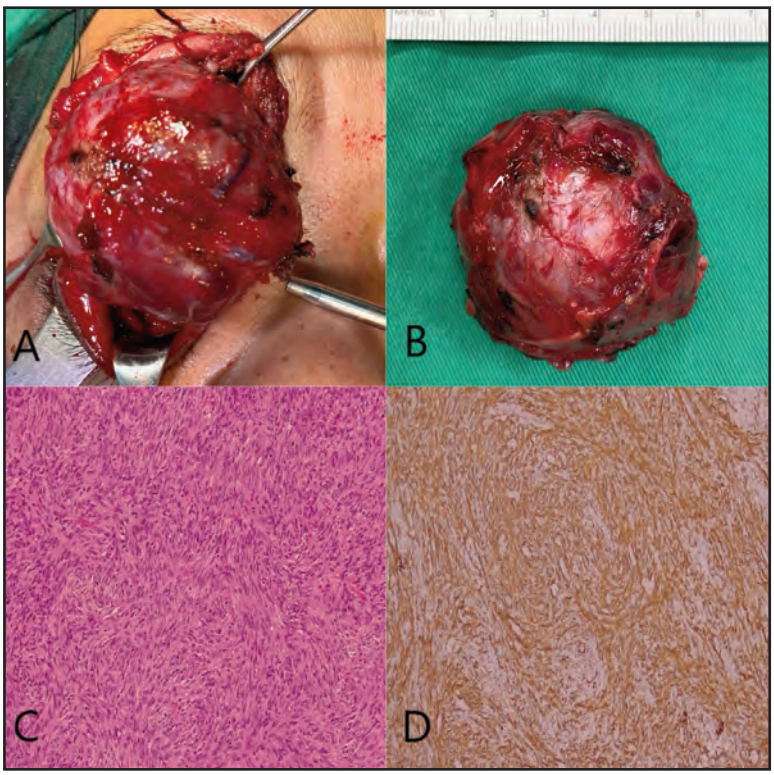

Fig. 3: Intraoperative image showing the location of the mass (A) and a round encapsulated mass with smooth outer surface post-surgical excision (B). Photomicrograph showing spindle cells arranged predominantly in storiform pattern (hematoxylin and eosin stain, magnification ×100) (C). Immunohistochemistry demonstrating diffuse CD34 positivity (magnification x100) (D)

Table I: Summary of published case reports of patients with DFSP of the eyelid in relation to trauma/scar.

Age/Gender/ Country	Initial tumor location	Site of extension	Risk Factor	Histopathology	Duration of illness	Treatment	Outcome/ Disease duration (month)	Author/ Year
62/M/China	Right lower eyelid	None	Local trauma (cat scratch)	Lace-like pattern. Atrophic variant	6 months	Resection of mass with wide margins and reshaped the lower eyelid	6 months	Li et al. 2011.[7]
38/M/USA	Left eyebrow	Left medial canthal, glabella and nasal	Struck by a wooden board	Spindle cell in storiform pattern	6 months	1) Mohs micrographic surgery 2) Exenteration and dacryocystectomy	6 months	Goshe et al. 2012.[6]
44/F/Turkey	Right medial canthus	None	Post mass excision	N/A	15 years	1) En-bloc resection 2) Intensity-modulated radiation therapy with 5400 Gray (180 Gray/fraction/day)	15 years	Kaya et al. 2022.[4]
35/F/Nigeria	Right side of the head	Right Upper eyelid	Post mass excision twice	Storiform pattern	18 years	1) Local resection of the tumor involving 3 cm of normal margin and split thickness skin grafting from the right thigh 2) Right cutler beard procedure and excisional biopsy with primary wound closure and graft of the scalp wound	18 years	Monsudi et al. 2023.[8]
50/F/ Malaysia	Right upper eyelid	None	Post mass excision	Diffuse sheets, cartwheel, storiform, and fascicles patterns	7 years	1) Excisional biopsy via transcutaneous anterior orbitotomy and upper eyelid reconstruction surgery 2) Right upper blepharoplasty and frontalis flap	7 years	Our case

F: female; M: male; N/A: not available

Goshe et al. reported a case of DFSP in a 38-year-old man who developed a tumour in a scar on his left eyebrow, two years after being hit by a wooden board.[6] Li et al. reported a case of primary DFSP of the right lower eyelid region with a history of trauma by a cat scratch at the tumour lesion, which may speed up its progression.[7] Kaya et al. reported a case of a 44-year-old woman who presented with primary DFSP in the right medial canthus.[4] She had a history of a previously excised mass at the same location 20 years earlier, though no pathology report was available.[4] Similarly, Monsudi et al. reported a recurrent case of DFSP on the right side of the head that extended to the right upper eyelid region with a previous history of excisional surgeries twice, but no histopathological examination of the sample was performed.[8]

The histopathological appearance of DFSP is characterised by uniform spindle neoplastic cells arranged predominantly in a storiform pattern parallel to the epidermal surface with minimal pleomorphism and scant cytoplasm.[1] It is surrounded by collagenous stroma and often displays a characteristic honeycomb appearance due to irregular projections infiltrating the subcutaneous tissue and fat.[2,4] In cases of periocular and ocular adnexa involvement, the histopathology of DFSP has been classified into storiform, atrophic, pigmented, diffuse sheets, and cartwheel patterns.[3,10] Immunohistochemistry typically demonstrates strong positivity for CD34 and vimentin,[1,3] with some tumours occasionally demonstrating focal positivity for SMA but not S100.[4] Satellite appearance around the lesion can occur due to intradermal infiltration of malignant cells, potentially extending to muscle and bone.[3] In the present case, the tumour was positive for CD34 and SMA but negative for S100, desmin, and CK AE1/AE3.

The presence of spindle cells arranged in a storiform pattern, combined with histopathological features consistent with DFSP and positive immunohistochemical staining for CD34 and vimentin, constitutes the key diagnostic criteria for DFSP. However, it is important to note that CD34 positivity can also be observed in other spindle cell tumours, such as solitary fibrous tumour, sclerotic fibroma, cellular digital fibroma, cutaneous neurofibroma, dermatofibroma, intradermal spindle cell lipoma, desmoplastic melanoma, and nuchal-type fibroma.[1] Sharudin et al. presented a case of recurrent painless swelling over the left medial canthus region that was previously reported as nodular fasciitis before developing DFSP.[10] Another published report also described DFSP developing after recurrent leiomyomas.[3] The preliminary histopathological interpretation in the present case resembled a benign fibrohistiocytic lesion, illustrating how DFSP may closely mimic benign entities. This highlights the diagnostic challenge and the importance of considering DFSP in recurrent or atypical eyelid lesions. False-negative pathological diagnoses delay treatment, allowing the tumour to extend, recur, and cause significant local damage. Accurate pathological diagnosis is therefore crucial for successful DFSP management.[1]

The principal treatment for DFSP is surgical excision, employing two primary techniques: wide local excision (WLE) and Mohs micrographic surgery (MMS). WLE involves resection of the tumour with a margin of adjacent healthy tissue of 3 to 5 cm, which is important for reducing recurrence rates.[4] The dermal defect resulting from WLE should be reconstructed using flaps or grafts.[3] However, WLE may not be feasible for head and neck tumours. MMS allows for immediate evaluation of margins, making it advantageous in cosmetically sensitive areas. It is associated with lower recurrence rates compared with WLE.[5] In cases where complete excision is not feasible or recurrence or metastasis is present, radiotherapy and chemotherapy are considered alternative treatments.[3] Adjuvant radiotherapy, such as brachytherapy or external beam radiotherapy, can enhance local control and reduce recurrence.[5] Jamor et al. reported a case of DFSP in the right upper eyelid, treating it with tumour excision and surface mould high-dose-rate brachytherapy.[5] They suggested this is a viable option when radical surgery is not possible and cost-effective in low-resource environments.[5]

The National Comprehensive Cancer Network Guidelines for soft tissue sarcoma recommend adjuvant radiotherapy in the setting of positive surgical margins.[2] In the patient, the combination of positive margins and refusal of radiotherapy increases the risk of local recurrence, emphasising the need for close and long-term follow-up. Molecularly targeted therapy, such as Imatinib, inhibits the platelet-derived growth factor receptor and other tyrosine kinase receptors. It effectively treats locally inoperable and metastatic DFSP by inhibiting tumour growth and promoting cell death.[2-3]

The prognosis for DFSP is favourable, with a ten year survival rate of 99.1%. However, patients with metastatic disease usually have a survival period of about two years after diagnosis.[2] Recurrence is determined by the tumour's location, adequacy of surgical margins, and accuracy of the initial pathological diagnosis.[1,4] Local recurrence rates vary between 20-50%, particularly with positive margins.[1-2] Monsudi et al. reported recurrence at 14 months post-operatively.[8] The head and neck region is the most common site for DFSP recurrence, likely due to the difficulty of achieving free surgical margins.[1,4] Life-long surveillance is recommended, as local recurrence may arise many years after initial treatment.[3]

DFSP arising from a previous surgical scar is uncommon and may mimic benign tumours, leading to diagnostic and management delays. Therefore, early recognition of any mass developing at a prior surgical site, thorough patient counselling, and close long-term follow-up are essential to ensure timely treatment of this locally aggressive tumour and to prevent recurrence.

REFERENCES

1. Larbcharoensub N, Kayankarnnavee J, Sanpaphant S, Kiranantawat K, Wirojtananugoon C, Sirikulchayanonta V. Clinicopathological features of dermatofibrosarcoma protuberans. Oncol Lett 2016; 11(1): 661-7.
2. Menon G, Brooks J, Ramsey ML. Dermatofibrosarcoma protuberans [Internet]. StatPearls - NCBI Bookshelf. 2024. Available from: https://www.ncbi.nlm.nih.gov/books/NBK513305/Accessed January 17, 2025.

3. Eshraghi B, Jahanbani-Ardakani HR, Abtahi SM, Abtahi SH. Ophthalmologic aspects of dermatofibrosarcoma protuberans: a systematic review in the context of a rare case of primary orbital involvement. J Fr Ophtalmol 2019; 42(8): 913-24.
4. Kaya AA, Özkurt ZG, Gül A, Nacir M. A rare orbital pathology: a large orbital dermatofibrosarcoma protuberans. Turk J Ophthalmol 2022; 52(6): 436-9.
5. Jamora KE, Cereno REP, Inocencio ET, Hizon VFR. Dermatofibrosarcoma protuberans of the upper eyelid treated with surface mould high-dose-rate brachytherapy. Rep Pract Oncol Radiother 2022; 27(1): 182-7.
6. Goshe JM, Lewis CD, Meine JG, Schoenfield L, Perry JD. Primary dermatofibrosarcoma protuberans invading the orbit. Ophthalmic Plast Reconstr Surg 2012; 28(3): e65-7.
7. Li J, Ge X, Ma JM, Li M. Dermatofibrosarcoma protuberans. Ophthalmology 2012; 119(1): 197-197.e3.
8. Monsudi KF, Ibrahim MH, Ayodapo AO, Owoeye JF, Na'allah GR. Dermatofibrosarcoma protuberans of the scalp and lid-a huge challenge: case report. W J Biomed Res 2023; 10(2): 66-70.
9. Patel RC, Downing C, Robinson C, Bassett R, Roland CL, Garg N, et al. Dermatofibrosarcoma protuberans found within procedural scars: a retrospective review at a tertiary referral cancer centre. Cureus 2020; 12(9): e10286.
10. Sharudin SN, Tan SW, Mohamad NF, Vasudevan SK, Khairan H, Mun YC, et al. Orbitofacial dermatofibrosarcoma protuberans with intranasal extension. Orbit 2018; 37(3): 196-200.

Scurvy-induced severe pulmonary hypertension in a child with autism spectrum disorder: A rare and reversible cause

Nur Zulaika Madon[1], Putri Yubbu[1,2], Mohd Amin Itam[2]

[1]Department of Paediatrics, Faculty of Medicine and Health Sciences, Universiti Putra Malaysia, Selangor, Malaysia, [2]Paediatric Cardiology Unit, Hospital Sultan Idris Shah, Serdang, Malaysia

SUMMARY

Severe pulmonary hypertension (PHT) in children is rare but potentially life-threatening, with diverse aetiologies. Clinical presentation is often non-specific and may be overlooked, particularly in children with neurodevelopmental disorders. A case is reported of an autistic boy with avoidant restrictive food intake disorder (ARFID) who presented with severe PHT secondary to scurvy which showed complete reversibility following vitamin C replacement.

INTRODUCTION

Paediatric PHT caused by Vitamin C deficiency (scurvy) is rare but may occur in children with highly restrictive dietary patterns.[1,2] Scurvy impairs endothelial function and promotes pulmonary vascular remodelling, which may culminate in severe PHT.[3] Although uncommon, micronutrient deficiencies should be considered early in the diagnostic work-up, particularly in patients with neurodevelopmental disorders and restrictive dietary patterns as described in the patient with autism spectrum disorder (ASD).[4]

CASE PRESENTATION

A 7-year-old boy with autism spectrum disorder presented with symptoms of gastroenteritis and features of right-sided heart failure. He adhered to a highly selective diet devoid of fruits and vegetables, and demonstrated failure to thrive (weight 18 kg, <3rd percentile; height 126 cm, 25th–50th percentile). Initially, he required multiple fluid boluses, inotropic support for hypotensive episodes, and non-invasive respiratory support for respiratory distress.

On examination, he was receiving continuous positive airway pressure with a positive end-expiratory pressure of 5 cmH_2O and a fraction of inspired oxygen of 60%, blood pressure of 100/60 mmHg and pulse rate of 120 bpm. He had bilateral pedal oedema, raised jugular venous pressure, and hepatomegaly extending 4 cm below the right costal margin. A left parasternal heave and a loud P2 were present, with bilateral lung crepitations on auscultation.

Transthoracic echocardiography demonstrated dilated right-sided chambers with evidence of severe PHT, severe tricuspid regurgitation (estimated right ventricular systolic pressure 62 mmHg), impaired right ventricular systolic function (TAPSE 13 mm), and preserved left ventricular ejection fraction (79%). With a history of improper dietary intake and clinical suspicion of scurvy, vitamin C was tested and reported a markedly reduced serum ascorbic acid level (<0.1 mg/dL; Ref: 0.4–2.0 mg/dL). Notably, the patient lacked the classic dermatological or musculoskeletal hallmarks of scurvy. Other medical conditions causing PH were excluded. He was commenced on oral sildenafil and therapeutic-dose vitamin C.

At the six-week follow-up, the patient was clinically well, with significant improvement in PHT and normalisation of right ventricular geometry and systolic function. Sildenafil was discontinued, while vitamin C supplementation was continued.

DISCUSSION

This case highlights a rare but important example of reversible severe PHT secondary to nutritional deficiency. Although uncommon and frequently overlooked, scurvy represents a clinically significant cause of PHT and may be fatal if unrecognised and untreated.[1-2] While often dismissed as a historical relic, scurvy remains a clinically relevant entity in the modern era. In regions where food fortification and nutritional supplementation are widespread, the diagnosis is frequently unanticipated, leading to significant under-detection and diagnostic delays.[5]

Scurvy has been described as 'the great mimicker' as its clinical manifestations are highly variable. Presentations may be as non-specific as constitutional symptoms such as fatigue and loss of appetite. Some patients exhibit cutaneous or haematological manifestations, whilst the vast majority present with musculoskeletal symptoms, reported in 92% of patients.[6] Scurvy may contribute to the development of PHT through several mechanisms, most notably impaired endogenous endothelial nitric oxide production, coupled with dysregulated pulmonary vascular remodelling — including hypoxia-inducible factor-mediated pathways — resulting in diminished opposition to pulmonary vasoconstriction.[3] Cardiopulmonary manifestations have been reported to range from exertional fatigue to cardiopulmonary collapse secondary to right-sided heart failure in the context of pulmonary hypertension.[2,6]

This article was accepted: 25 May 2026
Corresponding Author: Putri Yubbu
Email: drputri@upm.edu.my

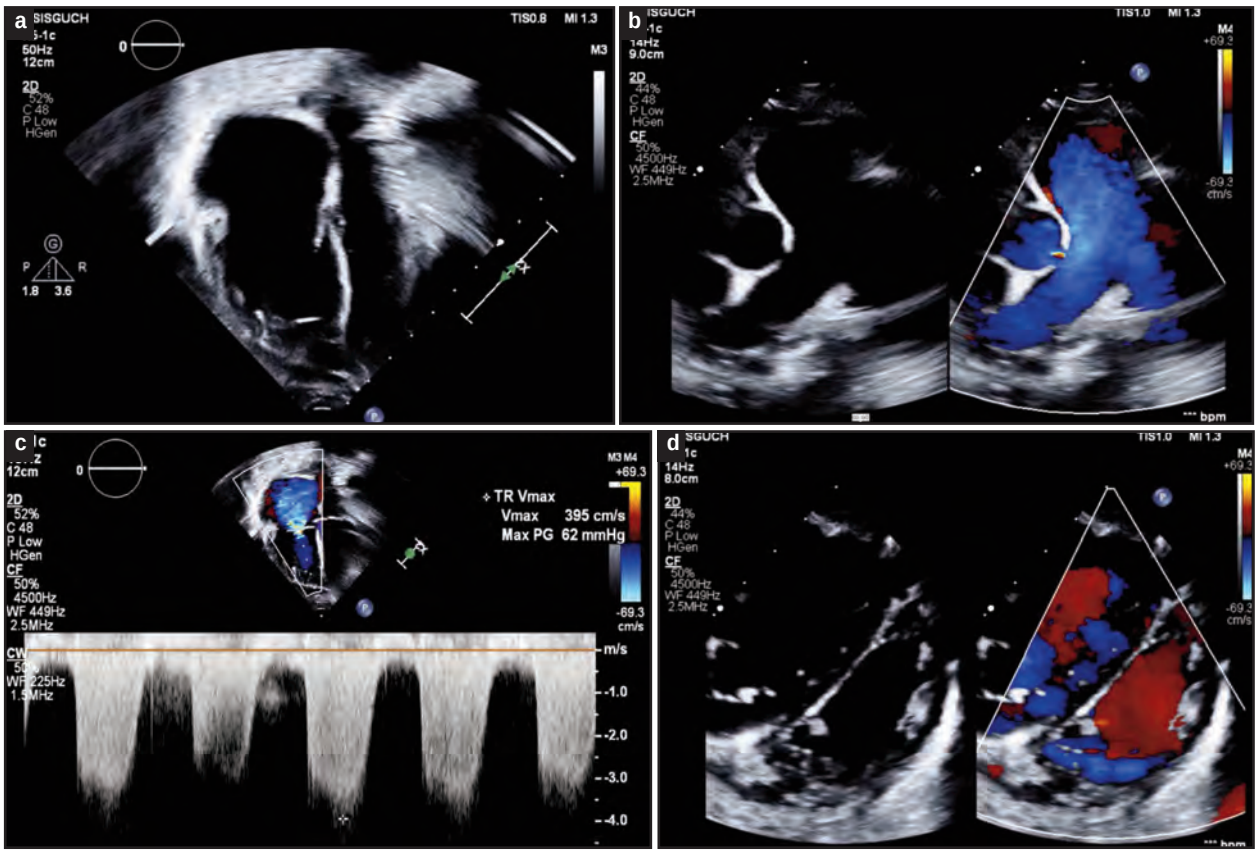

Fig. 1: Pre-treatment Echocardiogram; (a) Dilated right-sided chambers (b) Dilated pulmonary arteries (c) Severe tricuspid regurgitation with TR of 62mmHg (d) Interventricular septal flattening

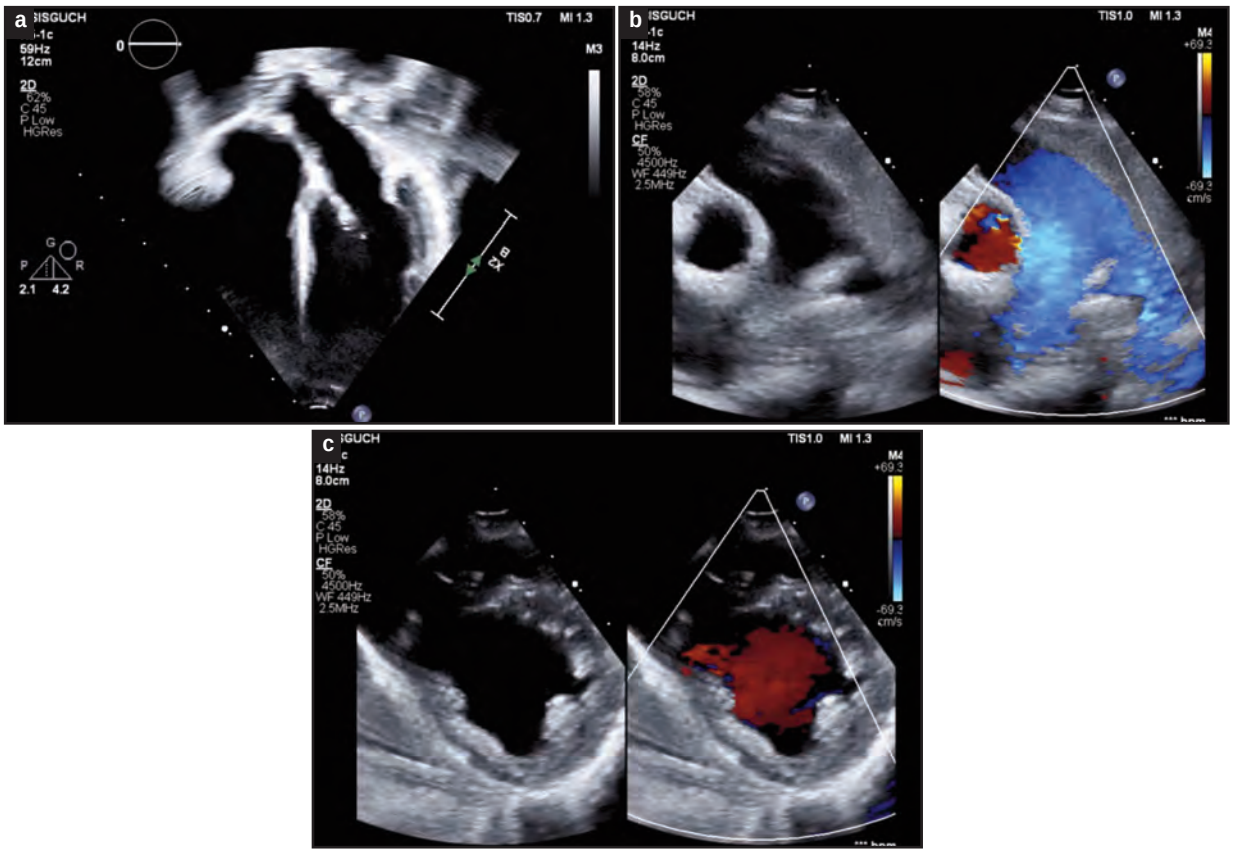

Fig. 2: Post-treatment Echocardiogram; (a,b) Right ventricle and pulmonary artery were much less dilated (c) Restored circular left ventricle

The clinical presentation in our case mirrors the findings reported by Satawiriya et al., characterised by decompensated heart failure and episodes of hypotension secondary to severe PHT.[2] Notably, the present patient lacked the hallmark mucocutaneous and musculoskeletal manifestations of scurvy, such as arthralgia, spontaneous haemorrhage, or anaemia which were present in previously documented cohorts.[1-2,6] This underscores that pulmonary vascular dysfunction can emerge as a sentinel or even isolated manifestation of ascorbic acid deficiency, preceding the more widely recognised classic signs of scurvy.

Comprehensive reviews indicate that the narrow dietary variety common in children with ASD significantly elevates the risk of micronutrient deficiencies; notably, scurvy is a recognised sequela of avoidant restrictive food intake disorder (ARFID) in this high-risk group.[7] ARFID, recently introduced in the Diagnostic and Statistical Manual of Mental Disorders, 5th Edition (DSM-5). It is characterised by persistently insufficient nutritional and/or energy intake and frequently co-exists with ASD, with reported prevalence ranging from 12.5% to 33%.[8] Children with ASD and co-occurring ARFID often exhibit more severe restrictive eating behaviours attributable to sensory sensitivities; such behaviours have been reported at up to 15-fold greater frequency than in typically developing children,[8] thereby heightening the risk of micronutrient deficiencies, growth faltering, and impairments in psychosocial functioning, despite adequate caloric intake.[9]

This case underscores the critical need for a systematic evaluation of secondary causes of PHT, including nutritional deficiencies, particularly in children with neurodevelopmental disorder.[10] Routine screening is strongly recommended of serum ascorbic acid, alongside other key micronutrients such as vitamin D and iron, in children presenting with PHT who exhibit selective eating patterns or are at high risk for malnutrition. Notably, scurvy-induced PHT in the paediatric population is typically transient; high-dose vitamin C supplementation achieves rapid clinical and haemodynamic resolution, thereby preventing long-term cardiopulmonary sequelae.[1-2]

Integration of comprehensive dietary and micronutrient assessments into the diagnostic algorithm for paediatric PHT is essential, particularly in children with autism and ARFID. Scurvy-induced PHT is a life-threatening yet fully reversible condition; early recognition and prompt treatment with ascorbic acid ensure complete haemodynamic resolution and prevents irreversible cardiopulmonary sequelae.

REFERENCES

1. Azar J, Ayyad M, Jaber Y, Ayasa LA. Scurvy-induced pulmonary arterial hypertension. BMJ Case Reports CP 2023; 16(4): e254730.
2. Satawiriya M, Khongphatthanayothin A, Limsuwan A. Reversible severe pulmonary hypertension related to scurvy in children. BMC Cardiovascular Disorders 2024; 24: 24.
3. Humbert M, Morrell NW, Archer SL, Stenmark KR, MacLean MR, Lang IM, et al. Cellular and molecular pathobiology of pulmonary arterial hypertension. J Am Coll Cardiol 2004; 43(12, Suppl S): S13–S24.
4. Sharp WG, Berry RC, Burrell L, Scahill L, McElhanon BO. Scurvy as a Sequela of Avoidant-Restrictive Food Intake Disorder in Autism: A Systematic Review. J Dev Behav Pediatr 2020; 41(5): 397-405.
5. Velandia B, Centor RM, McConnell V, et al. Scurvy is still present in developed countries. J Gen Intern Med 2008; 23: 1281-4.
6. Trapani S, Rubino C, Indolfi G, Lionetti P. A narrative review on pediatric scurvy: the last twenty years. Nutrients 2022; 14(3).
7. Inoue, T., Otani, R., Iguchi, T., et al. (2021). Prevalence of autism spectrum disorder and autistic traits in children with anorexia nervosa and avoidant/restrictive food intake disorder. BioPsychoSocial Medicine 15: 9.
8. Mayes SD, ZickgrafH. Atypical eating behaviors in children and adolescents with autism, ADHD, other disorders, and typical development. Research in Autism Spectrum Disorders 2019; 64: 76-83.
9. Bandini LG, Anderson SE, Curtin C, Cermak S, Evans EW, Scampini R, et al. Food selectivity in children with autism spectrum disorders and typically developing children. J Pediatr. 2010; 157(2): 259-64.
10. Humbert M, Kovacs G, Hoeper MM, Badagliacca R, Berger RMF, Brida M, et al. 2022 ESC/ERS Guidelines for the diagnosis and treatment of pulmonary hypertension. Eur Heart J 2022; 43(38): 3618-731.

CASE REPORT

How immunity shapes mpox severity: Insights from Sarawak Malaysia

Wei Shan Tan, MBBS[1], Siti Ayesha Siddiqa Saifuddin, MRCPI[1], Ingrid Pao Lin Ting, AdvMDerm[1], Hock Hin Chua, MRCP[2], Min Moon Tang, AdvMDerm[1]

[1]Department of Dermatology, Sarawak General Hospital, Kuching, Sarawak, Malaysia, [2]Infectious Diseases Unit, Sarawak General Hospital, Kuching, Sarawak, Malaysia

SUMMARY

Although uncommon in Malaysia, Mpox has emerged locally. Three cases of Mpox in Sarawak are presented, with the aim to describe clinical manifestations based on patients' immunity. All were MSM aged between 28 and 40 years of age. The first patient was HIV negative. He had 20 papules with central crusts on the penis and trunk. The disease duration in the first patient lasted approximately one month. The second patient was HIV-infected, and on HAART since 2022 with a CD4 of 208/μL. He had about 13 lesions over the hands, fingers, trunk, and perianal region. Recovery was achieved within two weeks, after which the patient was lost to follow-up. The third patient presented with a rapidly progressive eruption of multiple pustules over the genital area, face, scalp, trunk, and limbs two weeks before hospitalization. The lesions were most severe at the scrotum and perianal region with vesicles coalescing, resulting in necrosis with deep induration, and subsequent ulceration. His total lesion count was nearly 50. He tested positive for HIV, Hepatitis B, and RPR, with a CD4 of 15/μL. The ulcers were secondarily infected with *Acinetobacter baumannii*. He was hospitalised and isolated for a total of 75 days, receiving IV augmentin, tazocin, tecovirimat, IM benzathine penicillin, in addition to HAART consisting of dolutegravir, tenofovir, and emtricitabine. He improved very slowly. The clinical patterns of Mpox infection described in Sarawak reflect the typical presentation of Clade IIb MPXV. The disease was more severe and of longer duration in HIV-infected individuals with very low CD4 counts.

INTRODUCTION

Mpox (previously known as monkeypox) is caused by the Mpox virus (MPXV), a zoonotic orthopoxvirus that was first discovered in a colony of monkeys with pox infections in 1958.[1] There are two distinct clades of Mpox: Clade I (subclades Ia and Ib), which is associated with a threefold higher fatality rate than Clade II.[2] Clade II Mpox (subclades IIa and IIb), is associated with a self-limiting disease with a lower mortality rate.[2] Both clades, however, are disseminated in the same way. For decades, Mpox was endemic to West and Central African countries.[3] However, a major outbreak of Mpox clade IIb occurred in May 2022, leading to the declaration of Mpox as a Public Health Emergency of International Concern.[4] Since January 2024, more than 55,000 cases of clade I Mpox were reported globally. Since July 2023, Malaysia has reported a total 28 confirmed Mpox.[5]

Mpox typically presents with a febrile prodrome accompanied by generalised headache and fatigue.[6] Skin lesions initially appear as macules, progressing to papules, vesicles, and then umbilicated pustules with a prominent rim of erythema.[6] Ulcers will form subsequently with central scabs. Each morphology of the lesions appears at a single stage of development at a time; each lasts for one to two days. The number of lesions varied from a few to thousands.[7] Secondary bacterial infections may complicate the disease, resulting in abscess formation. In addition, lesions may coalesce to form large plaques and ulcers.[7-8]

Mpox in Malaysia reveals how heavily patient immunity shapes clinical presentations. Failure to recognise Mpox represents the greatest challenge in its management at the primary care level, leading to misdiagnosis and delays in contact tracing. Therefore, this case series aims to describe the clinical manifestations and disease progressions of Mpox in both immunocompetent and immunocompromised individuals.

CASE PRESENTATION

Mpox In Immunocompetent Individuals

The first case involved a 40-year-old gentleman with a history of latent syphilis, who had been treated and remained serofast since October 2015. He reported onset of painful vesicles at the genitalia four days after a casual sexual encounter at a sex party in Kuala Lumpur, involving three local and four foreign male partners. He developed high fever on Day 11 post-exposure, with scattered vesicles erupting over the trunk and limbs. Physical examination revealed multiple papules with central necrotic crusts over the penis and glans, associated with penile oedema (Figure 1A-1F). Similar discrete pustules with perilesional erythema were spotted over the trunk and limbs. The total lesion observed was 20. His inguinal lymph nodes were enlarged.

Penile lesion swab and scab tested positive for MPXV by PCR. Urethral swab culture grew *Staphylococcus aureus*. He was isolated in the ward for a week and treated with intravenous amoxicillin-clavulanate and analgesia. All lesions resolved without scarring one month later (Figure 1G-1H).

Mpox In Immunocompetent Individuals With HIV Coinfection

The second patient was a 28-year-old man who has sex with men (MSM) with positive retroviral infection. He had been

This article was accepted: 02 June 2026
Corresponding Author: Wei Shan Tan
Email: weishantan23@gmail.com



Fig. 1: 1A – 1F: Patient 1, Day 11 of illness at presentation, Figure 1G - 1H: Patient 1, penile lesion resolved without scarring 1 month following treatment, Figure 1I - 1M: Patient 2, Day 7 of illness at presentation, Figure 1N – 1P: Patient 3, Perianal lesion at Week 3(presentation), Week 7 (Day 11 Tecovirimat) and Week 19 of illness (day of discharge), Figure 1Q – 1S: Patient 3, Philtrum lesion at Week 3 (presentation), Week 7 (Day 11 Tecovirimat) and Week 19 of illness (day of discharge), Figure 1T – 1V: Patient 3, Right Heel ulcer at Week 3 (presentation) , Week 7 (Day 11 Tecovirimat) and Week 19 of illness (day of discharge), Figure 1W – 1Y: Patient 3, Trunk, Week 3 (presentation), Week 7 (Day 11 Tecovirimat), and Week 19 of illness (day of discharge), Figure 1Z – 1AB: Patient 3, Scrotal Base, Week 3 (presentation), Week 7 (Day 11 Tecovirimat) and Week 19 of illness (day of discharge)

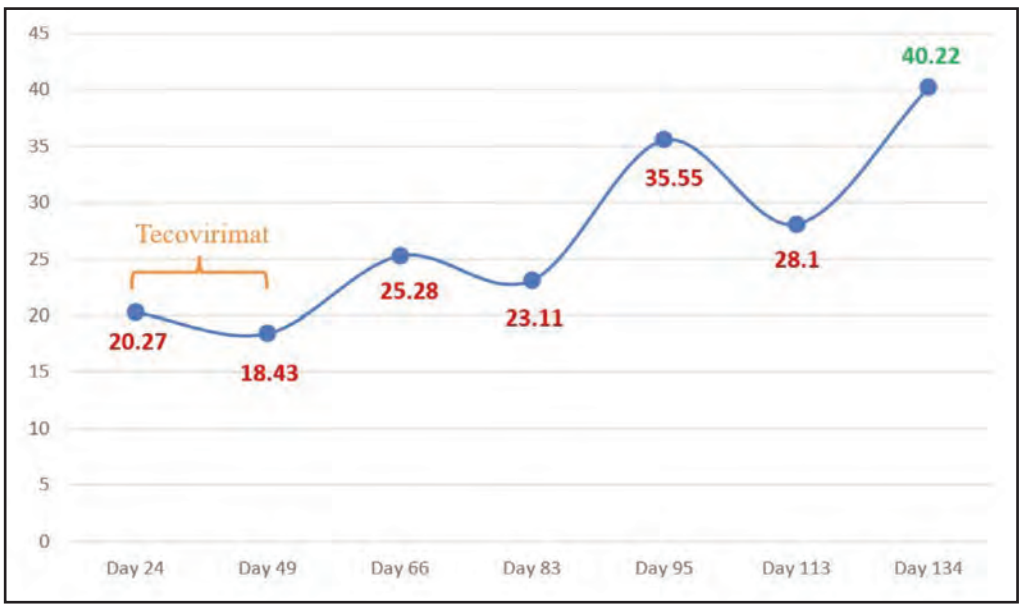

Fig. 2: Cycle of Threshold (Ct) of Mpox virus from perianal swab of Patient 30

commenced on antiretroviral therapy in 2022, but experienced treatment failure due to primary resistance, and was thus escalated to dolutegravir, lamivudine, and tenofovir since December 2024, with a CD4 count of 208 cells/µL. He presented with a one-week history of vesicles on the palms, soles, and arms, with fever for one day. His last reported sexual contact was two months prior, with a male partner from Penang. Clinically, scattered pustules were observed with erythematous rims over both palms, soles, and trunk (Figure 1J-1M). In total, 13 lesions were observed. Additionally, a single anal wart with multiple perianal erosions was noted.

Swabs and scabs over the lesion were positive for Orthopoxvirus DNA. Urethral swab was positive for *Ureaplasma urealyticum*. Screening for syphilis was reactive with a rapid plasma regain (RPR) titre of 1:1. Isolation in the ward was maintained for two weeks. Initially, oral acyclovir and doxycycline were prescribed for one week prior to Mpox confirmation. Three doses of intramuscular benzathine penicillin were administered at weekly intervals. The patient was instructed to perform potassium permanganate sitz baths. The patient was discharged in stable condition without complications. The patient was subsequently lost to follow-up.

Mpox In Immunocompromised Individuals With HIV Coinfection

The third patient was a 37-year-old MSM who first presented with multiple progressive, painful perianal ulcers for a week. No lesions were noted apart from the perianal ulcers. He was initially diagnosed with genital herpes and treated with a one-week course of oral acyclovir. Three weeks later, the lesions progressed, with an increasing number of crusted papules over the limbs, trunk, and face. Multiple scattered crusted ulcers with perilesional erythema over the scalp, hairline, face, neck, axilla, trunk, thighs, heels, and genitalia were observed. His perianal ulcers progressed into a large necrotic indurated plaque that extended from the perianal to the posterior scrotum and perineum region. (Figure 1N, 1Q, 1T, 1W, 1Z) The lesion count was almost 50.

His hepatitis B surface antigen, RPR (titre 1:8), and *Treponema pallidum* particle agglutination assay (TPPA) were positive. He was also diagnosed with retroviral disease with a CD4 count of 15 cells/µL. Polymerase chain reaction test from lesion scabs and swabs confirmed Mpox. A microbiological study of his genital ulcer grew Acinetobacter baumannii. He was hospitalised and isolated for a total of 14 weeks. During his isolation, he was initially treated with intravenous acyclovir for a 14-day course, which escalated to intravenous piperacillin/tazobactam without much improvement. He was then prescribed a 14-day course of oral tecovirimat 600mg bd in conjunction with anti-retroviral therapy consisting of dolutegravir, tenofovir, and emtricitabine. Clinical improvement was first observed at week 12 of the disease. All the crusts dropped off, leaving shallow ulcers except the ulcers at the perineum, which remained deep and undermining. Full recovery was achieved at week 16 of the disease. All ulcers healed with post-inflammatory dyspigmentation and atrophic scars, with scarring alopecia on his scalp. There were residual shallow ulcers at his perineum (Figure 1P, 1S, 1V, 1Y, 1AB). Repeated swabs of perineal ulcers at week 7, 9, 12, 14 of lesions showed persistent positive Mpox PCR. Figure 2 shows the trend of Cycle of threshold (Ct) value of the MPXV.

DISCUSSION

Unlike endemic regions where Mpox clade I is predominant, the Malaysia outbreak was associated with Mpox Clade IIb, affecting MSM primarily, and transmitted through sexual contact.[9] This case series illustrates the diverse clinical spectrum of Mpox, demonstrating that host immune status is pivotal in determining the disease presentation, severity, and duration. The contrasting clinical presentations of the second and third patients suggest that CD4 cell count is a key determinant of disease prognosis and duration. The second patient, with a CD4 count of 208 cells/µL, experienced a self-limiting course similar to that of the immunocompetent first patient. In contrast, the third patient, who had advanced immunosuppression with a CD4 count of 15 cells/µL, developed fulminant Mpox. These contrasting clinical presentations and disease courses emphasise the importance of host immune status in disease severity and recovery.

In a non-endemic country like Malaysia, the clinical presentation may be confused with human herpes virus infections. Specifically, the initial misdiagnosis of the third patient, who first presented with only perianal ulcers, may serve as a mimic of herpes simplex that may mask the diagnosis of Mpox. This serves as a reminder that healthcare professionals must maintain a high index of suspicion for Mpox infections, regardless of the patient's travel history. The discrepancies of the incubation period in second and third patients (ranging from weeks to months) deviate from the usual incubation period of 5 – 21 days. These discrepancies likely stem from underreporting or social desirability bias regarding sexual encounters. In Malaysia, the stigma surrounding HIV and homosexuality may result in intentional concealment of actual exposure timelines, posing a challenge for contact tracing and clinical diagnosis.

While Tecovirimat is the recommended agent for Mpox treatment,[10] Patient three clearly demonstrated that the standard 14-day course did not improve his condition as expected. A 14-day course of tecovirimat may be insufficient for individuals with profound immunosuppression. Persistently positive PCR results and low cycle threshold (Ct) values over 14 weeks suggest that, in the absence of functional immunity, viral clearance is markedly delayed. Extended duration of tecovirimat in combination with cidofovir has been described in severe Mpox infection in HIV infected patients in the United States.[10] Here in Malaysia, cidofovir and its prodrug brincidofovir are not available for the treatment of tecovirimat-refractory cases. The present experience suggests that whilst antivirals are important, recovery in advanced HIV cases remains achievable with gradual immune reconstitution provided by anti-retroviral therapy and high-quality supportive care. While the CDC recommends MVA-BN vaccination as post-exposure prophylaxis for individuals with known or presumed exposure to Mpox, currently, there are limited observational data on the effectiveness of post-exposure prophylaxis vaccination for Mpox.[1]

The clinical patterns of Mpox infection described here in Sarawak reflect the typical presentation of Clade IIb MPXV. The disease was more severe with longer disease in HIV-infected individuals with very low CD4 counts. All healthcare professionals should maintain a high index of suspicion, armed with vigilant screening and labouratory investigation, to diagnose the infection early. High-quality supportive care, together with immune reconstitution in advanced AIDS, is imperative for managing patients with fulminant Mpox.

REFERENCES

1. Titanji BK, Hazra A, Zucker J. Mpox Clinical Presentation, Diagnostic Approaches, and Treatment Strategies: A Review. JAMA 2024; 332(19): 1652-62.
2. Bunge EM, Hoet B, Chen L, Lienert F, Weidenthaler H, Baer LR, Steffen R. The changing epidemiology of human monkeypox—A potential threat? A systematic review. PLoS neglected tropical diseases 2022; 16(2):e0010141.
3. Bogacka A, Wroczynska A, Rymer W, Grzesiowski P, Kant R, Grzybek M, et al. Mpox unveiled: Global epidemiology, treatment advances, and prevention strategies. One Health 2025; 20: 101030.
4. World Health Organization, Mpox. , 2024 (accessed May 23, 2026) https://www.who.int/news-room/fact-sheets/detail/mpox
5. World Health Organization. Global Mpox Trends; published at May 22, 2026, available at (accessed May 26, 2026) https://worldhealthorg.shinyapps.io/mpx_global/#sec-global
6. Thieme AH, Zheng Y, Machiraju G, Sadee C, Mittermaier M, Gertler M et al. A deep-learning algorithm to classify skin lesions from mpox virus infection. Nat Med 2023; 29(3): 738-47.
7. Mitjà O, Ogoina D, Titanji BK, Galvan C, Muyembe JJ, Marks M, et al. Monkeypox. Lancet 2023; 401(10370): 60-74.
8. Yadav R, Chaudhary AA, Srivastava U, Gupta S, Rustagi S, Rudayni HA, et al. Mpox 2022 to 2025 Update: A Comprehensive Review on Its Complications, Transmission, Diagnosis, and Treatment. Viruses 2025; 17(6): 753.
9. Hisham NB, Rashid FA, Madon M, Masri SN, Mohd N. Mpox Infection in People With HIV: A Case Series in a Non- endemic Country. Malaysian Journal of Medicine and Health Sciences 2024; 20(SUPP11): 69-72.
10. Duong MT, Tebas P, Ancha B, Baron J, Chary P, Isaacs SN, et al. Combination of Extended Antivirals With Antiretrovirals for Severe Mpox in Advanced Human Immunodeficiency Virus Infection: Case Series of 4 Patients. Open Forum Infect Dis 2024; 11(3): ofae110.

CASE REPORT

Haemorrhagic hamartomatous polyp of the palatine tonsil

Hari KS Krishnan[1], Azwan Halim B Abdul Wahab[1], Asmah Hanim Bt Hamdan[2]

[1]Department of Otorhinolaryngology, Sultan Ahmad Shah Medical Centre @IIUM, Kuantan, Pahang, Malaysia, [2]Department of Pathology and Laboratory Medicine, Kulliyyah of Medicine, International Islamic University Malaysia (IIUM), Kuantan, Pahang, Malaysia

SUMMARY

Hamartomatous polyps of the palatine tonsil are extremely rare benign lesions. In published series, these polyps are uniformly described as pale, pink, or greyish, smooth-surfaced, pedunculated masses. We present a 25-year-old healthy man who reported a single episode of blood-streaked saliva following a meal. Intraoral examination revealed a grade 2 right tonsil bearing a black, mulberry-like, pedunculated mass arising from the superior pole. There was no active bleeding or clot. An excision biopsy of the lesion was performed under general anaesthesia. Grossly, the specimen measured 2.0 × 1.6 × 0.7 cm, was dark black, firm and had an irregular surface. Histopathological examination showed a congested, haemorrhagic polyp lined by stratified squamous epithelium, with a fibrotic stroma containing multiple lymphoid aggregates and abundant vascular channels. The features were consistent with a hamartomatous polyp (lymphoid polyp). The patient recovered uneventfully, and no recurrence was observed at six months. This case is notable because its black, mulberry-like appearance contrasts sharply with the typical pale or pink smooth surface documented in the literature. Recognizing this atypical presentation expands the clinical differential diagnosis of pigmented tonsillar lesions and reinforces the importance of complete surgical excision

INTRODUCTION

The palatine tonsils are bilateral lymphoepithelial organs located on the lateral oropharyngeal walls; together with the adenoids, lingual tonsil, and tubal tonsils, they constitute Waldeyer's ring. Their principal role is the sampling of inhaled and ingested antigens for immunological analysis.[1] Neoplasms of the palatine tonsil are uncommon, and malignant lesions - chiefly squamous cell carcinoma and lymphoma - far outnumber benign tumours.[2] Among benign tonsillar tumours, squamous papilloma is the most frequent; hamartomata's polyps are exceedingly rare.

Hamartomatous polyps of the palatine tonsil have been reported under varied nomenclature, including fibroepithelial polyp, lymphangiomatous polyp, lymphangiofibrolipomatous hamartomatous polyp, and lymphoid polyp.[3-8] Regardless of the label, the macroscopic descriptions in the literature are remarkably consistent: a unilateral, solitary, pedunculated or sessile mass with a smooth surface and a pale, pink, white, or yellowish hue.[3,5,6,9] A case of a tonsillar hamartomatous polyp deviating strikingly from the conventional appearance is reported herein, presenting as a black, mulberry-like lesion. This atypical clinical morphology prompted the present report and may assist clinicians in formulating broader differential diagnoses for pigmented tonsillar masses.

CASE PRESENTATION

A 25-year-old man, a lifelong non-smoker and non-drinker with an unremarkable medical history, presented with a one-day history of blood-tinged saliva. He noticed minimal fresh blood streaking his saliva immediately after a meal; there was no ongoing oozing, epistaxis, haematemesis, or melaena. He denied dysphagia, odynophagia, foreign-body sensation, snoring, or obstructive sleep apnoea symptoms. He had no history of recurrent tonsillitis and was not taking antiplatelet or anticoagulant medications. The patient was afebrile throughout, with no signs of localised or systemic infection.

Intraoral examination showed bilateral grade 2 (Brodsky scale) tonsils. A black, mulberry-like pedunculated mass, approximately 2 cm in greatest dimension, was seen arising from the superior pole of the right tonsil (Figure 1). The overlying mucosa was intact, with no active bleeding, ulceration, or perilesional erythema. There was no cervical lymphadenopathy. Findings from the remainder of the ear, nose, throat, and systemic examinations were normal. In view of the lesion's superficial, pedunculated nature and the absence of bruits, pulsatility, or compressive symptoms, imaging studies (Doppler ultrasonography, computed tomography, or magnetic resonance imaging) were deemed unnecessary.

An excision biopsy with a clear macroscopic margin was performed under general anaesthesia. The polyp was pedunculated, attached to the superior tonsillar pole by a narrow stalk. Its gross appearance was uniformly black and firm, with a lobulated, irregular surface; it measured 2.0 × 1.6 × 0.7 cm. The stalk base was completely excised without entering the tonsillar parenchyma.

Histopathological examination demonstrated a polypoidal fragment covered partly by stratified squamous epithelium and partly by ulcerated, haemorrhagic surface tissue (Figure 2). The stroma was densely fibrotic and contained numerous lymphoid aggregates with reactive germinal centres. Dilated, congested vascular channels were scattered

This article was accepted: 6 February 2026
Corresponding Author: Hari K S Krishnan
Email: harikrish300@gmail.com

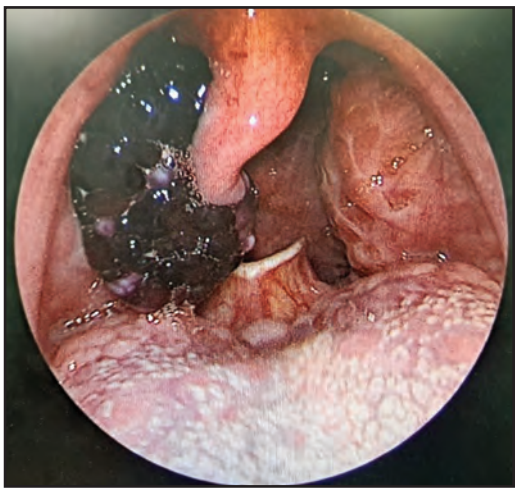

Fig. 1: Black, mulberry like mass arising from the right tonsil

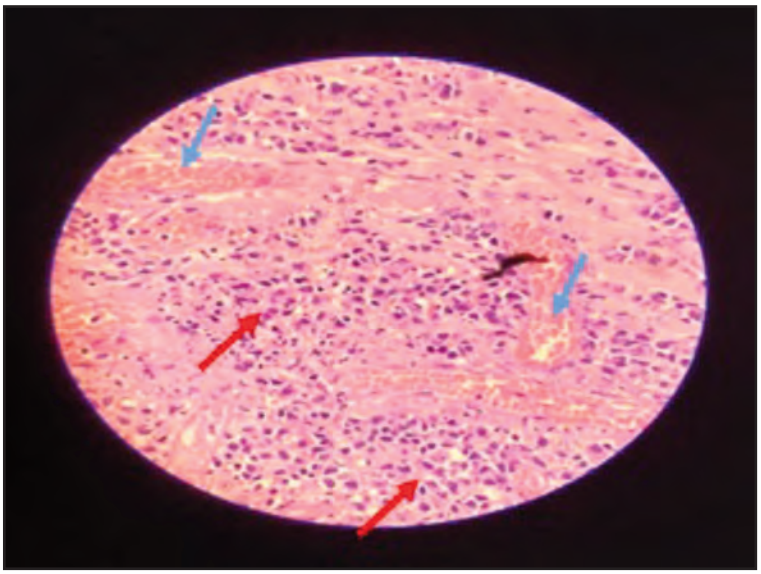

Fig. 2: Histopathological examination; haematoxylin and eosin (H&E) staining, 400x magnification. Blue arrow: vascular channels, red arrow: lymphoid aggregates

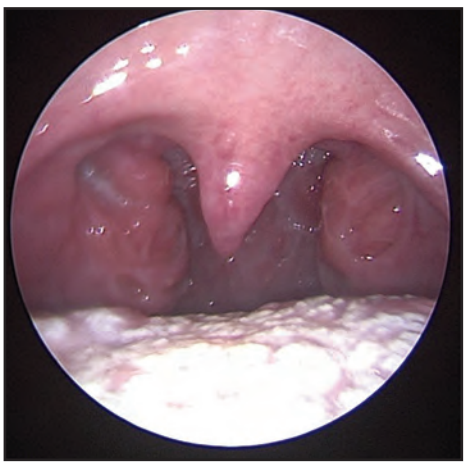

Fig. 3: Clinical examination 6 months after excision

Table I: Comparison of the present case with previously reported tonsillar hamartomatous polyps

Author/Year	Age/Sex	Symptoms	Gross Appearance (Colour/Surface)	Size	Management	Outcome
Kardon et al. (2000) [9]	Mean 25.2y; M:F 1:1	Dysphagia, sore throat, foreign body sensation	Pale, tan, pink; smooth, pedunculated	0.5–3.8 cm	Excision ± tonsillectomy	No recurrence
Sethi et al. (2011) [2]	18y/M	Recurrent sore throat, fever, dysphagia, foreign body sensation	Grayish-pink, smooth, pedunculated	2 × 1 × 0.5 cm	Tonsillectomy	No recurrence
Khatib et al. (2015) [6]	14y/M	Dysphagia, dysarthria	Pale, smooth surface	Not specified	Tonsillectomy	No recurrence
do Amaral-Silva et al. (2023) [3]	22y/F	Foreign body sensation	Pinkish-white, pedunculated	Not specified	Excisional biopsy	No recurrence
Present case (2026)	25y/M	Blood-streaked saliva	Black, mulberry-like, irregular surface	2.0 × 1.6 × 0.7 cm	Excision (pedicle alone)	No recurrence at 6 months

Abbreviations: y, years; M, male; F, female.

throughout the stroma. A diagnosis of hamartomatous polyp (lymphoid polyp) was established. No cytological atypia or malignant features were seen.

The postoperative course was uneventful. At a six-month follow-up visit, the right tonsil had healed completely with no visible residual or recurrent lesion (Figure 3), and the patient remained asymptomatic.

DISCUSSION

The hamartomatous polyp of the palatine tonsil is a focal malformation consisting of mature, disorganised tissue indigenous to the tonsil. Histologically, the lesion comprises lymphoid aggregates, fibrotic stroma, and variably dilated vascular channels, which together justify the multiple names encountered in the literature.[3-9] In a seminal clinicopathologic series of 26 cases, Kardon et al. described uniformly pedunculated or sessile polyps with a smooth, pale to tan cut surface; none exhibited haemorrhagic discolouration.[9] A detailed comparison of the present case with key published cases is provided in Table I. A 2023 literature review by do Amaral[3] Only occasional reports mention a reddish hue attributed to vascular prominence; a truly black, mulberry-like exterior has not been previously documented.

The black colour in the present case can be explained by the striking vascular congestion and intralesional haemorrhage seen on microscopy. The patient's symptom of blood-streaked saliva immediately after a meal suggests mechanical trauma during mastication, which may have caused capillary rupture within the already congested polyp, leading to extravasation of blood and superficial haemosiderin deposition. This subacute haemorrhage conferred the dark, irregular, mulberry-like appearance that initially raised a suspicion of a vascular malformation or melanoma. However, the absence of pulsatility, rapid growth, or regional lymphadenopathy, together with the typical pedunculated architecture, pointed toward a benign hamartomatous process.

The differential diagnosis of a dark tonsillar mass includes arteriovenous malformation, haemangioma, angiosarcoma, melanoma, and thrombosed varix. Because of the lesion's small size and pedunculated, superficial attachment, imaging was not mandatory in this case; however, when the nature of a pigmented tonsillar lesion is uncertain, a CT or MR angiography can delineate vascular flow and exclude a high.

Management of tonsillar hamartomatous polyps is complete surgical excision. While some authors advocate concurrent tonsillectomy, recurrence has not been reported when the pedicle is completely excised, even without concomitant tonsillectomy.[2-3] In the present case, stalk excision alone yielded a disease.[2]

This case reinforces the understanding that tonsillar hamartomatous polyps may deviate considerably from their classic pale, smooth appearance. Otolaryngologists should include this entity in the differential diagnosis when evaluating any irregular, pigmented tonsillar mass, thereby avoiding unnecessarily aggressive investigations whilst ensuring prompt and complete excision.

CONCLUSION

We present a rare hamartomatous polyp of the palatine tonsil that exhibited a black, mulberry-like appearance never before highlighted in the literature. This atypical morphology, driven by vascular congestion and haemorrhage, expands the known clinical spectrum of tonsillar lymphoid polyps. Complete surgical excision of the pedicle is curative and prevents recurrence.

REFERENCES

1. Arambula A, Brown JR, Neff L. Anatomy and physiology of the palatine tonsils, adenoids, and lingual tonsils. World J Otorhinolaryngol Head Neck Surg 2021; 7(3): 155-60.
2. Sethi A, Sethi D, Bansal R. True Hamartoma of the Tonsil. Indian J Otolaryngol Head Neck Surg 2011; 63(Suppl 1): 99-101.

3. do Amaral-Silva GK, Ribeiro-Brizola J, Santos ÁA, Cieslak-Sanches SR, Chicrala GM, Gaetti-Jardim EC, et al. Hamartomatous Polyp of the Palatine Tonsil: A Case Report and Critical Literature Review. Head Neck Pathol 2023; 17(2): 502-8.
4. Mehta S, Jha S, Adhya AK, Mitra S. Lymphangiofibrolipomatous hamartomaous polyp of tonsil. BMJ Case Reports CP. 2019; 12(8): e230030.
5. Mardekian S, Karp JK. Lymphangioma of the Palatine Tonsil. Archives of Pathology & Laboratory Medicine 2013; 137(12): 1837-42.
6. Khatib Y. Lymphangiomatous Polyp of Palatine Tonsil in A Child Presenting with Dysphagia and Dysarthria. JCDR. 2015.
7. Goulioumis A, Gkorpa M, Kekempanou K, Kourelis K. Hamartomatous polyp of the palatine tonsil: histological considerations and review of the literature. BMJ Case Reports CP 2023; 16(5): e254536.
8. Singh M, Mundi DK, Kaur I, Kaur A. Hamartomatous Polyp of the Tonsil: A Case Report. Nigerian Journal of Clinical Practice 2017; 20(6): 774.
9. Kardon DE, Wenig BM, Heffner DK, Thompson LDR. Tonsillar Lymphangiomatous Polyps: A Clinicopathologic Series of 26 Cases. Modern Pathology 2000; 13(10): 1128-33.

CASE REPORT

Falsarthrobacter nasiphocae PD-associated peritonitis: A rare pathogen in PD-associated peritonitis

Yi Liang Lim, MD, Gan Wee Fu, FRCP, YL Lim, WF Gan

Infectious Disease Unit, Internal Medicine Department, Hospital Melaka

SUMMARY

Peritoneal dialysis (PD)-associated infection remains a major cause of morbidity and technique failure among PD patients, with approximately 10–20% of peritonitis episodes resulting in permanent discontinuation of PD. We report a case of PD-associated peritonitis caused by a rare pathogen, Falsarthrobacter nasiphocae. The patient presented with cloudy PD effluent, consistent with the typical clinical features of PD-associated peritonitis. Despite treatment with first-line empirical antibiotics in accordance with local guideline recommendations, no clinical improvement was observed. Microbiological identification of the causative organism was additionally challenging and only available after completion of treatment. The episode was ultimately complicated by PD technique failure, necessitating transition to haemodialysis for renal replacement therapy. This is a single case report of PD-associated peritonitis involving Falsarthrobacter nasiphocae. The clinical significance of Falsarthrobacter nasiphocae in PD-associated peritonitis and its contribution to PD technique failure remain uncertain, given the limited data on organism-specific clinical course and antimicrobial susceptibility. This case highlights the importance of early identification of rare pathogens and may contribute to future guideline discussions on the management of PD-associated peritonitis caused by rare pathogens in patients with end-stage kidney disease (ESKD).

INTRODUCTION

The incidence of end-stage kidney disease (ESKD) requiring dialysis has been increasing rapidly in Malaysia, with further growth anticipated.[1] Peritoneal dialysis (PD) remains a crucial mode of long-term renal replacement therapy, offering overall survival comparable to haemodialysis and potentially reducing dialysis-associated healthcare costs.[2-3] However, PD is associated with several complications, including PD-associated peritonitis, which remains a leading cause of morbidity among PD patients, with 10–20% of peritonitis episodes resulting in permanent discontinuation of PD.[4]

Despite the availability of the 2022 International Society for Peritoneal Dialysis guidelines for the diagnosis and management of PD-associated peritonitis, including antibiotic recommendations, data regarding rare or atypical causative pathogens remain limited.

A rare case of PD-associated peritonitis caused by Falsarthrobacter nasiphocae. To the best of our knowledge, no similar cases involving this organism in a PD patient have been identified.

CASE PRESENTATION

A 68-year-old male with a history of diabetes mellitus, hypertension, and dyslipidaemia had been undergoing peritoneal dialysis (PD) for ESKD for the past three years. His serial Staphylococcus kloosii PD-associated peritonitis eight months prior, which was successfully treated. Dialysis effluent culture and sensitivity reports of the previous PD-associated peritonitis are included in Table I. A PD training program was repeated during the episode of Staphylococcus kloosii PD-associated peritonitis, and he demonstrated favourable technique. Other than that, he had no hospitalizations for fluid overload.

The patient presented with cloudy dialysis effluent for three days, without other symptoms such as abdominal pain, loose stools, or fever. Physical examination was unremarkable, with no features suggestive of exit-site or tunnel infection. Abdominal X-ray showed the Tenckhoff catheter in situ. Inflammatory markers were not significantly elevated, with a white blood cell count of 7.3×10^9/L. Dialysis effluent microscopic examination revealed an elevated white cell count of 380 cells/mm^3, with 95% polymorphonuclear cells. Empirical intraperitoneal (IP) antimicrobials — comprising IP cefazolin and IP ceftazidime, along with syrup nystatin — were initiated in accordance with local guidelines.

By day 4 of treatment, the dialysis effluent remained cloudy. Repeat dialysis effluent microscopic examination continued to show elevated cell counts of 220 cells/mm^3, with 95% polymorphonuclear cells. Preliminary culture demonstrated microbial growth; however, organism identification by Gram stain and standard MALDI-TOF techniques was unsuccessful. Consequently, IP antibiotics were escalated to IP vancomycin and IP meropenem.Clinical improvement ensued, with decreasing effluent turbidity and a cell count of 6 cells/mm^3, comprising predominantly polymorphonuclear cells. He completed a total of three weeks of IP antibiotics and was discharged in stable condition.

The dialysis effluent sample was sent to the national reference labouratory (the Institute for Medical Research, Malaysia) for further identification and antibiotic susceptibility testing. The causative organism was identified

This article was accepted: 9 June 2026
Corresponding Author: Yi Liang Lim
Email: lim.95@hotmail.com

Table I: PD effluent culture and sensitivity

Dates	PD effluent C+S
24th of March 2024	Staphylococcus kloosii Sensitive to Vancomycin(MIC 1.5ug/ml) Resistant to Fusidic acid, Oxacillin
5th of November 2024	Falsarthrobacter nasiphocae Sensitive to Vancomycin(MIC 1.5 ug/ml) Resistant to Ceftriaxone(MIC 4 ug/ml) Intermediate to Penicillin(MIC 0.25 ug/ml)
8th of November 2024	(Formal report was released on 23rdDecember 2024)

PD: Peritoneal Dialysis; C+S: culture and sensitivity; MIC: Minimal Inhibitory Concentration

Table II: Case reports of rare pathogens in PD-associated peritonitis

Author	Age, sex	Symptoms	Organism	Antibiotic	Outcome
OzantHelvaci et al.[6]	68 years old, male	Turbid PD effluent, abdominal pain	Serratia liquefaciens, gram-negative bacterium	IP Ceftazidime	PD catheter removal
Jae Un Lee et al.[7]	63years old, male	Turbid PD effluent, abdominal pain	Sphingomonaspaucimobilis, aerobic Gram-negative bacillus	IP imipenem	PD catheter removal
Konner P et al.[8]	46 years old, male	Impaired ultrafiltration, turbid PD effluent	Neisseria sicca, gram-negative cocci	Oral levofloxacin	Resolution
Waleed Albaker.[9]	24 years old, female	Abdominal pain	Bacillus licheniformis, aerobic, gram-positive	IP vancomycin	Resolution

IP: Intraperitoneal; PD: Peritoneal Dialysis

as Falsarthrobacter nasiphocae via 16S rRNA gene sequencing, together with its antimicrobial susceptibility profile.

Two months after the PD-associated peritonitis episode, the patient was readmitted with a one-week history of symptoms of fluid overload. No culture was taken during that admission, as the clinical presentation did not suggest infection. He was discharged in good condition. However, the patient's overall clinical picture showed persistent fluid overload during multiple visits and assessments at the nephrology clinic. Evaluation suggested PD membrane failure; the peritoneal equilibration test showed a weekly Kt/V of 1.3, while 24-hour urine and dialysate volume was 600 mL. He was counseled for transition to hemodialysis as an alternative mode of renal replacement therapy, and he eventually underwent the procedure.

DISCUSSION

Peritoneal dialysis (PD)-associated peritonitis remains a significant complication in PD patients, contributing not only to increased morbidity and hospitalization but also frequently resulting in technique failure and transition to haemodialysis.[4] The 2022 International Society for Peritoneal Dialysis guidelines provide a structured approach to diagnosis and empiric management. However, peritonitis caused by rare or atypical organisms presents a unique diagnostic and therapeutic challenge due to limited clinical data.

This case describes an unusual aetiology of PD-associated peritonitis — Falsarthrobacter nasiphocae, a rare Gram-positive, aerobic bacillus with no previously established pathogenic role in such cases. The organism was initially described in marine mammals and environmental settings and has only recently been implicated in human disease, with the first known case involving a periprosthetic joint infection.[5] The isolation of this rare pathogen from a prosthetic joint and a PD catheter may reflect a shared pathogenic mechanism, such as colonisation of foreign bodies.[5] Similarly, in both cases, this organism was found to be sensitive to vancomycin and resistant to ceftriaxone.[5] No similar cases of PD-associated peritonitis attributable to Falsarthrobacter nasiphocae. Its role as a human pathogen remains poorly understood, raising questions about its route of entry, environmental reservoirs, virulence potential, and host susceptibility factors.

As Falsarthrobacter nasiphocae was not identifiable by routine culture techniques, definitive identification was achievable only through molecular diagnostic testing at a national reference laboratory. The case was further complicated by the patient's lack of response to routine empirical antibiotics. Failure to respond to standard empirical therapy should prompt consideration of atypical pathogens. When conventional diagnostic work-up is inconclusive, early utilisation of molecular diagnostic testing, such as 16S rRNA sequencing, may facilitate timely diagnosis and guide targeted antimicrobial therapy.

This case also highlights the therapeutic challenges in managing an atypical pathogen. The lack of susceptibility data and the absence of standardized treatment guidelines complicate clinical decision-making. Severalcase reports have described rare pathogens in PD-associated peritonitis; some cases responded to antibiotic therapy, whilst others required PD catheter removal.[6-9]

In this case, clinical resolution was achieved following escalation to IP vancomycin and meropenem. However, PD technique failure occurred several months later, with no other obvious precipitating risk factors identified. The significance of Falsarthrobacter nasiphocae and its long-term impact remain unknown.

The absence of prior reports of Falsarthrobacter nasiphocae as a cause of PD-associated peritonitis represents an important limitation in contextualizing this case within the existing literature. As this report reflects a single clinical observation, the findings should be interpreted with appropriate caution. The organism's microbiological profile and virulence potential in the peritoneal dialysis setting remain poorly characterised, thereby limiting evidence-based guidance for management. These limitations underscore the importance of systematic reporting and support the need for a national or regional registry to capture atypical PD peritonitis pathogens and their associated outcomes, which may help inform future diagnostic and therapeutic strategies. To the best of available knowledge, this is the first case report of Falsarthrobacter nasiphocae in PD-associated peritonitis. No similar cases have been identified. Emerging rare pathogens in PD-associated peritonitis represent a growing clinical concern, given the challenges in establishing a definitive diagnosis and selecting appropriate therapy. As illustrated in this case, PD-associated peritonitis caused by a rare organism such as Falsarthrobacter nasiphocae may result in clinically significant consequences, including PD technique failure, even when there is apparent clinical resolution. Delayed pathogen identification may impede timely administration of targeted antimicrobial therapy, potentially contributing to PD technique failure as a long-term consequence. In this context, the use of molecular diagnostic techniques may play a complementary role in improving early pathogen detection. Furthermore, enhanced case reporting and systematic data collection are essential to better characterise the clinical course, antimicrobial susceptibility profiles, and optimal management of PD-associated peritonitis due to uncommon organisms.

REFERENCES

1. Bujang MA, Adnan TH, Hashim NH, Mohan K, Kim Liong A, Ahmad G, et al. Forecasting the Incidence and Prevalence of Patients with End-Stage Renal Disease in Malaysia up to the Year 2040. International Journal of Nephrology [Internet] 2017; 2017: 10-5.
2. Vicentini CA de A, Ponce D. Comparative analysis of patients' survival on haemodialysis vs. peritoneal dialysis and identification of factors associated with death. Brazilian Journal of Nephrology 2022;
3. Bavanandan S, Ahmad G, Teo AH, Chen L, Liu FX. Budget Impact Analysis of Peritoneal Dialysis versus Conventional In-centre Haemodialysis in Malaysia. Value in Health Regional Issues 2016; 9: 8-14.
4. Knapp C, Li S, Kou C, Wetmore JB, Johansen KL. Peritoneal Dialysis-Associated Peritonitis Rates in the Outpatient and Hospital Setting Among Incident Dialysis Patients With Medicare, 2009–2018. Kidney Medicine [Internet] 2024; 7(1): 100931.
5. Tay ST, Azhar Mahmood Merican, Jabar KA, Rukumani Devi Velayuthan, Khairul Anwar Ayob, Lee JL, et al. Falsarthrobacter nasiphocae periprosthetic joint infection. International Journal of Infectious Diseases [Internet] 2023; 136: 77-80.
6. Ozant Helvaci, Kenan Hızel, Guz G, Turgay Arinsoy, Ulver Derici. A very rare pathogen in peritoneal dialysis peritonitis: Serratia liquefaciens. Saudi Journal of Kidney Diseases and Transplantation [Internet] 2019; 30(3): 738-8.
7. Jae Un Lee, Joong Keun Kim, So Hee Yun, Moon Sik Park, Na Eun Lee, Sun IO, et al. A case of peritoneal dialysis-associated peritonitis caused by Sphingomonas paucimobilis. Kidney research and clinical practice 2013; 32(2): 78-80.
8. Konner P, Watschinger B, Apfalter P, Hörl WH, Vychytil A. A case of continuous ambulatory peritoneal dialysis peritonitis with an uncommon organism and an atypical clinical course. American journal of kidney diseases :the official journal of the National Kidney Foundation [Internet] 2001; 37(1): E10
9. Waleed Albaker. Successful Treatment of Bacillus licheniformis Peritonitis in Peritoneal Dialysis Patient with Intraperitoneal Vancomycin: A Case Report. International Medical Case Reports Journal [Internet] 2021; Volume 14: 215-8.

Delayed antiviral therapy in adult varicella: Severe infection and aesthetic implications

Boon Khang Soh, MBBS[1], Wei Fai Leong, MBBS[1], Wan Aznita Wan Abdullah, MD[1], Shin Chian Chua, MD[1], Zhi Xian Cindy Ngu, MBBS[2]

[1]Independent Practitioner, Malaysia, [2]Hospital Sibu, Malaysia

SUMMARY

Background: Varicella-zoster virus infection is commonly self-limiting in childhood. However, adults may present with increased severity, higher complication rates, and long-term cutaneous sequelae. Early initiation of antiviral therapy within 72 hours of rash onset is important in reducing disease burden. Case Presentation: A man in his 20s, a college student residing in a campus hostel, presented with a 7-day history of fever, malaise, and a progressively worsening generalised pruritic vesiculopustular rash. He reported recent exposure to a classmate diagnosed with chickenpox and had no prior history of childhood varicella or varicella vaccination. He reported no other relevant medical history. He initially sought medical attention on day 3 of illness and was managed symptomatically, without initiation of antiviral therapy. The clinical condition subsequently deteriorated, with increasing lesion burden, pustulation, and severe pruritus, particularly over the face. On day 7, he was clinically diagnosed with varicella with severe cutaneous involvement complicated by secondary bacterial infection. He was treated with oral valaciclovir, amoxicillin-clavulanate, and bilastine for 5 days. Although acute lesions resolved, extensive post-inflammatory hyperpigmentation and atrophic scarring developed over the face and body, resulting in significant psychosocial distress. Patient-reported outcome assessment (SCAR-Q) demonstrated marked improvement in appearance and symptoms after treatment but persistent psychosocial impact. Conclusion: This case highlights the importance of timely antiviral therapy in adult varicella to reduce complications and long-term aesthetic sequelae. Prompt recognition of secondary bacterial infection and timely antibiotic treatment are essential. Early intervention is particularly important in cases with facial involvement to reduce cosmetic and psychosocial impact.

INTRODUCTION

Varicella-zoster virus (VZV) infection is commonly regarded as a benign, self-limiting illness characterised by a prodromal fever and generalised vesicular rash. However, in adults, the clinical course may be substantially more severe, with higher rates of complications and morbidity — particularly among immunocompromised individuals — although severe disease may also occur in otherwise healthy adults.

Early initiation of antiviral therapy, such as acyclovir or valaciclovir, within 24–72 hours of rash onset is recommended to reduce viral replication, limit disease severity, and prevent complications.[1,2] Delayed presentation or initial under-recognition in primary care may result in missed therapeutic opportunities.

In the absence of timely antiviral therapy, ongoing viral replication may lead to more extensive disease and increased susceptibility to complications, including secondary bacterial infection and, less commonly, systemic involvement such as pneumonia or neurological complications.[2]

We report a case of adult varicella with delayed initiation of antiviral therapy, resulting in severe cutaneous involvement complicated by secondary bacterial infection and subsequent aesthetic sequelae. This case highlights the importance of early recognition and prompt antiviral treatment in primary care to reduce both clinical complications and long-term morbidity.

CASE PRESENTATION

A man in his 20s presented with a 7-day history of fever, malaise, and a generalised pruritic rash. The eruption initially appeared as papules over the trunk and subsequently spread to the back, chest, and face, progressing to vesicles and subsequently pustules. He was a college student residing in a campus hostel. The patient reported recent exposure to a classmate diagnosed with chickenpox. The patient reported no prior history of chickenpox during childhood and had not received varicella vaccination. The patient had no known immunocompromising condition, malignancy, chronic systemic illness, or regular immunosuppressive medication use.

He first sought medical attention on day 3 of illness and was clinically diagnosed with varicella. He was managed symptomatically with antipyretics and antihistamines, without initiation of antiviral therapy.

Despite initial treatment, the condition worsened, with an increasing number of lesions, progression to pustules, and severe pruritus, particularly over the face. He sought a second opinion on day 7 of illness. Cutaneous examination revealed widespread polymorphic lesions involving the face and trunk, comprising papules, vesicles, and pustules at varying stages of development. Multiple lesions demonstrated central crusting, particularly over the facial region. The distribution predominantly involved the face, anterior chest, and

This article was accepted: 09 June 2026
Corresponding Author: Boon Khang Soh
Email: drjimmsoh@gmail.com

Table I: Recommended antiviral therapies for adult varicella[2]

Clinical Scenario	Drug	Adult Dose	Duration	Major Toxicities
Immunocompetent patients	Acyclovir	800mg po 5 times daily	5-7 days	None; minor nausea or headache
	Valaciclovir	1g po three times daily	5-7 days	None; minor nausea or headache
	Famciclovir	500mg po three times daily	5-7 days	None; minor nausea or headache
	Brivudin	125mg po once daily	5-7 days	Potentially lethal interaction with fluropyrimidines (e.g, 5-fluorouracil)
Immunocompromised patients / disseminated VZV syndrome (e.g., encephalitis, pneumonitis)	Intravenous Acyclovir	10-15mg/kg every 8 hours	7-10 days	Nephrotoxicity (rare); CNS disturbances
Acyclovir-resistant VZV	Intravenous Foscarnet	60-90mg/kg every 12 hours until healed	>10days	Nephrotoxicity (common); electrolyte disturbance (common), seizure, arrhythmias, anaemia, genital ulcers

Table II: Impact of antiviral therapy timing on clinical and aesthetic outcomes in adult varicella

Timing of antiviral therapy	Clinical outcomes	Aesthetic outcomes
≤72 hours of rash onset	Reduced lesion formation, faster recovery	Reduced risk of post-inflammatory hyperpigmentation (PIH) and scarring
Delayed (>72 hours)	Progressive lesion development and increased risk of complications	Increased risk of PIH, atrophic scarring, and possible keloid formation in susceptible individuals

posterior trunk (Figure 1). No signs of systemic involvement were noted.

A diagnosis of varicella with extensive cutaneous involvement complicated by secondary bacterial infection was established, and the patient was commenced on oral valaciclovir 500 mg twice daily, amoxicillin-clavulanate 625 mg twice daily, and bilastine 20 mg twice daily for 5 days.

The diagnosis was made clinically, based on the characteristic polymorphic eruption consisting of papules, vesicles, pustules, and crusts at different stages of evolution in the presence of fever and malaise. Laboratory confirmation with polymerase chain reaction (PCR) testing was not performed.

At the one-week follow-up, clinical improvement was noted with resolution of active lesions. However, extensive post-inflammatory hyperpigmentation and atrophic scarring developed over the face and body, negatively affecting self-esteem. Patient-reported outcome assessment using the SCAR-Q demonstrated substantial improvement in appearance (25 to 75) and symptom domains (33.3 to 83.3). However, psychosocial scores showed only modest improvement (33 to 41.6), suggesting persistent psychological impact despite clinical recovery. Cutaneous findings at 1 week post-treatment are shown in Figure 2.

At three weeks post-treatment, persistent post-inflammatory hyperpigmentation and atrophic scarring were noted over the face, anterior trunk, and posterior trunk, with no active lesions. These findings are illustrated in Figure 3.

DISCUSSION

Varicella is a highly contagious infection caused by the varicella-zoster virus (VZV), typically presenting with a prodrome of pyrexia and malaise, followed by a polymorphic eruption consisting of macules, papules, vesicles, and crusts at different stages of evolution, with possible residual scarring. Although generally self-limiting, varicella in adults is associated with a more severe clinical course, increased lesion burden, and a higher risk of complications.[1]

In routine primary care practice, varicella is commonly diagnosed clinically. Laboratory confirmation is generally reserved for atypical presentations, immunocompromised patients, or cases where the diagnosis is uncertain. Antiviral therapy should not be delayed while awaiting confirmatory testing when clinical suspicion is high.[1,2] The patient in this case presented with clinical features consistent with varicella; however, initiation of antiviral therapy was delayed. Although varicella vaccination is cost-effective for prevention, it has no role in the treatment of established infection. In symptomatic patients, antiviral therapy remains essential. In Malaysia, although there is no single unified national guideline dedicated exclusively to uncomplicated varicella, current practice in primary care is aligned with Ministry of Health formularies and international recommendations. Oral acyclovir remains the mainstay of treatment and is commonly prescribed at a dose of 800 mg five times daily in adults. Recommended antiviral therapies for adult varicella are summarised in Table I.

Early initiation of antiviral therapy is critical, as viral replication typically peaks within the first 24–72 hours of rash onset. Initiation of treatment within this window has been shown to reduce the duration of fever, shorten the time to crusting from 7.4 to 5.6 days (approximately 2 days), reduce the peak lesion count by 46%, and decrease overall disease severity.[3,4] In this case, delayed antiviral initiation beyond the optimal therapeutic window likely contributed to increased lesion burden and subsequent aesthetic sequelae. The impact of timing of antiviral therapy on clinical and aesthetic outcomes is summarised in Table II.[3,4]

Delayed initiation of antiviral therapy results in diminished therapeutic efficacy. Continued viral replication leads to progression of cutaneous lesions and increased inflammatory burden, contributing to more extensive disease involvement.

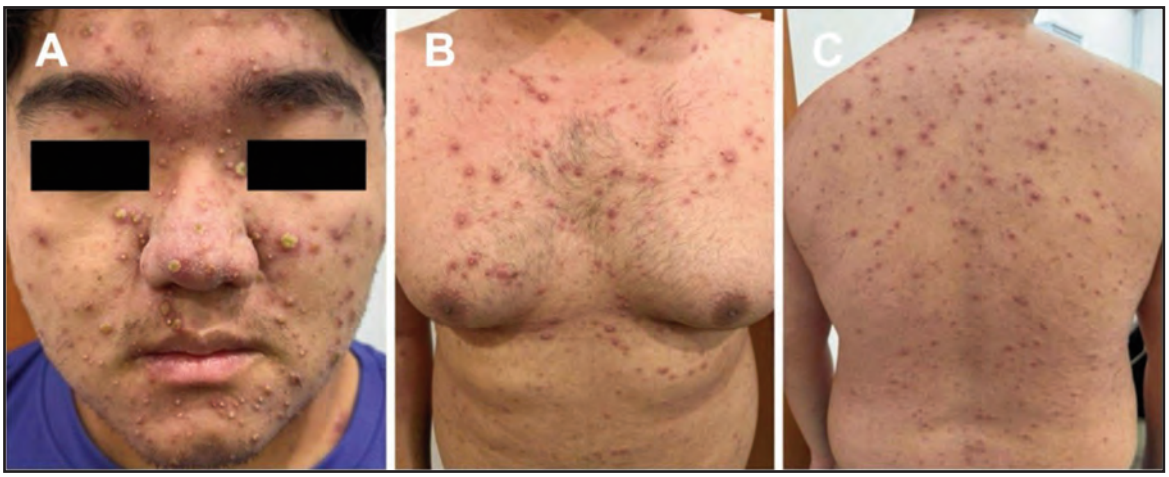

Fig. 1: Acute cutaneous involvement demonstrating (A) facial, (B) anterior trunk, and (C) posterior trunk distribution of multiple vesiculopustular lesions

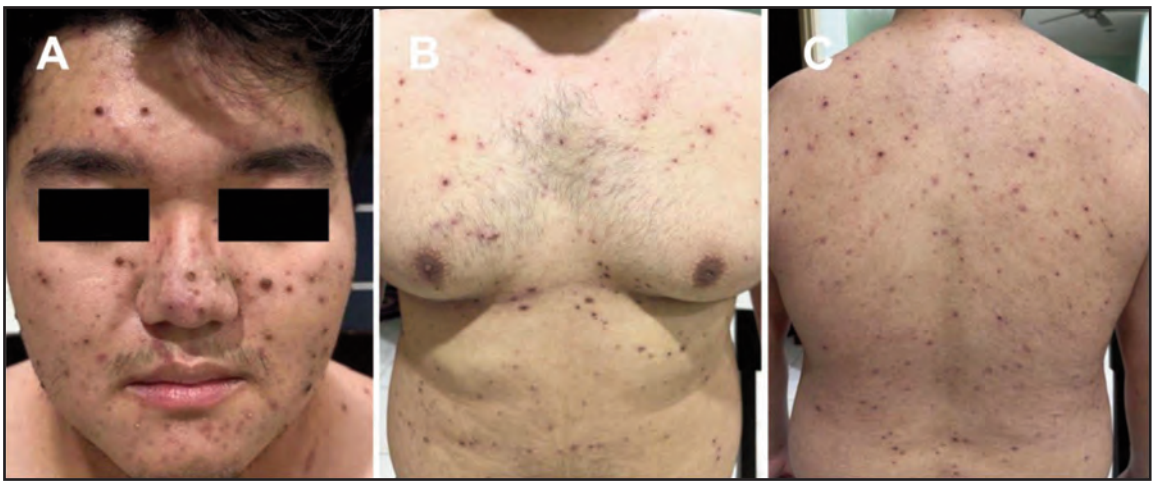

Fig. 2: Cutaneous findings at 1 week post-treatment demonstrating (A) facial, (B) anterior trunk, and (C) posterior trunk distribution of resolving lesions with residual crusting and post-inflammatory changes

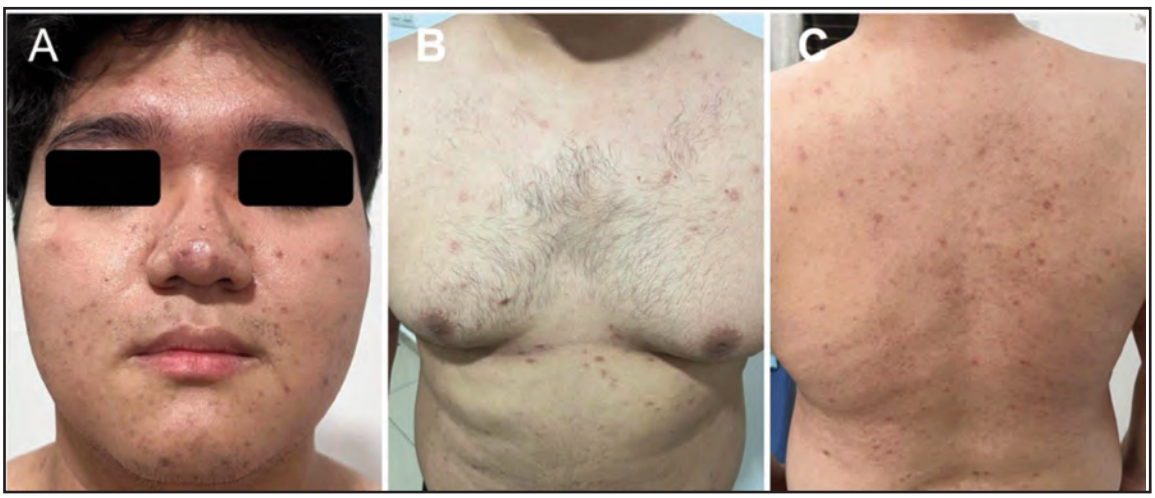

Fig. 3: Cutaneous findings at 3 weeks post-treatment demonstrating residual post-inflammatory hyperpigmentation and atrophic scarring involving (A) face, (B) anterior trunk, and (C) posterior trunk

The widespread vesiculopustular lesions observed in this patient reflect a more severe manifestation of varicella, consistent with findings reported in adult cases.[1,5]

Secondary bacterial infection represents one of the most frequently encountered complications of varicella. Disruption of the epidermal barrier due to vesicle formation and scratching predisposes to bacterial colonisation and superinfection. These infections may manifest as pustulation, crusting, cellulitis, or more severe soft tissue involvement.[1,6]

The presence of purulent crusting and pustular lesions in this patient is consistent with secondary bacterial superinfection, which further exacerbates tissue inflammation and delays healing. In severe cases, life-threatening complications such as varicella gangrenosa and sepsis have been reported.[7] Importantly, complications of varicella are not limited to cutaneous involvement. Systemic complications, including neurological, respiratory, and ocular manifestations, have been described, even in immunocompetent individuals.[8]

From an aesthetic perspective, the severity and extent of inflammation play a pivotal role in determining long-term cutaneous outcomes. Extensive inflammatory lesions, particularly when complicated by secondary bacterial infection, are associated with increased risks of post-inflammatory hyperpigmentation (PIH), atrophic scarring, and, less commonly, keloid formation. Post-varicella scarring has been reported in up to 7–18% of patients and may persist into adulthood.[9] PIH is especially prevalent in individuals with darker skin phototypes, which are common in the Malaysian population.

Facial involvement, as demonstrated in the present case, carries significant psychosocial implications. Visible scarring and pigmentation may negatively impact self-esteem, social interactions, and overall quality of life, particularly in young adults.[10] Patient-reported outcome measures such as SCAR-Q may be used to assess the psychosocial burden associated with scarring. In this case, improvement in scar appearance and symptoms was accompanied by only modest psychosocial recovery, reflecting the recognised lag between physical and psychological adaptation.

Management of post-varicella aesthetic complications frequently requires multimodal therapy. For PIH, first-line treatment includes topical agents such as hydroquinone, retinoids, and azelaic acid, combined with strict photoprotection. Procedural options include chemical peels and pigment-targeting laser therapies such as Q-switched or picosecond lasers. For atrophic scars, treatment options include microneedling, fractional laser resurfacing, subcision, and chemical reconstruction of skin scars (CROSS technique using trichloroacetic acid). Combination therapy is often required to achieve satisfactory outcomes.[9,10]

In the Malaysian private healthcare setting, the estimated cost of managing post-varicella aesthetic complications can be substantial, often requiring multiple treatment sessions.
This case highlights an important gap in real-world clinical practice. Varicella is frequently perceived as a benign condition and managed symptomatically, particularly in primary care. However, adult varicella should not be underestimated. Delayed antiviral initiation may result in preventable complications, prolonged disease course, and significant aesthetic and psychosocial burden.

Accordingly, general practitioners and aesthetic physicians should adopt a proactive approach to the management of varicella. Early antiviral therapy should be strongly considered in adult patients, particularly those presenting within 72 hours of rash onset, with extensive disease or facial involvement. Timely intervention not only improves clinical outcomes but also plays a crucial role in preventing long-term aesthetic sequelae.

In conclusion, this case underscores the importance of early recognition and timely antiviral treatment in varicella infection. Early intervention may significantly minimise complications and long-term aesthetic burden, thereby improving both clinical and psychosocial outcomes.

REFERENCES

1. Gershon AA, Breuer J, Cohen JI, Cohrs RJ, Gershon MD, Gilden D, et al. Varicella zoster virus infection. Nat Rev Dis Primers 2015; 1: 15016.
2. Gnann JW Jr. Antiviral therapy of varicella-zoster virus infections. In: Arvin A, Campadelli-Fiume G, Mocarski E, Moore PS, Roizman B, Whitley R, Yamanishi K, editors. Human herpesviruses: biology, therapy, and immunoprophylaxis. Cambridge: Cambridge University Press; 2007.
3. Wallace MR, Bowler WA, Murray NB, Brodine SK, Oldfield EC Jr. Treatment of adult varicella with oral acyclovir. Ann Intern Med. 1992; 117(5): 358-63.
4. Balfour HH Jr. Antiviral drugs. N Engl J Med. 1999; 340(16): 1255-68.
5. Lin L, Zhang R. A case of generalised varicella in an adult. Clin Cosmet Investig Dermatol. 2025; 18: 2167-72.
6. Centers for Disease Control and Prevention (CDC). Varicella. In: Epidemiology and prevention of vaccine-preventable diseases. 14th ed. Atlanta: CDC; 2021 [cited 2026 Apr 22]. Available from: https://www.cdc.gov/pinkbook/hcp/table-of-contents/chapter-22-varicella.html
7. Schots JPM, Moons P, Stoot JHMB. Management of varicella gangrenosa: a life-threatening condition from chickenpox. Case Rep Med. 2014; 2014: 206152.
8. Lee SC, Ng MCE, Tan CL, Lim YAL, Rahman NA, Abdullah A, et al. Vision loss in an immunocompetent child post varicella infection: a case report. Malays Fam Physician 2020; 15(1): 54-7.
9. Pour Mohammad A, Ghassemi M. Varicella-zoster scar treatments: a tertiary review. Med J Islam Repub Iran 2021; 35: 136.
10. Agarwal N, Mittal A, Kuldeep CM, Singh A, Gupta LK, Khare AK, et al. Chemical reconstruction of skin scars therapy using trichloroacetic acid in post varicella scars. J Cutan Aesthet Surg 2013; 6(3): 144-8.

Mosaic turner syndrome (45,X/46,XY) presenting as delayed puberty and ambiguous genitalia in an adolescent

Elise Wen Yun Yap[1], Su Fen Chia[1,2], Albert Chao Chiet Tan[1]

[1]Department of Obstetrics and Gynecology, Hospital Tengku Ampuan Rahimah, Ministry of Health, Selangor, Malaysia, [2]Institute for Health Systems Research, National Institutes of Health, Ministry of Health Malaysia

SUMMARY

Mosaic Turner Syndrome (45,X/46,XY) is a rare chromosomal condition that may present with varying clinical features. When classical dysmorphic features are absent, the condition may escape early recognition, as prenatal genetic screening is generally not indicated without specific antenatal findings. We describe a 13-year-old girl, raised as female, who presented with delayed puberty and ambiguous genitalia. Despite clitoromegaly noted at birth, the finding was overlooked until adolescence. Hormonal evaluation revealed hypergonadotropic hypogonadism, and karyotyping confirmed mosaic 45,X/46,XY. The absence of classical phenotypic features, along with caregiving challenges and limited follow-up during early childhood, may have contributed to delayed diagnosis. Multidisciplinary evaluation prompted timely surgical intervention, with gonadectomy confirming gonadoblastoma and highlighting the associated malignancy risk. Nevertheless, the mother's ongoing emotional support and open communication, contributed to the child's psychological well-being development and stable gender identity. In addition, this case highlights missed early clinical signs, gaps in early assessment, and positive psychosocial adaptation despite delayed diagnosis. It emphasises the importance of enhancing provider training and public awareness of meticulous pubertal assessment, early genital evaluation, and integration of psychosocial context into clinical care, particularly in families facing socioeconomic and caregiving burdens.

INTRODUCTION

Turner Syndrome (TS) is a chromosomal condition typically characterised by a 45,X karyotype, often presenting in early childhood with features like short stature and lymphoedema. However, mosaic variants such as 45,X/46,XY exist. This rare chromosomal pattern poses significant diagnostic challenges owing to its broad and often subtle phenotypic spectrum, which may range from a typical female presentation to ambiguous genitalia, or even a phenotypic male.[1]

Unlike classic Turner syndrome, which is often diagnosed in early life, mosaic forms may be substantially more difficult to recognise. The phenotypic variability means that associated features — including genital atypia — may be subtle at birth and therefore overlooked or considered clinically insignificant.[1] Consequently, diagnosis may not be established until adolescence, when the patient presents with primary amenorrhoea or delayed puberty. Such delayed recognition carries significant implications, particularly in individuals with 45,X/46,XY mosaicism, given the elevated risk of gonadal malignancy associated with Y chromosome material, as well as the considerable psychosocial impact during this critical developmental period.[2,5]

Importantly, delayed diagnosis has implications that go beyond medical management. Adolescents diagnosed with disorders of sex development (DSDs) may experience psychosocial stress, gender uncertainty, and stigma in the absence of adequate support. Without timely diagnosis, they are often left without the opportunity for gradual psychosocial adaptation or access to multidisciplinary support.[3,11-12] Social, economic, and healthcare system factors may further compound diagnostic delays. This is particularly relevant in resource-limited settings where access to routine genetic testing is limited.

In this report, we describe a 13-year-old phenotypic female who presented with primary amenorrhoea and ambiguous genitalia is described and ambiguous genitalia and was subsequently diagnosed with mosaic Turner syndrome (45,X/46,XY). In resource-limited settings, early features of genital ambiguity may be overlooked, resulting in delayed access to genetic testing and specialist referral. This case underscores the complexities within the clinical care pathway, where delays in diagnosis despite early observable signs, may reflect gaps in clinical awareness, documentation, and continuity of follow-up.

These findings point to the value of enhancing medical education on disorders of sex development (DSDs), particularly in recognizing subtle genital differences and supporting timely adolescent surveillance. The early childhood period offers a key window for medical assessment as well as family-centred guidance on developmental, psychological, and ethical aspects.

CASE PRESENTATION

Case History

A 13-year-old girl of Malay ethnicity, assigned female at birth, was referred for evaluation of primary amenorrhoea and ambiguous genitalia. She was born full-term via vacuum-assisted delivery to a 27-year-old healthy mother, with non-consanguineous parents and no known family history of genetic disorders. Her early developmental milestones were within normal limits, and she had no prior surgical interventions or significant medical history.

This article was accepted: 09 June 2026
Corresponding Author: Su Fen Chia
Email: chiasufen@moh.gov.my

Although clitoromegaly resembling a penis was noted by the mother at birth, the finding was initially reassured by healthcare providers as normal and not investigated further. No indication for prenatal genetic screening existed, and no other dysmorphic features were noted at birth. The patient was primarily cared for by her grandmother during her early childhood.

Concerns were raised again at age 13 owing to failure to attain menarche and persistent genital abnormalities. She had no history of secondary virilization characteristics, such as deepening of the voice, or changes in hair distribution. Gender identity remained congruent with female sex assignment at birth.

Her family demonstrated strong emotional resilience and a thoughtful understanding when informed of the diagnosis. Both parents acknowledged and accepted the implications, including infertility and the potential need for gender-affirming support. Following her father's accident, which left him unable to work, her mother assumed the primary caregiving role within the family. Despite the challenges of raising five children and coping with financial strain, she remained a steadfast source of emotional support for her daughter. The child continues to thrive in school and daily activities, likely supported by this nurturing environment.

Family pedigree

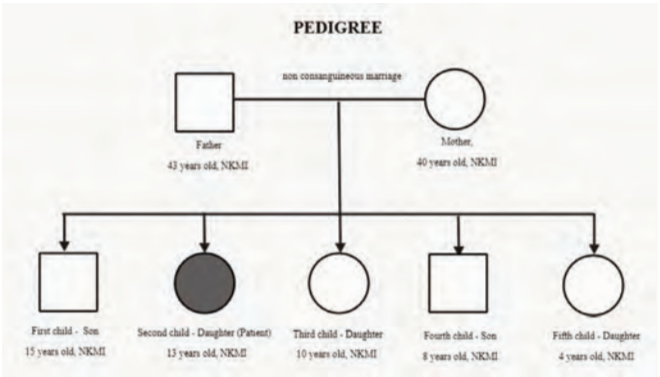

Physical Examination

Her height was 141.5 cm, weight 35 kg, with a BMI of 17.5 kg/m². Secondary sexual development was Tanner Stage II, with breast buds present but not enlarged and minimal pubic hair. Axillary and facial hair were absent. Examination of the external genitalia revealed clitoromegaly with a penile-like appearance, labial fusion, hyperpigmentation, a small vaginal orifice, and no palpable gonads or scrotum. No café-au-lait spots, webbed neck, cardiac murmur, or other stigmata of Turner syndrome were observed.

** Clinical photographs were not included as consent for publication of genital images was declined.*

Results of relevant tests or investigations:

- Hormonal profile:
  - FSH: 102.4 IU/L ↑
  - LH: 30.29 IU/L ↑
  - Progesterone: <0.67 nmol/L ↓
  - Testosterone: 7.20 nmol/L ↑ (male range)
  - 17-OHP: 2.46 nmol/L (normal)
- Pelvic MRI:
  - Anteverted atrophic uterus (2.7 x 1.7 x 2.8 cm), single endometrial cavity, preserved zonal anatomy
  - Non-visualisation of both ovaries
  - Perineal structure resembling penis (Clitoromegaly, with a phallic structure identified on axial view)
  - No urinary tract or other abdominal abnormalities (Normal bladder, kidneys, liver, spleen, vertebrae)
- Standard karyotyping using G-banding technique on peripheral blood:
  - 30 cells analyzed:
  - - 22 cells (73.3%): 46,XY
  - - 8 cells (26.7%): 45,X
  - Final karyotype: 45,X[8]/46,XY[22]
  - Interpretation → Mosaic Turner Syndrome

Diagnosis

- Mosaic Turner Syndrome (45,X/46,XY) with Disorder of Sex Development (DSD)
- Ambiguous genitalia and delayed puberty

Treatment Plan

She was subsequently referred to a tertiary centre for further management under a dedicated Paediatric Adolescent Gynaecology team. She remains under regular follow-up by a multidisciplinary team comprising paediatric adolescent gynaecology, paediatric surgery, and psychological services, guiding her long-term care. Management has focused on providing affirming, patient-centred care aligned with her expressed female gender identity and psychosocial development.

Following multidisciplinary discussion, a staged surgical approach was planned. Priority was given to examination under anaesthesia (EUA) with diagnostic laparoscopy and bilateral inguinal exploration with gonadectomy. The decision for gonadectomy was made through shared decision-making after detailed counselling, for risk reduction in view of the presence of Y-chromosome material and its associated malignancy risk, as well as to allow definitive evaluation of gonadal tissue.

She then underwent examination under anaesthesia (EUA) with diagnostic laparoscopy, bilateral inguinal exploration with gonadectomy. Histopathological examination revealed gonadoblastoma in the left gonad, while the right gonad demonstrated mixed gonadal elements without evidence of malignancy. A final diagnosis of mixed gonadal dysgenesis with gonadoblastoma was established on the basis of histopathological findings.

Following surgery, oral hormone replacement therapy (progynova 1mg once daily) with oral oestrogen (estradiol 1mg twice weekly) was initiated to support pubertal development and bone health, with plans for ongoing titration and future addition of progesterone as appropriate. Bone health surveillance, including planned bone mineral density assessment, and cardiovascular monitoring have been incorporated into her long-term follow-up plan.

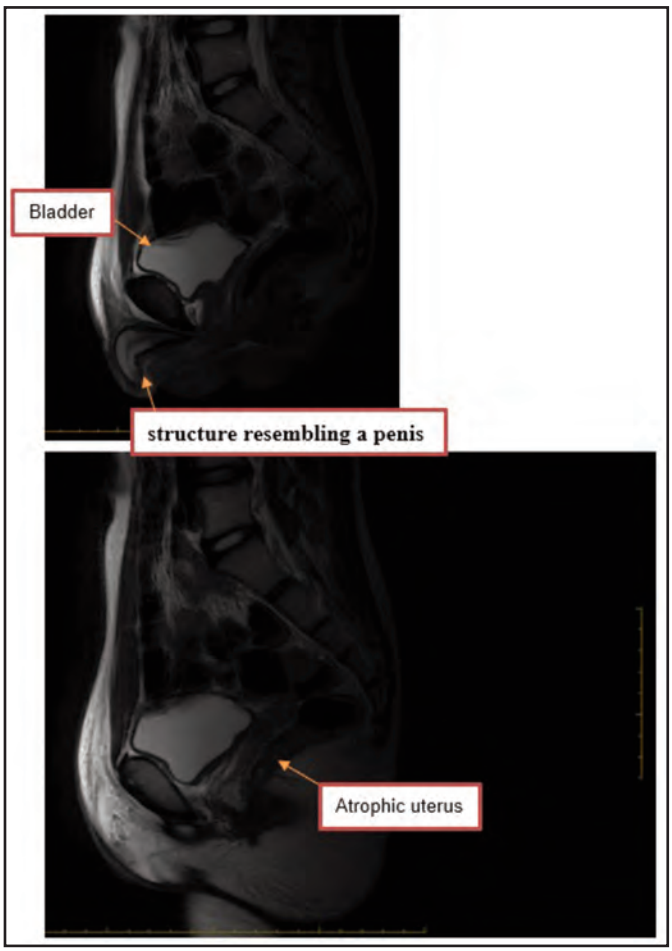

Fig. 1: Sagittal T2-weighted MRI: Shows the atrophic uterus (2.7 × 1.7 × 2.8 cm) with single endometrial cavity and preserved zonal anatomy

Surgical options for genital reconstruction, including reduction clitoroplasty and possible vaginoplasty, are being considered in a staged manner based on patient readiness and shared decision-making. Psychological support, including individual counselling and peer-based interventions, is being provided to facilitate emotional adjustment and strengthen resilience during adolescence and transition.

DISCUSSION

The absence of typical Turner syndrome features in this patient delayed recognition until primary amenorrhoea became apparent. Early genital ambiguity in the form of clitoromegaly was noted at birth but not further investigated, reflecting missed early clinical signs and gaps in initial assessment and follow-up. This case underscores the wide clinical variability associated with rare mosaic Turner syndrome and the diagnostic delays that arise when classical features are absent.[4]

The presence of Y-chromosome material in mosaic Turner syndrome confers an increased risk of gonadoblastoma or germ cell neoplasia in situ, reported in approximately 12–40% of patients.[5] In this case, the patient presented in early adolescence with delayed diagnosis and was subsequently found to have gonadoblastoma on histopathological examination following gonadectomy, highlighting the clinical relevance of this risk. Malignant transformation has most commonly been described during adolescence and early adulthood (approximately 13–24 years), although cases in younger children have also been reported. This supports consideration of early prophylactic gonadectomy, often at the time of diagnosis.[1,6] However, the optimal timing of gonadectomy should be individualized. In this case, early surgical intervention was undertaken based on the known malignancy risk associated with Y-chromosome material. Even in the absence of definitive imaging findings, surgical intervention may be warranted, given that imaging may fail to detect early neoplastic change in dysgenetic or intra-abdominal gonads.[7] Referral to a centre with expertise in the care of individuals with TS and Y chromosome material, along with a shared decision-making approach, is recommended, as demonstrated in this case.[8]

Hormonal analysis in this case revealed hypergonadotropic hypogonadism and elevated testosterone, consistent with primary gonadal failure with possible testicular tissue. Imaging confirmed an atrophic uterus and non-visualized ovaries, further supporting the diagnosis of mixed gonadal dysgenesis. Consistent with prior case descriptions, our patient's findings resemble those of a 22-year-old female with

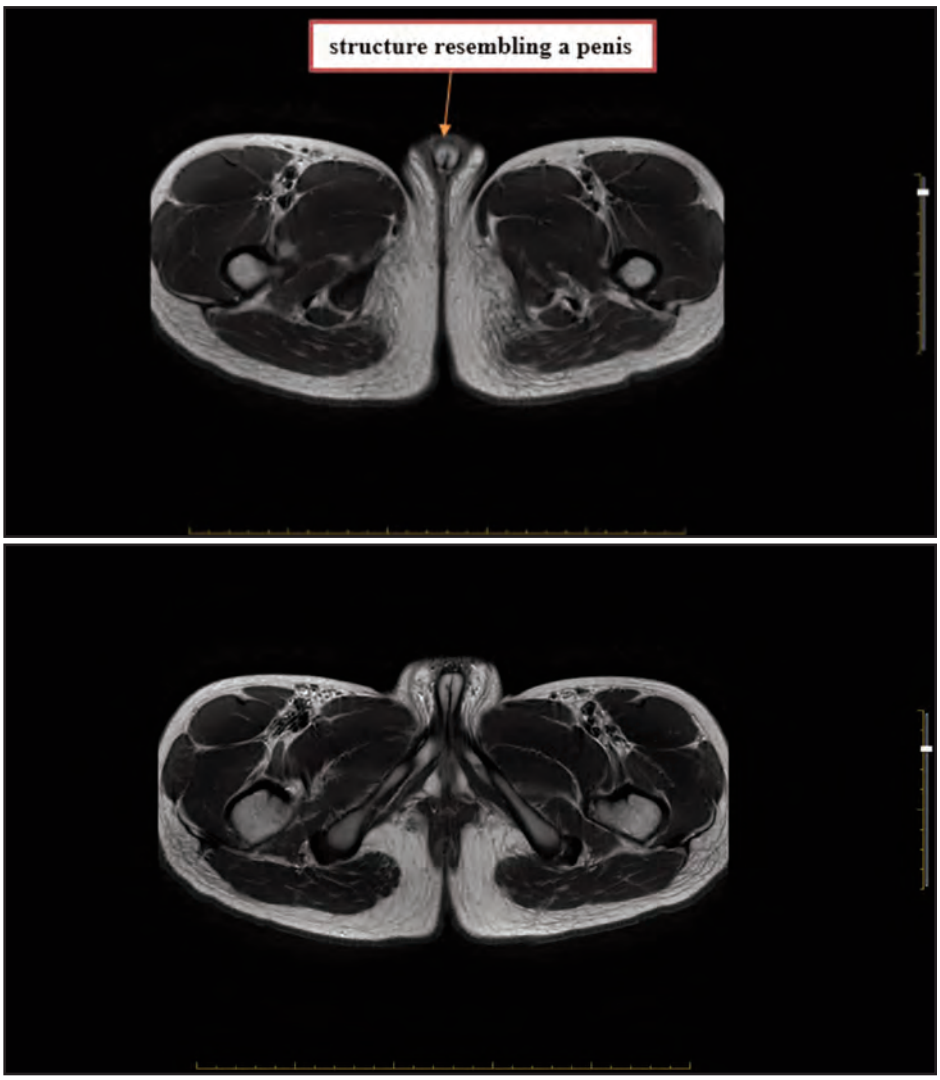

Fig. 2: Axial T2-weighted MRI: Demonstrates a structure resembling a penis and non-visualisation of both ovaries

45,X/46,XY mosaicism who presented with primary amenorrhea and demonstrated absent uterus and ovaries on imaging before prophylactic gonadectomy.[8]

In patients with hypergonadotropic hypogonadism, as in this case, hormone replacement therapy is recommended until the average age of natural menopause, initially to induce puberty and subsequently to maintain secondary sexual characteristics, optimise uterine development and support attainment of peak bone mass.[1] Hence, oestrogen therapy was initiated in our patient, with ongoing follow-up to optimise hormone replacement therapy, including the timing of progesterone addition for endometrial protection. In addition, baseline and periodic cardiac assessment is recommended to screen for structural cardiac anomalies, alongside bone health optimisation.[1]

Beyond medical implications, adolescents diagnosed with DSD often experience challenges related to identity, autonomy, and future reproductive potential.[10] These concerns are best addressed through multidisciplinary care — encompassing medical, surgical, psychosocial, and psychosexual support, alongside ethical and human rights considerations, and delivered via individualised counselling and shared decision-making in a developmentally appropriate manner.[11-12] Satisfaction with healthcare communication has been associated with improved psychosocial outcomes in adolescents with DSD.[13] The child continues to function well in school and daily activities, suggesting positive psychosocial adaptation. This highlights the protective role of supportive caregiving in adolescents with DSD, particularly in the context of delayed diagnosis and complex care needs.

Mosaic TS with 45,X/46,XY karyotype can present with subtle or ambiguous features that may not be recognised at birth. This case highlights the importance of early genital assessment and timely genetic evaluation, as missed early signs and gaps in follow-up may lead to delayed diagnosis. In addition, caregiving strain and social factors may further contribute to delays in diagnosis. Multidisciplinary involvement encompassing medical, surgical, psychological, and social support, plays a key role in addressing the needs of both patient and family.

REFERENCES

1. Gravholt CH, Andersen NH, Christin-Maitre S, Davis SM, Duijnhouwer A, Gawlik A, et al. Clinical practice guidelines for the care of girls and women with Turner syndrome. Eur J Endocrinol 2024; 190(6): G53-g151.
2. Reimann GE, Bernad Perman MM, Ho PS, Parks RA, Comis LE. Psychosocial Characteristics of Women with a Delayed Diagnosis of Turner Syndrome. J Pediatr 2018; 199: 206-11.
3. Cools M, Nordenström A, Robeva R, Hall J, Westerveld P, Flück C, et al. Caring for individuals with a difference of sex development (DSD): a Consensus Statement. Nat Rev Endocrinol 2018; 14(7): 415-29.
4. Alkhunaizi E, Albrecht JP, Aarabi M, Witchel SF, Wherrett D, Babul-Hirji R, et al. 45,X/46,XY mosaicism: Clinical manifestations and long term follow-up. Am J Med Genet A 2024; 194(3): e63451.
5. Pyle LC, Nathanson KL. A practical guide for evaluating gonadal germ cell tumour predisposition in differences of sex development. American Journal of Medical Genetics Part C: Seminars in Medical Genetics 2017; 175(2): 304-14.
6. Mittal S, Weaver J, Aghababian A, Edwins R, Godlewski K, Fischer K, et al. Deferring gonadectomy in patients with turner syndrome with a genetic Y component is not a safe practice. J Pediatr Urol 2023; 19(3): 294.e1-.e5.
7. Ebert KM, Hewitt GD, Indyk JA, McCracken KA, Nahata L, Jayanthi VR. Normal pelvic ultrasound or MRI does not rule out neoplasm in patients with gonadal dysgenesis and Y chromosome material. Journal of Paediatric Urology 2018; 14(2): 154.e1-.e6.
8. Dowlut-McElroy T, Shankar RK. The Care of Adolescents and Young Adults with Turner Syndrome: A Paediatric and Adolescent Gynecology Perspective. J Pediatr Adolesc Gynecol 2022; 35(4): 429-34.
9. Alhajjaj A, Altarouti SA, Alkhabbaz F. Mosaic Turner Syndrome With 45,X/46,XY Mosaicism and Apparent Absent Uterus. Cureus 2021; 13(5): e14816.
10. Ernst MM, Liao LM, Baratz AB, Sandberg DE. Disorders of Sex Development/Intersex: Gaps in Psychosocial Care for Children. Paediatrics 2018; 142(2).
11. Wisniewski AB, Batista RL, Costa EMF, Finlayson C, Sircili MHP, Dénes FT, et al. Management of 46,XY Differences/Disorders of Sex Development (DSD) Throughout Life. Endocr Rev 2019; 40(6): 1547-72.
12. Vora KA, Srinivasan S. A guide to differences/disorders of sex development/intersex in children and adolescents. Aust J Gen Pract 2020; 49(7): 417-22.
13. Liles SM, Crerand CE, Buchanan C, Chan YM, Chen D, Hansen-Moore J, et al. Healthcare communication satisfaction and psychosocial outcomes in adolescents and young adults with differences of sex development. Patient Educ Couns 2024; 125: 108294.

CASE REPORT

Unravelling invasive fungus: A case report of rhino-orbital mucormycosis in a patient with diabetic ketoacidosis

Muhammad Syazani I[1,2], Nazrina H[1,3], Lizawati RH[4], Julieana M[2]

[1]Department of Ophthalmology Hospital Tuanku Ja'afar Seremban, [2]Department of Ophthalmology and Visual Science, School of Medical Sciences, Health Campus Universiti Sains Malaysia, [3]Department of Ophthalmology, Faculty of Medicine and Health Science, Universiti Malaysia Sabah, [4]Department of Pathology Hospital Tuanku Ja'afar Seremban

SUMMARY

Rhino-orbital mucormycosis is a rare but life-threatening invasive fungal infection, commonly associated with poorly controlled diabetes mellitus, particularly diabetic ketoacidosis. A case of a 52-year-old woman is reported with poorly controlled type 2 diabetes who presented with bilateral periorbital swelling and chemosis, progressing to right panophthalmitis. Computed tomography demonstrated bilateral sinusitis with orbital involvement, while fungal culture and histopathology confirmed angioinvasive mucormycosis. The patient was treated with systemic liposomal amphotericin B, local and retrobulbar amphotericin B, right eye evisceration, bilateral functional endoscopic sinus surgery, and repeated surgical debridement. Radical exenteration and maxillectomy were considered during multidisciplinary discussion. However, the family declined further extensive surgery due to concerns regarding morbidity and facial disfigurement. MRI was not feasible because the patient was critically ill with prolonged intubation and difficult intravenous access. Therefore, serial CT imaging was used to monitor disease progression and treatment response. Despite the inability to achieve complete radical surgical clearance, the patient showed favourable recovery with preservation of left eye vision following aggressive multimodal therapy. This case highlights the importance of prompt antifungal therapy, multidisciplinary management, and the potential role of globe-sparing approaches in selected patients.

INTRODUCTION

Mucormycosis is a highly invasive and potentially fatal infection caused by Mucorales fungi, for example Rhizopus sp. and Mucor sp.[1] and commonly presented as rhino-orbital mucormycosis.[1] It carries a very high mortality rate, ranging from 50–100%.[1] Initial symptoms and signs can be non-specific and may delay diagnosis, leading to devastating consequences. Major risk factors include poorly controlled diabetes mellitus (particularly in the context of diabetic ketoacidosis), haematological malignancies, immunodeficiency, and use of immunosuppressive agents.[2] Orbital symptoms include chemosis, ophthalmoplegia, proptosis, drop in vision as a result of orbital involvement from paranasal sinus.[2,3]

CASE PRESENTATION

A 52-year-old woman with poorly controlled type 2 diabetes mellitus (HbA1c 17.6% at admission) presented with a 2-day history of bilateral periorbital swelling and chemosis, progressing to right eye panophthalmitis. Fever and cough preceded the onset of periorbital swelling. Computed tomography of the brain and orbit showed mucosal thickening with rim enhancing lesion in the bilateral maxillary sinuses, with collections extending to the bilateral infraorbital foramen, bilateral thickened rectus muscles, irregular right globe with thickened optic nerve.

The patient was co-managed with the otorhinolaryngology team; rhinoscopy demonstrated crusted, unhealthy mucosa and eschar in both nasal cavities. Fungal culture and sensitivity of the sample demonstrated hyphae consistent with Mucor. She was then treated with intravenous amphotericin B 45mg OD for 3 days and then changed to liposomal amphotericin B 225mg OD for a total duration of 1 month, as per the infectious disease team. The patient subsequently underwent right eye evisceration and bilateral functional endoscopic sinus surgery (FESS) for extensive fungal infection involving the sinuses with extension into the right orbit.Post-operative histopathology confirmed angioinvasive fungal sinusitis. Postoperatively, daily debridement and desloughing were performed owing to persistent purulent discharge and slough tissue at the eviscerated socket. As she showed no signs of improvement, she underwent bilateral orbit exploration and removal of eschar tissue.

Following a multidisciplinary team meeting involving oculoplastics, otorhinolaryngology, and the infectious disease team, bilateral maxillectomy and exenteration were planned to achieve total eradication of mucormycosis. However, the family members opted for palliative management owing to concerns regarding high mortality risk and facial disfigurement. The patient was then discharged from the ward after completing intravenous amphotericin B. The patient was reviewed in clinic every two weeks, with gradual improvement in general condition.

At the third month post-discharge review, the right orbit demonstrated healthy granulation tissue with no pus or slough. No evidence of mucormycosis extension into the left eye was identified, with preserved visual acuity of 6/9 on the Snellen chart.

This article was accepted: 09 June 2026
Corresponding Author: Muhammad Syazani Ibrahim
Email: syazani101@gmail.com

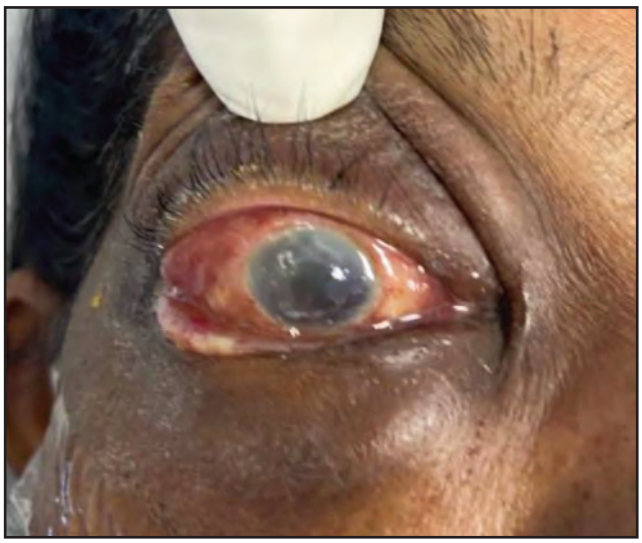

Fig. 1: Clinical photograph demonstrating right eye complete ophthalmoplegia with marked chemosis and corneal melting. B-scan ultrasonography revealed scleral thickening with vitreous opacities



Fig. 2: Computed tomography brain and orbit showed an irregular right eye globe with enhancement, swollen recti muscles, and a thickened optic nerve with intraconal fat streakiness left extraconal collection extended into intraconal region



Fig. 3: Patient condition after 3 months post discharge from ward with development healthy granulation tissue and no remnant of necrotic tissues of orbit

DISCUSSION

Diabetic ketoacidosis precipitates the progression of fungal sinusitis in poorly controlled diabetes mellitus, leading to rhino-orbital mucormycosis — diabetes mellitus being the most common predisposing factor.[3] An improved prognosis can be achieved through early diagnosis and prompt initiation of treatment.

Orbital symptoms include ophthalmoplegia (approximately 67%), visual impairment (65%), proptosis (64%), periorbital oedema (43%), and periorbital pain. In this case, arriving at a correct diagnosis presented a challenge, as the only symptoms that could be elicited during the first encouter patient was bilateral periorbital oedema, given that the patient was intubated and sedated for diabetic ketoacidosis.[3]

A significant difference in survival rates exists depending on the timing of treatment initiation. Initiating therapy within 6 days can lead to survival rates of 76-81%.[4] Conversely, delays of more than 12 days may drastically reduce survival rates to 36–42%.[4] In this case, initiation of treatment was delayed in view of delay in arriving at the diagnosis and difficulty in intravenous access that eventually required insertion of peripheral inserted central catheter.

Amphotericin B improves the survival rate by up to 60% in mucormycosis patients, and it has been the gold standard treatment since then.[5] In this case, liposomal amphotericin B was chosen because it has better blood-brain barrier penetration and a safer renal profile.[5-6]

Liposomal amphotericin B was selected for its superior tissue penetration and more favourable renal risk profile compared with conventional amphotericin B. Amphotericin B is a rapid fungicidal treatment, especially in the acute phase of illness.[7] Alternative agents such as posaconazole and isavuconazole are generally reserved as salvage therapy or for patients who are intolerant of amphotericin B.[8]

Clear-margin resection of all infected tissue reduced mortality by up to 49%.[7] and increased it up to 71%[9] with combination of liposomal amphotericin B. Mucormycosis causes angio-invasion, thus leading to vascular obstruction and inadequate penetration of systemic antifungal therapy. To enhance tissue penetration, local irrigation with amphotericin B was performed.[7] The patient underwent several operative procedures to remove infected and necrotic tissues but was unable to achieve adequate removal in view of patient refused exenteration of left eye radical clear margin resection of the face. Local irrigation and retrobulbar with amphotericin B were also performed during dressing of the wound.

Evisceration was chosen because infection was confined to right globe, and no definitive evidence of extensive orbital tissue involvement or intracranial involvement, with good visual acuity in the left eye. Despite MRI providing better delineation of soft tissue involvement, the lesion extent, the patient was critically ill with difficult intravenous access and prolonged intubation, limiting the feasibility of MRI. CT imaging provides more rapid assessment, facilitates earlier medical and surgical intervention. It more feasible to be performed to monitor the progression and treatment response.

Despite not undergoing exenteration, the patient survived the infection, attributable to the combination of systemic and local amphotericin B together with multiple surgical debridements of necrotic tissue. This suggests that, in carefully selected cases, aggressive multimodal therapy without exenteration may achieve infection control whilst potentially preserving a better quality of life.

Given significant morbidity associated with repeated surgical debridement, other successful treatment approaches include hyperbaric oxygen therapy in combination with systemic and local amphotericin B including retrobulbar amphotericin B administration.[10]

Rhino-orbital mucormycosis may present with subtle and non-specific findings, which can lead to diagnostic delay. A high index of suspicion for fungal infection should be maintained in patients presenting with diabetic ketoacidosis and chemosis. Primary infection of orbital mucormycosis may be detected by early, thorough nasal endoscopy with suspicious eye symptoms and signs. A favourable outcome is achievable with early diagnosis, intravenous antifungal therapy, and clear resection margins. Rhino-orbital mucormycosis is a life-threatening orbital infection; the possibility of exenteration should be considered to prevent intracranial spread. Continuous multidisciplinary team co-management and in-depth counselling of family members regarding the high mortality rate are essential in the management of this condition.

REFERENCES

1. Katragkou A, Walsh TJ, Roilides E. Why is mucormycosis more difficult to cure than more common mycoses? Clin Microbiol Infect 2014; 20 Suppl 6: 74-81.
2. Roden MM, Zaoutis TE, Buchanan WL, et al. Epidemiology and outcome of zygomycosis: A review of 929 reported cases. Clin Infect Dis 2005; 41(5): 634-53.
3. Yohai RA, Bullock, JD, Aziz AA, & Markert RJ. Survival factors in rhino-orbital-cerebral mucormycosis. Surv Ophthalmol. 1994; 39(1): 3-22.
4. Pillsbury HC, Fischer ND. Rhinocerebral mucormycosis. Arch Otolaryngol 1977; 103(10): 600-4.
5. Petrikkos GL. Lipid formulations of amphotericin B as first-line treatment of zygomycosis. Clin Microbiol and Infect 2009; 15 Suppl 5: 87-92.
6. Aguirre, J. P. B., & Hamid, A. M. R. Amphotericin B deoxycholate versus liposomal amphotericin B: effects on kidney function. Cochrane Database of Syst Rev 2015; (11): CD010481.
7. Tedder M, Spratt JA, Anstadt MP, Hegde SS, Tedder SD, Lowe JE. Pulmonary mucormycosis: results of medical and surgical therapy. Ann Thorac Surg. 1994; 57(4): 1044-50.
8. Rothe K, Braitsch K, Okrojek R, Heim M, Rasche S, Verbeek M, et al. Clinical and microbiological features and outcomes of mucormycosis in critically ill patients. Int J Infect Dis 2021; 109: 142-7.
9. Seiff, S. R., Choo, P. H., & Carter, S. R. Role of local amphotericin B therapy for sino-orbital fungal infections. Ophthal Plast & Reconstr Surg 1999; 15(1): 28-31.
10. Valencia-Caballero V, Cachay-Diaz J, Huamán-Muñante J, Romaní-Montoro L, Vásquez-Zevallos N, Carozzi-Calvo C, et al. Hyperbaric oxygen therapy as an adjunctive treatment for COVID-19-associated mucormycosis: a report of two cases. Rev Peru Med Exp Salud Publica 2023; 40(1): 98-103.

Severe junctional epidermolysis bullosa in a rural infant: Challenges of diagnosis and management in primary care

Flecia Kundayis, Dr.Fam.Med (Fam Med), Erna Sazrina Binti Sahirin, MBBS

Klinik Kesihatan Lohan, Ranau, Sabah, Malaysia

SUMMARY

Epidermolysis Bullosa (EB) is a rare inherited bullous disorder that results in skin fragility and blister formation following minimal trauma. Infants with severe forms of EB are at high risk of developing recurrent infections, nutritional compromise, metabolic derangements, and life-threatening complications. Optimal management requires multidisciplinary support, specialised wound care, and access to dermatology expertise resources that may not be readily available in rural healthcare settings. We describe the case of an infant from rural Sabah who developed extensive blistering shortly after birth and subsequently experienced repeated infections, failure to thrive, electrolyte imbalance, and bronchiolitis complicated by sepsis. Despite ongoing care in the primary setting with consultation from dermatology paediatric specialists, the patient's condition deteriorated and succumbed to death at approximately two months of age. This report highlights the complexity of diagnosing and managing severe EB in a resource-limited environment and emphasises the necessity for improved referral pathways, caregiver education, and system-level support for infants with rare dermatological disorders.

INTRODUCTION

Epidermolysis Bullosa represents a group of inherited blistering disorders characterized by structural defects within the skin that lead to mechanical fragility. The condition is broadly classified into EB simplex, junctional EB, dystrophic EB, and Kindler syndrome, each defined according to the level of dermo-epidermal separation and mutations in specific structural proteins such as keratins, laminins, type VII collagen, and integrins.[1] Severe subtypes, particularly junctional EB and recessive dystrophic EB, often present in the neonatal period with widespread erosions, denuded skin, mucosal involvement, nail deformities, and chronic wounds, and are associated with high mortality.[1] The disease is associated with recurrent infections, malnutrition, growth failure, and multisystem complications.[2] Effective management requires coordinated input from dermatologists, paediatricians, dietitians, wound care nurses, and genetic counsellors. Accessing multidisciplinary care can be difficult in low-resource settings. In Malaysia, cases of EB have been reported sporadically, but the true incidence remains unknown because of diagnostic limitations and the absence of a national EB registry. Rural communities face geographical, specialist-access, and socioeconomic barriers that hinder diagnosis and management. This case illustrates the natural progression of suspected severe junctional EB in an infant from a rural community, emphasizing the clinical, logistic, and systemic challenges encountered in primary care management.

CASE PRESENTATION

The patient was a 2-month-old infant born to a young couple living in a remote rural village in Ranau, Sabah, Malaysia. Both parents were Malaysian with no formal education and were distantly related, raising the possibility of consanguinity between them. The mother had an uncomplicated pregnancy and attended regular antenatal checkups. No abnormalities were detected on routine antenatal ultrasound, and maternal screening tests, including infectious screening and a 75 g oral glucose tolerance test, were normal. The infant was delivered at term through spontaneous vaginal delivery without immediate postnatal complications.

The infant's skin appeared fragile shortly after birth, with spontaneous blistering of the limbs and pressure points observed on day 16 of life. The parents reported that even gentle handling or repositioning resulted in the formation of new bullae and erosions. Over the next few weeks, the lesions became more extensive and involved the elbows, buttocks, hands, and feet. Many of these areas developed erythema, crusting, and delayed healing. Several fingernails and toenails were dystrophic. The infant exhibited irritability and difficulty feeding, resulting in inadequate weight gain.

The family sought care at Klinik Kesihatan Lohan on Day 16 of life, where the child was assessed. The clinical presentation raised a strong suspicion of severe EB, likely junctional or recessive dystrophic type. Due to the rural setting, diagnostic tools such as skin biopsy and genetic testing were unavailable. The patient was subsequently referred to a pediatric dermatology specialist, and a skin biopsy confirmed the diagnosis of junctional epidermolysis bullosa.

Wound care consisted of daily dressings performed at the clinic using white, soft paraffin and non-adhesive gauze. Parents were educated on gentle handling techniques and instructed to avoid adhesive materials that could aggravate the skin. Consistent home wound care was challenging owing to the family's socioeconomic limitations. Pharmacological management included oral cephalexin for secondary bacterial infection of extensive skin erosions, oral nystatin for oral candidiasis contributing to feeding difficulties, and oral itraconazole for suspected fungal superinfection of chronic skin lesions following specialist consultation. Paracetamol

This article was accepted: 09 June 2026
Corresponding Author: Flecia Kundayis
Email: fleciakundayis@gmail.com



Fig. 1: Extensive tense and flaccid bullae over the earlobe, upper limbs, and trunk on Day 16 of life, consistent with severe bullous disease



Fig. 2: Multiple erosions, crusted plaques, and healing ulcerations over pressure points at approximately 2 months of age, demonstrating chronic fragility of the skin in severe epidermolysis bullosa

was administered for pain control during routine wound care and dressing changes, and multivitamin supplementation was provided to support nutritional status and wound healing. Despite these interventions, the infant's condition remained fragile, and growth was suboptimal during subsequent follow-up visits.

At approximately two months of age, the infant developed cough, rapid breathing, lethargy, and poor feeding. On examination, he appeared tachypnoeic and had transmitted chest sounds suggestive of acute bronchiolitis. The patient was referred to the nearest district hospital. Investigations revealed severe biochemical derangements, including hyponatremia (serum sodium 126 mmol/L), renal impairment (creatinine 126 µmol/L), and transaminitis (ALT 65.2 U/L, AST 358 U/L). There was marked leukocytosis (total white cell count 25 $\times 10^9$/L) and hyperkalemia, with a potassium level of 10.2 mmol/L, alongside a significantly elevated C-reactive protein level of 196 mg/L. Serum albumin was reduced to 37 g/L, reflecting poor nutritional status and ongoing protein loss from chronic wounds. Venous blood gas analysis revealed profound metabolic acidosis, with a pH of

6.51 and bicarbonate level of 4.5 mmol/L. These findings indicate systemic infection, dehydration, and multi-organ dysfunction. Despite intensive medical management and resuscitative efforts, the infant's condition deteriorated rapidly, progressing to septic shock, severe metabolic acidosis, electrolyte derangements, and multi-organ dysfunction. He subsequently developed cardiac arrest and could not be resuscitated.

During subsequent follow-up, the mother was emotionally well and able to accept the loss with good family support. Screening for depression and anxiety using the Whooley questions and the Generalized Anxiety Disorder (GAD) screening tool was unremarkable. Genetic testing was discussed but declined because of financial constraints. She is currently not keen to conceive and has opted for intramuscular Depo-Provera for contraception. She was advised on early antenatal booking and offered a referral to a dermatology clinic for prenatal assessment should she become pregnant in the future.

DISCUSSION

This case represents a typical presentation of severe junctional epidermolysis bullosa (EB) manifesting in the neonatal period.[1,3] The early onset of blistering, widespread erosions, dystrophic nails, poor wound healing, and feeding difficulties are characteristic of severe junctional EB, which is associated with high morbidity and mortality.[1,2] In the absence of confirmatory genetic testing at the rural clinic, the diagnosis was made clinically, consistent with guidelines that recognize the value of clinical phenotyping in resource-limited settings.[1,3]

EB results from defects in proteins responsible for dermal-epidermal adhesion, leading to skin fragility and blister formation following minimal trauma. Severe subtypes are frequently associated with oral involvement, growth failure, and nutritional compromise.[2,5] The infant in this case demonstrated impaired feeding and failure to thrive, which likely contributed to the significant reduction in total protein levels.[5]

Recurrent infections are a major cause of morbidity and mortality in EB.[2] Chronic wounds act as portals of entry for microorganisms, particularly when access to wound care supplies is limited. Despite daily clinic-based wound care, the infant developed sepsis complicated by metabolic derangements and multi-organ failure. Bronchiolitis further increases infant vulnerability. Chronic inflammation, malnutrition, and fluid loss increase the risk of deterioration during acute illness.[2,5]

This case highlights the substantial challenges in managing severe junctional EB in a rural primary care setting. Access to pediatric dermatology services is limited by geographical barriers and the need for referral to distant tertiary centers. Advanced wound care products recommended for EB, such as silicone-coated mesh dressings and silver-impregnated dressings, were not readily available in the local healthcare setting. Furthermore, the family's socioeconomic limitations affected their ability to obtain specialized wound care supplies and maintain optimal wound care at home. Similar challenges have been reported in other resource-limited settings, where poverty and limited specialist services contribute to poorer outcomes.[2]

This case provides several important lessons for primary-care practitioners. Neonates presenting with extensive blistering should raise suspicion of inherited bullous disorders and warrant early referral for specialist assessment.[3] Infants with severe EB require close monitoring for infection, malnutrition, electrolyte imbalance, and poor growth, as these complications can rapidly become life-threatening.[3,5] Early multidisciplinary involvement, including dermatology, pediatrics, dietetics, nursing, and social support services, is essential to optimize outcomes.[3]

The challenges encountered in this case highlight the opportunities to improve the management of similar patients in rural communities. Early use of teledermatology may facilitate timely specialist input and reduce delays in diagnosis and treatment.[3] Standardized referral pathways for suspected EB could improve coordination between primary care facilities and tertiary centers. Access to appropriate wound care materials and structured caregiver training on dressing techniques, infection prevention, nutrition, and gentle handling may reduce complications and improve home-based care.[3] Medical social workers may help address financial barriers.

In addition to its medical complications, severe EB places a considerable psychosocial burden on caregivers.[4] Parents often experience emotional distress related to chronic wound care, frequent healthcare visits, uncertainty regarding prognosis, and the risk of life-threatening complications. In rural settings, these challenges may be compounded by financial hardship, transportation difficulties, and limited access to specialist support services. Following the infant's death, bereavement support, psychological assessment, and counselling regarding future reproductive options were important components of ongoing care. Given the possibility of parental consanguinity in this case, genetic counselling should also be considered to facilitate informed reproductive decision-making in future pregnancies.[4]

In conclusion, Epidermolysis Bullosa is a complex and debilitating condition that requires comprehensive multidisciplinary management. This case demonstrates the difficulties in diagnosing and managing severe EB in a rural Malaysian health clinic setting, where limited access to pediatric dermatology subspecialty care, socioeconomic constraints, and logistical challenges significantly hinder timely and optimal management. The rapid deterioration and fatal outcomes underscore the need for enhanced rural health resources, improved caregiver education, and strengthened referral systems to support early intervention and continuity of care for infants with EB.

REFERENCES

1. Fine J, Bruckner-Tuderman L, Eady R, Bauer E, Bauer J, Has C, Heagerty A, Hintner H, Hovnanian A, Jonkman M, Leigh I, Marinkovich M, Martinez A, McGrath J, Mellerio J, Moss C, Murrell D, Shimizu H, Uitto J, Woodley D, Zambruno G. Inherited epidermolysis bullosa: updated recommendations on diagnosis and classification. Journal of the American Academy of Dermatology 2014; 70(6): 1103-1126.
2. Bardhan A, Bruckner-Tuderman L, Chapple I, Fine J, Harper N, Has C, et al. Epidermolysis bullosa. Nature Reviews Disease Primers. 2020; 6(1): 78.
3. Saad R, Duipmans J, Yerlett N, Plevey K, McCuaig C, Woolfe W, et al. Neonatal epidermolysis bullosa: a clinical practice guideline. British Journal of Dermatology 2024; 190(5): 636-56.
4. Martin K, Geuens S, Asche J, Bodan R, Browne F, Downe A, et al. Psychosocial recommendations for the care of children and adults with epidermolysis bullosa and their family: evidence-based guidelines. Orphanet Journal of Rare Diseases 2019; 14(1): 133.
5. Dos Santos ML, Monteiro A, Nascimento A, Barbosa S, Delgado A, Zamberlan P. Nutritional Profile and Topic Management for Wound Healing in Children with Epidermolysis Bullosa: What Is the Evidence? A Systematic Review. Recent Progress in Nutrition. 2024; 4(3).

Management challenges of bilateral eye cytomegalovirus (CMV) retinitis in a patient with HIV and multidrug-resistant virological failure: A case report

Nur Azureen Mohd Ali[1,2], Julieana Muhammed[2], Farhana I[1], Nazrina H[1,3]

[1]Department of Ophthalmology Hospital Tuanku Ja'afar Seremban, Negeri Sembilan Malaysia, [2]Department of Ophthalmology and Visual Science, School of Medical Sciences, Health Campus, Universiti Sains Malaysia, Kubang Kerian, Kelantan, Malaysia, [3]Department of Ophthalmology Hospital Tuanku Ja'afar Seremban, Negeri Sembilan Malaysia

SUMMARY

Introduction: Cytomegalovirus (CMV) retinitis is a major cause of vision loss in patients with advanced Human Immunodeficiency Virus (HIV) infection, particularly those with virological failure. Case Presentation: We report a 29-year-old male, an ex-intravenous drug user, diagnosed with HIV in August 2023. He initiated antiretroviral therapy (ART) but developed progressive virological failure with a peak viral load of 1.53 million copies/mL and a declining CD4 T-lymphocyte count from 44 to 24 cells/μL. He was also diagnosed with disseminated tuberculosis and Mycobacterium avium complex (MAC) infection. Ophthalmic evaluation in February 2024 revealed right eye (RE) Zone 1 and left eye (LE) Zone 2 CMV retinitis with vitritis. Initial treatment with oral valganciclovir resulted in partial resolution. In September 2024, reactivation occurred, requiring intravenous and intravitreal (IVT) ganciclovir. In February 2025, he developed macula-off retinal detachment in the LE, which required surgical intervention. Discussion: CMV retinitis in immunocompromised individuals is challenging, particularly in the setting of ART resistance and limited antiviral access. Early antiviral IVT may prevent structural complications. Conclusion: Vigilant monitoring, prompt re-treatment, and multidisciplinary care are essential in preserving vision in complex CMV retinitis cases.

INTRODUCTION

Cytomegalovirus (CMV) retinitis is the most common opportunistic ocular infection in patients with advanced HIV infection and typically occurs in individuals with profound immunosuppression (CD4 <50 cells/μL).[1,3] Despite the advent of effective antiretroviral therapy (ART), CMV retinitis remains a significant cause of vision loss, especially in resource-limited settings or among individuals with poor ART adherence or resistance.[2-3] Prompt diagnosis and treatment are critical to prevent irreversible vision loss and ocular complications such as retinal detachment. We present a case of bilateral CMV retinitis in a patient with ART failure and multidrug-resistant Human Immunodeficiency Virus (HIV), complicated by reactivation and retinal detachment.

CASE PRESENTATION

A 29-year-old male, diagnosed with Human Immunodeficiency Virus (HIV) in August 2023, was referred to ophthalmology in February 2024 for evaluation of progressive visual symptoms. He was an ex-intravenous drug user and had been started on first-line antiretroviral therapy (ART) consisting of Tenofovir, Lamivudine, and Efavirenz in accordance with Malaysian guidelines. The treatment course was complicated by virological failure with rising HIV viral loads (875,290 copies/mL in January 2024, 284,403 copies/mL in April 2024, and 1.53 million copies/mL in July 2024), accompanied by progressive CD4 decline from 44 cells/μL in January 2024 to a nadir of 24 cells/μL in July 2024. Resistance testing revealed broad resistance to nucleoside reverse transcriptase inhibitors (NRTIs) and non-nucleoside reverse transcriptase inhibitors (NNRTIs), with the exception of zidovudine (AZT), prompting ART regimen modification in August 2024.[5] The ART regimen was subsequently switched to tenofovir/emtricitabine in combination with lopinavir/ritonavir (Kaletra).

He also had disseminated Mycobacterium tuberculosis (MTB) and Mycobacterium avium complex (MAC) infection. Anti-tuberculosis (anti-TB) therapy was initially commenced but temporarily withheld owing to drug-induced liver injury (DILI). Following stabilisation of liver function, anti-TB therapy was resumed with isoniazid, rifampicin, and ethambutol (HRE) in combination with ciprofloxacin. The regimen was subsequently modified to isoniazid, levofloxacin, and ethambutol (HLE) owing to significant drug–drug interactions between rifampicin and protease inhibitor-based ART (lopinavir/ritonavir). ART adherence prior to admission was suboptimal. Following resistance testing, ART optimisation was undertaken in coordination with the infectious disease team. Potential drug interactions, particularly with rifampicin-based anti-tuberculosis therapy, were carefully monitored. He was also on levetiracetam for seizure disorder.

On ophthalmic evaluation, his visual acuity was 6/9 right eye (RE) and 6/12 left eye (LE). Anterior segment examination demonstrated bilateral endothelial dusting and anterior chamber inflammation. Fundus examination revealed right eye (RE) peripapillary flame-shaped haemorrhages with exudates, granular retinitis, and vitritis involving zone 1. LE showed granular retinitis with vitritis in zone 2 (Figure 1). He was diagnosed with RE zone 1 and LE zone 2 CMV retinitis. The diagnosis of CMV retinitis was established clinically, based on characteristic confluent retinal haemorrhages and

This article was accepted: 11 April 2026
Corresponding Author: Julieana Binti Muhammed
Email: drjulieana@usm.my

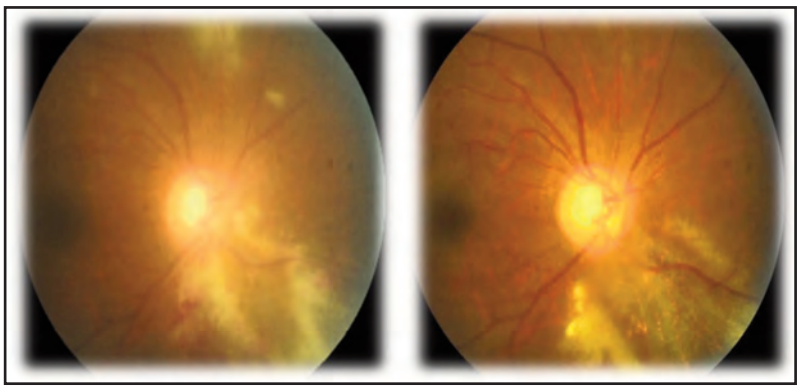

Fig. 1: Shows the fundus view at initial presentation with active CMV retinitis, characterised by granular retinal lesions * and vitritis (right), and fundus appearance two months after treatment initiation, showing resolving vitritis and retinitis (left)

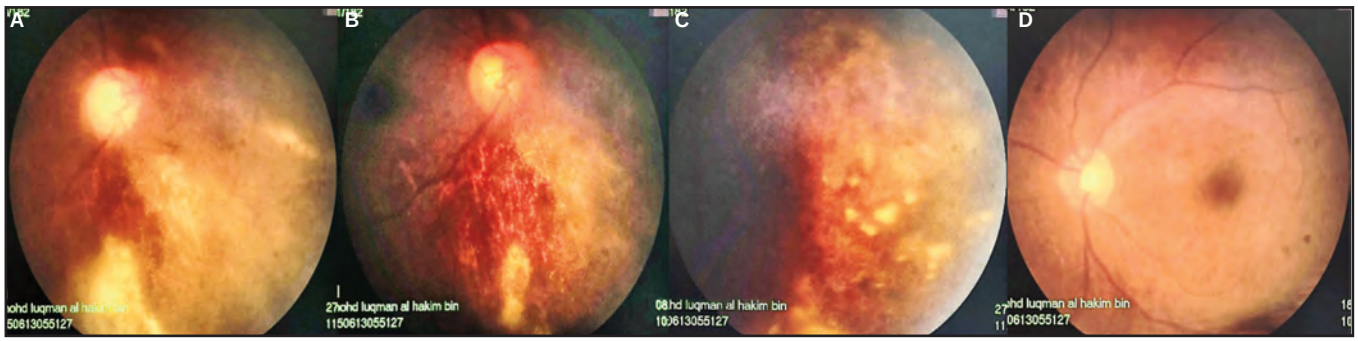

Fig. 2: (A, B) Shows the fundus view of the RE during reactivation of CMV retinitis characterised by inferior vitritis and wedge-shaped retinitis involving Zone 1(C) Shows the fundus view of the LE during reactivation of CMV retinitis characterised by dense vitritis*, retinitis, and fibrotic changes from 1–4 and 10–11 o'clock and (D) LE fundus post treatment 3 months

retinal whitening with granular borders in the setting of profound immunosuppression, with a nadir CD4 count of 44 cells/µL. Ocular fluid polymerase chain reaction (PCR) was not performed as the clinical features were classical. HIV retinopathy was considered less likely, as the lesions were progressive rather than limited to microvascular changes. There were no choroidal granulomas or occlusive vasculitis suggestive of ocular tuberculosis.

Topical corticosteroid (Gutt Maxitrol, both eyes [BE], four-hourly), cycloplegic (Gutt atropine 1%, BE, once daily), and anti-glaucoma medication (Gutt timolol 0.5%, BE, twice daily) were commenced to control anterior segment inflammation and secondary elevated intraocular pressure of 24 mmHg in both eyes. Systemically, oral valganciclovir 900 mg twice daily was administered for two weeks as induction therapy, followed by once-daily maintenance dosing for a further two weeks.

The patient was evaluated clinically for extraocular CMV involvement. There were no gastrointestinal, pulmonary, or neurological symptoms suggestive of systemic CMV disease. At the time of presentation, both intravenous (IV) and intravitreal (IVT) ganciclovir were unavailable at the treating centre owing to logistical and resource limitations. Given the absence of systemic CMV involvement and local drug availability constraints, induction therapy with oral valganciclovir was initiated. Oral valganciclovir is an accepted induction agent for CMV retinitis in the absence of systemic involvement, achieving systemic drug exposure comparable to intravenous administration. Vision improved to 6/9 bilaterally, with resolving retinitis after 2 months.

Seven months following his first presentation, the patient re-presented with bilateral floaters. Visual acuity remained 6/9 in BE. Slit-lamp examination demonstrated fine keratic precipitates and anterior vitreous cells bilaterally. Fundus exam showed reactivation features: the RE had inferior vitritis and wedge-shaped retinitis involving Zone 1 (Figure 2, A, B), while the LE showed dense vitritis, retinitis, and fibrotic changes from 1–4 and 10–11 o'clock (Figure 2, C). CD4 count dropped to 24 cells/µL, and HIV viral load remained high (1.53 million). He was treated with IV ganciclovir 300 mg BD and BE IVT ganciclovir injections (RE: 9 doses; LE: 5 doses). IVT ganciclovir (2 mg/0.05 mL) was administered weekly as induction therapy. The RE required a total of nine injections owing to slower resolution of zone 1 retinitis with persistent active borders, whereas the LE received five injections following earlier lesion inactivity and clinical improvement. Following IVT therapy, both eyes demonstrated a gradual reduction in retinal whitening and haemorrhages, with decreased vitritis. The retinitis borders eventually became inactive, with residual retinal scarring. A 21-day IV regimen was completed, followed by ongoing ophthalmic and infectious disease surveillance.

In February 2025, approximately five months later, the patient presented with progressive blurring of vision bilaterally, with visual acuity in the LE reduced to hand movements temporally. Anterior segment was unremarkable. Fundus examination of LE revealed inferior rhegmatogenous retinal detachment (RRD) from 4 to 8 o'clock with macula off. The patient underwent pars plana vitrectomy, endolaser photocoagulation, and silicone oil tamponade. Intraoperatively showed subtotal RRD with a retinal break at 8 o'clock and hyperpigmented scar at 2 o'clock. Postoperatively, the retina remained flat with silicone oil in situ, and visual acuity in the LE improved to counting fingers at 3 feet.

DISCUSSION

This case is noteworthy due to the presence of documented multidrug antiretroviral therapy (ART) resistance with virological failure, limited access to antiviral therapy, and the development of macula-off retinal detachment despite treatment. Although Cytomegalovirus (CMV) retinitis is a well-recognised opportunistic infection in advanced HIV, this case warrants reporting due to the presence of documented multidrug antiretroviral therapy (ART) resistance with virological failure, limited access to intravenous (IV) and intravitreal (IVT) antiviral therapy, and the development of macula-off retinal detachment despite treatment. These factors highlight contemporary management challenges in resource-limited settings.

CMV retinitis is most commonly observed in patients with CD4 counts below 50 cells/μL. The patient demonstrated poor viral suppression despite ART, likely secondary to antiretroviral resistance. This immunocompromised state predisposed him to severe bilateral CMV retinitis with reactivation.

This case illustrates several management challenges in CMV retinitis, particularly in patients with ART failure and significant systemic comorbidities. The absence of timely access to IVT therapy at initial presentation may have contributed to reactivation and eventual retinal detachment.[4] Reactivation rates are higher in patients with inadequate immune recovery or ongoing viraemia.

Furthermore, delayed ART optimisation owing to resistance patterns may prolong immunosuppression, increasing the risk of opportunistic infections and complications such as CMV reactivation. Differentiating between CMV reactivation and immune recovery uveitis remains a diagnostic challenge, particularly in patients recently transitioned to new ART regimens.

IVT ganciclovir is the treatment of choice for zone 1 retinitis, typically in combination with systemic antiviral therapy.[4] The patient responded well to a combination of IV and IVT ganciclovir during reactivation. Retinal detachment is a recognised complication of CMV retinitis, occurring particularly in eyes with extensive necrotic involvement. In the present case, the left eye (LE) developed macula-off RRD despite ART optimisation. During serial follow-up, peripheral retinal necrosis was closely monitored; no identifiable retinal breaks were detected to warrant prophylactic barrier laser treatment. Despite apparent clinical quiescence, structural retinal thinning likely predisposed the eye to delayed detachment.

At initial presentation, the LE demonstrated relatively milder zone 2 involvement compared with the right eye (RE), and both eyes received identical systemic antiviral therapy. The only difference in management was the number of intravitreal ganciclovir injections, which was determined by clinical response. Despite the milder initial presentation, the LE subsequently developed RRD. Retinal detachment in CMV retinitis is primarily attributable to necrotic retinal thinning and delayed atrophic break formation, rather than initial disease severity alone. Even eyes with apparently controlled retinitis remain structurally vulnerable; detachment may occur despite adequate antiviral therapy.

Multidisciplinary coordination between ophthalmology, infectious disease, and HIV care providers is crucial for early detection, systemic immune optimization, and timely ocular management.

CMV retinitis remains a significant cause of visual morbidity in the setting of advanced HIV infection. This case illustrates the potentially aggressive course and risk of reactivation and retinal detachment in patients with inadequate immune recovery. Early diagnosis, appropriate systemic and intravitreal antiviral therapy, and multidisciplinary care are essential for optimising visual outcomes.

REFERENCES

1. Jabs DA, Van Natta ML, Holland GN, Danis RP, Komaroff E, Enterline DS, et al. Cytomegalovirus retinitis in patients with the acquired immunodeficiency syndrome. Arch Ophthalmol 1992; 110(5): 729-32.
2. Sugar EA, Jabs DA, Ahuja A, Thorne JE, Danis RP, Meinert CL. Incidence of immune recovery uveitis in patients with cytomegalovirus retinitis treated with highly active antiretroviral therapy. Am J Ophthalmol 2012; 153(6): 1013-23.e3.
3. Jabs DA. Cytomegalovirus retinitis and the acquired immunodeficiency syndrome—bench to bedside: LXVII Edward Jackson Memorial Lecture. Am J Ophthalmol 2011; 151(2): 198-216.e1.
4. Martin DF, Sierra-Madero J, Walmsley S, Wolitz RA, Macey K, Georgiou P, et al. A controlled trial of valganciclovir as induction therapy for cytomegalovirus retinitis. N Engl J Med 2002; 346(15): 1119–26.
5. Panel on Antiretroviral Guidelines for Adults and Adolescents. Guidelines for the Use of Antiretroviral Agents in Adults and Adolescents with HIV [Internet]. U.S. Department of Health and Human Services; 2023 [cited 2025 May 6]. Available from: https://clinicalinfo.hiv.gov

CASE REPORT

The great mimicker in the tropics: A case of neuromelioidosis presenting diagnostic challenges in rural Sarawak

Kok Yin Yee, MD[1], Wong Tze Cheng, MRCP[1], Lim Han Hua, MRCP[2]

[1]Department of Medicine, Sarikei Hospital, [2]Infectious Disease Unit, Department of Medicine, Sarawak General Hospital

SUMMARY

Melioidosis, caused by *Burkholderia pseudomallei*, is a severe and potentially fatal infection prevalent in Southeast Asia and Northern Australia, with an estimated 89,000 deaths per year worldwide. While central nervous system (CNS) involvement is relatively rare, occurring in only 1-5% of cases, it is associated with significantly higher mortality. This case report details an unusual presentation of neuromelioidosis in a 47-year-old patient with hyperlipidemia, who initially presented with headache, vomiting, and unsteady gait, mimicking other neurological conditions. Diagnostic challenges arise due to non-specific cerebrospinal fluid (CSF) findings and initial CT brain results, delaying prompt diagnosis. Ultimately, B. pseudomallei was identified in the blood cultures. Subsequent imaging revealed worsening subdural collections and leptomeningeal enhancement, indicative of a severe CNS infection. This case underscores the complexities in diagnosing neuromelioidosis, emphasizing the critical need for clinicians in endemic regions to maintain a high index of suspicion in patients presenting with atypical neurological symptoms. Prompt microbiological confirmation and aggressive, prolonged antibiotic therapy are essential for effective management and improved patient outcomes.

INTRODUCTION

Melioidosis is caused by *Burkholderia pseudomallei*, or *B. pseudomallei*, a gram-negative, motile, aerobic, non-spore-forming soil saprophyte. It is mostly found in tropical climates, especially in Southeast Asia and Northern Australia.[1] Several risk factors have been associated with an increased susceptibility to melioidosis, with diabetes being the major risk factor, followed by other risk factors including excessive alcohol consumption, chronic kidney disease, and the use of glucocorticoids.[2]

Melioidosis is associated with significant morbidity and mortality. The average annual incidence rate in Malaysia is 3.41 per 100,000 population, with almost 50% of patients with bacteremic melioidosis succumbing to death.[4] The organism has been isolated from moist soil and water from all states in Malaysia. The peak age-specific incidence occurred from 41 to 59 years for both males and females in Malaysia, with a Male: Female ratio of 3.2:1.[5]

Often, melioidosis presents with non-specific signs and symptoms, which hinder diagnosis and management; hence, the disease has been nicknamed 'the great mimicker. ' The disease can vary widely, ranging from subtle conditions to severe life-threatening conditions, such as central venous system involvement, which is rare (1–5%) but statistically associated with higher case mortality (up to 25%). We report a case of neuromelioidosis from Sarikei, Sarawak.

CASE PRESENTATION

A 47-year-old man, a non-smoker and occasional alcohol drinker, working as a pepper farmer with underlying dyslipidemia, Hepatitis B, and undiagnosed Diabetes Mellitus, presented with one week of throbbing headache in the occipital region with two episodes of vomiting and right jaw pain. There was no fever, unilateral body weakness, blurred vision, neck stiffness, or altered behavior. The initial vital signs were normal. Central nervous system examination revealed a slow response to questions and a clumsy gait.

At the initial presentation, the patient had mild transaminitis and hyponatremia (Table 1). Notably, the total white blood cell count and platelet levels were within the normal range. A plain computed tomography (CT) scan of the brain revealed a prominent right high parietal extra-axial space, which manifested as a non-focal enhancing brain parenchymal lesion on the contrast scan. Cerebrospinal fluid (CSF) examination revealed a protein level of 0.92 g/L, a serum-to-fluid glucose ratio of 0.51, and 6 lymphocytes/µL. Gram stain, culture and sensitivity, and acid-fast bacilli tests were all negative. Intravenous ceftriaxone and aciclovir were started to empirically treat the central nervous system infection.

On day 3 of treatment, his condition worsened, he desaturated under ambient air, and developed diabetic ketoacidosis. Serial chest X-rays revealed the appearance of diffuse, fluffy alveolar infiltrates in the bilateral lungs. Multiple splenic microabscesses were observed on abdominal ultrasonography. His exposure history coupled with the clinical picture led to a strong clinical suspicion of disseminated melioidosis, and treatment was switched to intravenous meropenem and oral sulfamethoxazole-trimethoprim. Blood culture later grew *Burkholderia pseudomallei*, which was sensitive to amoxicillin-clavulanate, sulfamethoxazole-trimethoprim, and ceftazidime.

This article was accepted: 15 June 2026
Corresponding Author: Wong Tze Cheng
Email: tchengwong91@hotmail.com

Table I: Blood Investigation trend throughout illness

Day of Illness	7	10	11	12	13	14	15	16	19	24	34	41	47	50
Hemoglobin (g/dL)	12.7	10.2	9.9	10.0	10.1	9.8	10.6	11.8	10.6	11.2	11.9	11.1	16.7	11.4
White cells (103/µl)	10.3	5.39	4.67	6.79	7.38	7.04	8.56	11.4	8.42	4.64	5.47	8.63	9.28	8.65
Platelets (103/µl)	240	143	106	73	68	95	146	238	256	379	516	484	410	205
Sodium (mmol/L)	124	121	125	119	117	123	126	123	126	130	128	135	137	
Potassium (mmol/L)	4.2	2.7	3.0	2.7	2.6	3.0	3.9	4.6	4.2	3.9	3.5	3.4	4.1	4.1
Urea (mmol/L)	3.8	2.9	3.6	3.8	2.9	3.0	3.3	4.3	5.2	4.6	4.1	4.3	3.9	3.8
Creatinine (µmol/L)	70	77	64	49	54	43	42	55	62	89	101	93	91	94
Total bilirubin (µmol/L)	5.4	10.6	26.9	50.3	60.3	51.7	44.8	37.9	27.1	18.6	15.4	9.7	8.7	8.6
Direct bilirubin (µmol/L)	2.9	6.0	16.8	33.4	38.3	26.9	20.1	14.6	9.5	8.4	6.7	4.4	3.8	1.8
Aspartate transferase (U/L)	62	554	1530	466	212	108	73	42	36	76	77	29	35	47
Alanine transaminase (U/L)	134	184	368	253	174	121	94	60	41	28	59	54	50	59
Alkaline phosphatase (U/L)	512	291	303	272	278	259	280	338	275	216	174	147	126	130
Total protein (g/L)	84	59	54	54	57	55	60	75	70	82	91	83	83	79
Albumin (g/L)	34	26	24	24	25	24	25	29	27	33	39	36	39	39
Globulin (g/L)	50	33	30	30	32	31	35	46	43	49	52	47	44	50
Calcium (mmol/L)	2.34	2.02	2.11			2.2								
Phosphate (mmol/L)	0.86	0.11	0.29			0.29								
Creatinine Kinase (U/L)	34		1594		768	623								
C Reactive Protein (mg/L)		197			164			71		3	10	4		

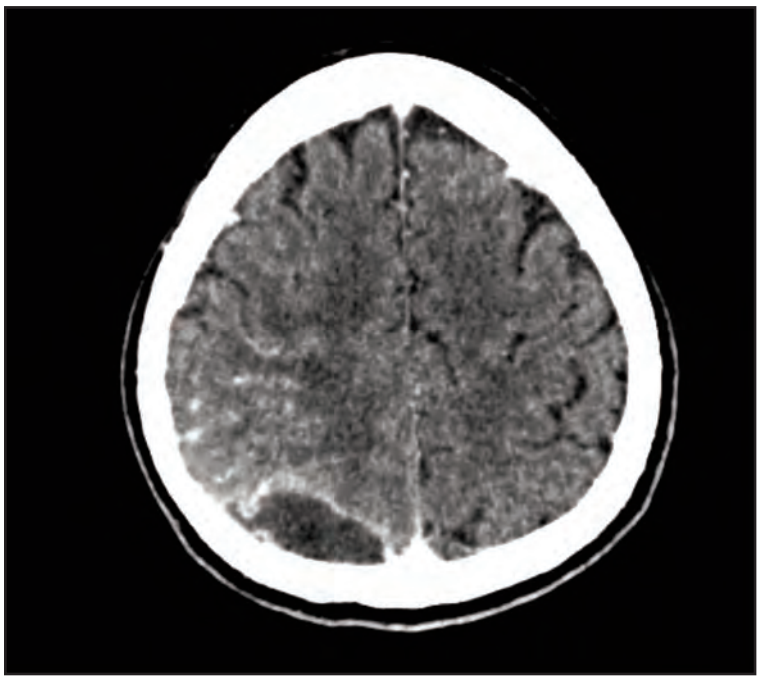

Fig. 1: Contrast Computed Tomography of Brain 14 days after treatment

Repeated contrast-enhanced CT of the brain 14 days after treatment showed worsening features, with leptomeningeal enhancement in the right parieto-occipital and left occipital regions and an enlarging subdural hypodensity in the right parietal lobe, with two new subdural hypodensities with rim enhancement abutting the superior sagittal sinus, suggestive of subdural empyema (Figure 1). Unfortunately, the empyema was deemed not amenable to drainage. Intravenous meropenem was then extended to complete a 6 weeks course, with oral sulfamethoxazole-trimethoprim.

With antibiotics, the patient showed clinical, biochemical, and radiological improvement. Neurological symptoms resolved, and no fever was documented. C-reactive protein and white blood cell count were reduced. At the end of 6 weeks of intravenous antibiotics, repeated abdominal ultrasonography showed improvement in splenic lesions, and contrasted CT brain revealed significantly smaller subdural hypodensity at the right parietal lobe with peripheral enhancement and residual leptomeningeal enhancement (from initial 1.8 × 4.3 cm to 0.3 × 1.7 cm).

He was then discharged to complete a total of 6 months of maintenance therapy with sulfamethoxazole-trimethoprim. A follow-up review noted that he had no residual neurological deficits and could resume his usual work and activities. Repeated contrast-enhanced CT of the brain revealed complete resolution of the leptomeningeal enhancement and empyema.

DISCUSSION

The patient's presentation of headache, vomiting, and unsteady gait, coupled with initial nonspecific CT findings, is suggestive of a broad differential diagnosis, including other CNS infections. However, the subsequent development of diabetic ketoacidosis, pulmonary infiltrates, and splenic microabscesses, along with the patient's exposure history, raised a strong clinical suspicion of disseminated melioidosis, which was confirmed by a positive culture.

The first report of CNS melioidosis was presented in 1977.[7] While disseminated melioidosis occurs in 16-37%, CNS involvement is rare, accounting for only 1.5-5% of all reported cases. Of note, a review noted that neurological infection (7.5%) in Malaysia was higher than that in Thailand (3.0%), India (1.1%), and Australia (2.6%).[2] It has shown a male preponderance and affects a younger population than melioidosis of all sites, consistent with the case reported.[1,6]

Neuromelioidosis is a rare but severe manifestation of melioidosis. It poses significant diagnostic challenges, especially in differentiating it from other CNS infections, earning melioidosis the moniker 'the great mimicker. ' Despite being primarily presented as pyemic, such as brain, subdural, and epidural abscesses,[7] cases with meningoencephalitis have also been reported. In this case, the initial CSF and CT findings were nonspecific, underscoring the difficulty in differentiating neuromelioidosis from other infectious or inflammatory processes.

A wide spectrum of neurological manifestations has been reported in neuromyelitis. In a systemic review by Wongwandee et al., headache (54%), unilateral weakness (57%), and cranial nerve deficits (52%) were the prominent presentations.[7] Currie et al. reported cerebellar signs in 50% of neuromyelitis cases.[1] Our patient presented with headache and had an unsteady gait without weakness, possibly attributed to cerebellar involvement. Therefore, a high index of suspicion is required to identify central nervous system involvement in laboratory-proven melioidosis.

Culture remains the gold standard for the isolation of Burkholderia pseudomallei.[3] However, this is limited by the difficulty in pathogen identification and prolonged incubation and identification time, potentially leading to delays in diagnosis and treatment. Therefore, dependence on culture alone for establishing the diagnosis of neuromelioidosis can be challenging. While real-time polymerase chain reaction (PCR) is a promising diagnostic tool, it may not be readily available in economically disadvantaged and resource-limited settings.[3]

The CSF profile mostly shows mononuclear pleocytosis, high protein, and normal glucose levels, which is consistent with our case.[7] However, these findings are non-specific and can mimic other types of meningoencephalitis. Therefore, it cannot be used as the sole marker for diagnosing neuromelioidosis. Notably, the CSF culture was negative. It is reported that the organism is isolated from brain tissue, pus, CSF, or blood in only 50% of the cases.[8] In our case, due to anatomical limitations, drainage of subdural empyema was not performed, making it impossible to culture the pus.

Apart from culture, brain imaging is essential for establishing a diagnosis. Unfortunately, the lack of sensitivity of CT scans in identifying features of neuro-melioidosis, particularly in the early stage, is fiendish.[1] In a case review of neurologic melioidosis by Currie et al., eight of 11 initial CT scans showed normal results, and in the remaining patients, only non-specific changes were observed.[1] In our case, the patient's initial contrast-enhanced CT findings were non-specific, leading to difficulty in revealing his neurologic involvement. While magnetic resonance imaging (MRI) can provide additional information even in cases with normal CT findings, as demonstrated by the study done by Currie et al., this modality may not be readily available, especially in resource-limited settings.[1]

We believe that neuromelioidosis remains underreported, especially in endemic regions, because of its unusual presentation and difficulty in diagnosis. In Malaysia, the absence of pathognomonic clinical presentations, coupled with the lack of familiarity with the disease among attending physicians and laboratory personnel, are the main factors contributing to misdiagnoses, especially in rural settings.[2] The limited availability of advanced diagnostic tools, such as rapid polymerase chain reaction (PCR) or antigen detection tests, delays definitive diagnosis. In our case, the diagnosis relied on clinical suspicion and subsequent blood culture results, which took several days to obtain.

In view of CNS involvement, a prolonged course of intravenous antibiotics was warranted. Podin et al. reported that up to 86% of clinical isolates from all melioidosis patients in district hospitals in Sarawak, Malaysia were gentamicin-susceptible,[9] while the Darwin guideline suggested that IV meropenem is the initial treatment of choice with a dose doubled to 2 g 8-hourly.[10] The subsequent maintenance therapy with sulfamethoxazole-trimethoprim also requires proper planning to ensure compliance for complete eradication. Our patient showed complete clinical and radiological recovery at the end of treatment.

This case highlights the importance of clinical vigilance among treating clinicians, especially in exploring environmental exposure and establishing epidemiological links in endemic regions. Early recognition and treatment can potentially improve the outcomes of neuromelioidosis. Simultaneously, the One Health approach involving healthcare professionals, veterinarians, environmental scientists, and public health officials is essential to address the disease burden by improving the surveillance, prevention, and control of melioidosis.

In conclusion, this case report highlights an unusual presentation of melioidosis with central nervous system involvement, which poses diagnostic and therapeutic challenges. Neuromyelitis is rare but potentially fatal. The patient's initial nonspecific symptoms and complex clinical course underscore the importance of considering melioidosis in patients presenting with neurological manifestations, particularly in endemic regions. Early suspicion, prompt microbiological confirmation, and aggressive antibiotic therapy are crucial for managing these cases.

REFERENCES

1. Currie BJ, Ward L, Cheng AC. The epidemiology and clinical spectrum of melioidosis: 540 cases from the 20 year Darwin prospective study. PLoS Negl Trop Dis 2010; 4(11): e900.
2. Nathan S, Chieng S, Kingsley PV, Mohan A, Podin Y, Ooi MH, et al. Melioidosis in Malaysia: incidence, clinical challenges, and advances in understanding pathogenesis. Trop Med Infect Dis 2018; 3(1): 25.
3. Chen C, Fang J, Li X, Nelly J, Zhang N, Zhang Y, et al. Diagnostic accuracy of non-culture methods for the diagnosis of melioidosis: a systematic review and meta-analysis. BMC Infect Dis 2025; 25(1): 1.
4. Arushothy R, Mohd Ali MR, Zambri HF, Muthu V, Hashim R, Chieng S, et al. Assessing the national antibiotic surveillance data to identify burden for melioidosis in Malaysia. IJID Reg 2024; 10: 94-9.
5. Puthucheary SD, Vadivelu J. Human melioidosis. Singapore University Press; 2002.
6. Deuble M, Aquilina C, Norton R. Neurologic melioidosis. Am J Trop Med Hyg. 2013; 89(3): 535-9.
7. Wongwandee M, Linasmita P. Central nervous system melioidosis: a systematic review of individual participant data of case reports and case series. PLoS Negl Trop Dis 2019; 13(4): e0007320.
8. Shobhana A, Datta A, Trivedi S. CNS melioidosis: a diagnostic challenge. Neurol India 2022; 70(2): 778-80.
9. Podin Y, Sarovich DS, Price EP, et al. Burkholderia pseudomallei isolates from Sarawak, Malaysian Borneo, are predominantly susceptible to aminoglycosides and macrolides. Antimicrob Agents Chemother 2014; 58(1): 162-6.
10. Currie BJ, Janson S, Meumann E, Martin GE, Ewin T, Marshal CS. The 2024 revised Darwin melioidosis treatment guideline. Northern Territory Disease Control Bulletin 2023; 30(4): 3–12. Accessed February 25, 2026. https://health.nt.gov.au/professionals/centre-for-disease-control/northern-territory-disease-control-bulletin

CASE REPORT

Small cell neuroendocrine carcinoma of Vagina: A rare case report

Nur Khairiyah AR, MRCOG, Lim Yi Jie, MRCOG, Muhammad Noor Asyraf Z, MOG, Sim Wee Wee, MRCOG

Gynaeoncology Unit, Department of Obstetrics and Gynaecology, Hospital Umum Sarawak, Malaysia

SUMMARY

Small cell neuroendocrine carcinoma of the vagina is a rare form of primary vaginal cancer. It is an aggressive vaginal carcinoma with poor prognosis. Most of the reported cases were among women aged 40-70 years old. Owing to its aggressiveness, multimodal treatment, including surgery, radiotherapy, and chemotherapy, has been suggested. However, many women present with metastasis and eventually succumb to the disease. Here, we report a case of vaginal neuroendocrine carcinoma in a 29 year old lady which we managed at our institution. She presented with a short history of right vulvovaginal swelling of one month duration and was treated for vulvovaginal abscess.

INTRODUCTION

Small cell neuroendocrine carcinoma of the vagina is a rare form of primary vaginal cancer, accounting for 2% of all gynecological malignancies.[1] In the English literature, only 45 cases have been reported.[1,4,9] It is known for its aggressiveness, poor prognosis, and difficulty in treatment.[1] Most of the reported cases were among women between 40-70 years old. However, in our case report, it involved a young woman with symptoms mimicking infection. Due to the less common presentation of small cell neuroendocrine carcinoma of the vagina, especially in younger age groups, she was misdiagnosed as having a vulvovaginal abscess. The aim of this case report is to create awareness that neuroendocrine carcinoma of the vagina can also present with symptoms mimicking infection and abscess. A high index of suspicion should be maintained, especially when the patient does not respond to initial antibiotics.

CASE PRESENTATION

A 29-year-old married woman, para 0+1, presented to the emergency department with complaints of right vulvovaginal swelling of one month's duration associated with worsening pain at the perineum. She was initially administered oral antibiotics for 1 week from the primary health clinic; however, her condition did not improve. The swelling increased in size and became more painful. There was no pus discharge or lower abdominal pain present. There was no weight loss or appetite. No other significant medical or family histories were obtained.

She was examined by the gynecological team, which showed a right vulvar mass extending to the right vagina measuring 6 × 5 cm, which was tender on palpation and hard. No pus points were observed. The diagnosis at the time was a right vulvovaginal abscess. The inguinal lymph nodes were enlarged bilaterally. She underwent incision and drainage of the right vulvovaginal wall swelling. Intraoperatively, the swelling measured 5 × 5 cm and extended to the right perineum. The vaginal wall appeared unhealthy, and the tissue was sent for histopathological examination. Her cervix appeared normal, and liquid cytology of the cervix was performed.

Microscopic examination revealed neoplastic tissue composed of diffuse solid sheets and cords of highly atypical cells with scant and discernible cytoplasm, ovoid to slightly spindled nuclei with hyperchromatic and dispersed chromatin, and inconspicuous nucleoli. The tumor demonstrated a small cell neuroendocrine carcinoma morphology.

On immunohistochemistry (IHC), the tumor was positive for synaptophysin, chromogranin, and CD 56 with a high Ki67 index. Liquid-based cytology of the cervix was negative for intraepithelial lesions or malignancy.

An MRI of the pelvis dated 22.11.2024 was done to assess the extent of the disease. It showed a lobulated mass involving the lower third of the vagina, extending to the right vulvar region, epicentered in the vulvar region, exhibiting an intermediate signal with homogeneous enhancement and local infiltration (Figure 1). Anteriorly, it abuts the urethra with no clear fat plane. Posteriorly, it involves the lower third of the posterior vaginal wall with no clear fat plane with the anterior anal canal wall. There were also right iliac and bilateral inguinal lymph node metastases (Figures 2,3). Computed tomography (CT) of the thorax, abdomen, and pelvis done on 22.11.2024 showed distant metastasis to the lungs and paratracheal and hilar nodes. No PET scan was performed because of the unavailability of PET scans in government hospitals in Sarawak at the time of presentation.

The case was discussed in a multidisciplinary team meeting (MDT) with an oncologist, radiologist, pathologist, and gynaeoncologist . The conclusion that the MDT was diagnosis of primary small cell neuroendocrine carcinoma of the vagina (FIGO stage IVB), and the agreed treatment plan was palliative chemotherapy due to the advanced disease. The patient and her husband were informed of the diagnosis and treatment plan and agreed to palliative chemotherapy.

This article was accepted: 15 June 2026
Corresponding Author: Nur Khairiyah Ab Rahim
Email: khairiyahabr@gmail.com

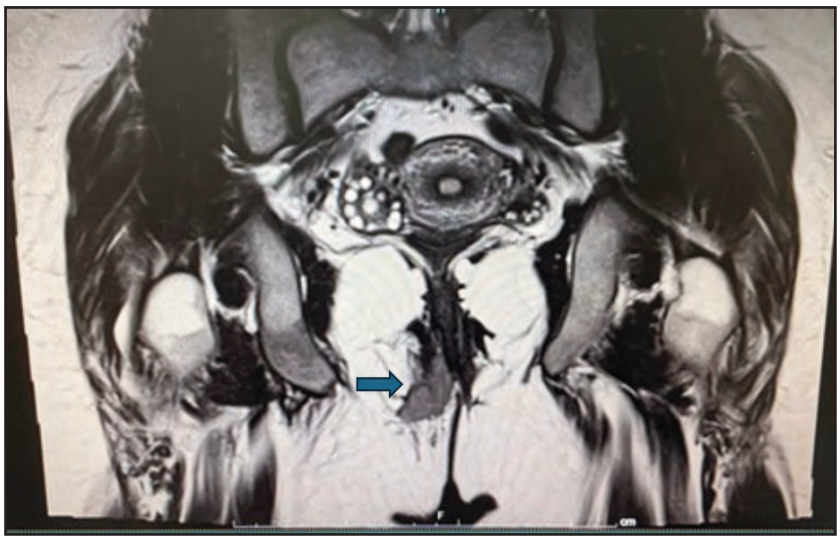

Fig. 1: Coronal view of MRI of the pelvis demonstrated lobulated mass involving lower third of vagina extending to right vulva region

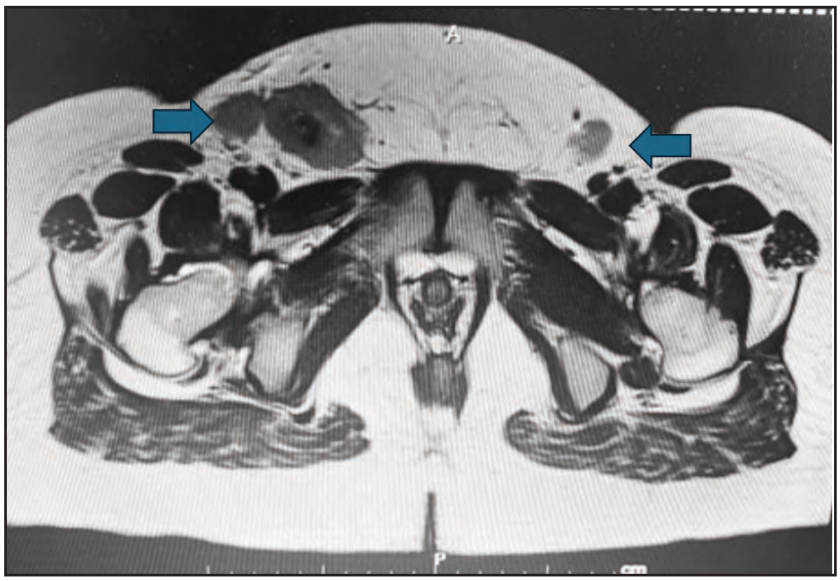

Fig. 2: Axial view of MRI pelvis showing bilateral inguinal lymph node metastases



Fig. 3: MRI of pelvis showing enlarged right external iliac lymph nodes

She was subjected to palliative chemotherapy with seven cycles of carboplatin and etoposide by the oncology team. A CT scan after seven cycles of chemotherapy was performed on 19.6.2025, 9 months after the diagnosis, and showed a slight reduction in the size of the vulva vagina mass and the inguinal and external iliac lymph nodes. However, new bone metastasis was detected involving both inferior and superior pubic rami, pubic tubercle, right ischium, left ilium, and T9 vertebral body.

DISCUSSION

Neuroendocrine tumors are a spectrum of malignancies, with small cell carcinoma being the most aggressive form. Most small cell carcinomas originate from the lungs, and 5% are extrapulmonary.[1] Primary small cell carcinoma of the vagina is rare, with only 45 cases reported worldwide.[1-2,4,9] The first case of primary small cell carcinoma of the vagina was reported in 1984 by Scully et al.[7]

The clinical presentation varies from asymptomatic to those who present with symptoms such as vaginal mass, vaginal pain, dyspareunia, vaginal discharge, or postcoital bleeding.[1,4,6] Our patient presented with pain and swelling in the vagina. Due to its non-specific presentation and rarity, diagnosis is often delayed. Patients may already have metastatic disease at the time of diagnosis.

The association between HPV and small cell neuroendocrine carcinoma of the vagina remains unexplored. A systematic review by Capote et al. showed that only four of the 45 reported cases were hPV-positive. Three of them were HPV 18, and another was high risk non 16, 18 HPV, which was not specified.[9] More research is needed to identify any association with HPV.

Owing to the aggressiveness of the disease, 50% of patients present at an advanced stage.[4] The median survival time is 11 months, and approximately 85% of patients die within 12 months after the initial diagnosis.[4,8] As the disease is rare, there is still no consensus on the standard treatment. Complete remission with radiation and/or combination chemotherapy in early stages in cases with smaller tumor sizes (ranging from 0.5 to 3 cm) can be seen.[4]

Multimodal treatment with surgery, chemotherapy, and radiation is recommended even in the early stages because of the aggressiveness of the disease. Surgery is usually recommended for cases with smaller tumor sizes (0.5–3 cm) and localized disease with no evidence of metastasis.[2,4] Recommended surgery for early stage disease depends on the location of the lesion. If it involves the upper third of the vagina, radical hysterectomy and vaginectomy are recommended.[9]

For locally advanced disease, the suggested management is combination chemotherapy with radiation therapy, including external beam radiotherapy to the pelvis up to 45 Gy, followed by brachytherapy.[2,9] Two commonly used chemotherapy regimens are cyclophosphamide, doxorubicin, and vincristine or cisplatin and etoposide.[2,4] A systematic review by Capote et al. showed that the median OS of those who received surgery plus radiation was 29 months, and for those who received concurrent chemoradiation, it was 17months.[9]

Currently, the role of immunotherapy is being investigated in small cell neuroendocrine carcinoma; however, it is more focused on lung cancer.[10] There was a report on RRx-001 (an M2-to-M1 macrophage stimulating agent) as maintenance after cisplatin/etoposide as first line, but progression was observed after 6 weeks of treatment.[9-10]

In conclusion, small cell neuroendocrine carcinoma of the vagina is a rare form of vaginal cancer. The presentation is usually nonspecific and typically seen in the postmenopausal age group. Therefore, diagnosis is often delayed, and patients usually present at an advanced stage where treatment is usually palliative.

Owing to the aggressiveness of the disease, treatment should be multimodal. Surgery is usually recommended for small tumors with no evidence of metastasis. For those with locally advanced disease, a combination of chemotherapy and radiation therapy is recommended. More trials should be conducted to identify the most effective treatment modality for vaginal small cell neuroendocrine carcinoma.

REFERENCES

1. Asghar A, Usman A, Sheikh A, et al. Small Cell Neuroendocrine Carcinoma of the Vagina: A Rare Presentation. Cureus 2023; 15(7): e42387.
2. Puja K, Arya AK, Yadav A, Durgesh. A Case Report on Primary Neuroendocrine Cancer of Vagina. Clin Med Rev Case Rep 2021; 8: 360.
3. Kostamo K, Peart M, McKenzie N, Holloman C, Carlan SJ, Maksem J et al. Novel treatment of small cell neuroendocrine of the vagina. Case Rep Oncol Med 2018: 9157036
4. Pongsuvareeyakul T, Garcia-Moliner M, Lokich E, Dizon DS, Singh K: Small cell neuroendocrine carcinoma of vagina: report of a unique case with literature review. Cancer Treat Res Commun. 2022; 33: 100645. 10.1016/j.ctarc.2022.100645
5. Bidkar VC, Acharya G, Kulkarni KA, et al. Neuroendocrine Carcinoma of Female Genital Tract: Series of Nine Cases. Indian J Gynecol Oncolog 19, 1 2021. https://doi.org/10.1007/s40944-020-00480-x
6. Kalampokas E, Giannis G, Alexandrou P, Kritikos E, Triantafyllidou O, et al. Small-cell neuroendocrine carcinoma of the vagina: A case report. Int J Gynaecol Obstet 2023; 161(2): 678-9.
7. Scully RE, Aguirre P, DeLellis RA. Argyrophilia, serotonin, and peptide hormones in the female genital tract and its tumors. Int J Gynecol Pathol 1984; 3: 51-70.
8. Khurana A, Gupta G, Gupta M, Kaur M. Primary neuroendocrine carcinoma of the vagina with coexistent atypical vaginal adenosis : A rare entity. J Can Res Ther 2013;9:328-30.
9. Capote S, Domènech M, Valdivieso L, et al. Small Cell Carcinoma of the Vagina: First Systematic Review of Case Reports and Proposal of a Management Algorithm. Journal of Lower Genital Tract Disease 2023; 27(1): 56-67.
10. Paz-Ares L, Dvorkin M, Chen Y, et al. Durvalumab plus platinum-etoposide versus platinum-etoposide in first-line treatment of extensive-stage small-cell lung cancer (CASPIAN): a randomised, controlled, open-label, phase 3 trial. Lancet 2019; 394: 1929-39.

Good's syndrome complicated with bronchiectasis with pulmonary hypertension

Chun Fei Yap, MRCP[1], Keen Tien Boey, MD[2], Yi Fan Goh, MD[1], Say Thin Chu, MRCP[1], Jiunn Sheng Chin, MRCP[1]

[1]Department of Internal Medicine, Hospital Duchess of Kent, [2]Department of Internal Medicine, Hospital Putrajaya

SUMMARY

Good's syndrome (GS) is a rare but important adult-onset immunodeficiency characterized by the coexistence of thymoma and hypogammaglobulinemia in adults. Diagnosis is often delayed because of the wide interval between the appearance of thymoma and the onset of immunodeficiency-related infections. Clinicians should maintain a high index of suspicion in adults with thymoma and recurrent or unusual infections, particularly respiratory infections, and routinely assess serum immunoglobulin levels. Early recognition and initiation of immunoglobulin replacement therapy are essential for reducing infectious complications and improving outcomes. Thymectomy, while necessary for tumor control, does not reverse immune dysfunction. This case report of GS aims to raise awareness among healthcare workers for patients with thymoma who present with recurrent or unusual infections and further workup for this group of patients. We herein report a case of a young female patient with underlying type AB thymoma but defaulted follow-up, history of bacteremia, and presented with recurrent pulmonary infections complicated with pulmonary hypertension who was found to have hypogammaglobulinemia leading to a diagnosis of GS. She was treated with intravenous immunoglobulin (IVIG) and was subsequently planned for long-term immunoglobulin replacement therapy.

INTRODUCTION

GS, an adult-onset immunodeficiency associated with thymoma, leads to immune system dysfunction and increased susceptibility to severe infections due to encapsulated bacteria, viruses, and fungi.[1-2] Both males and females are equally affected, commonly in their 4th or 5th decade of life, although it can rarely occur in younger patients.[1-2] It is challenging to recognize the disease because of its complexity, frequently leading to diagnostic delays.[2-3] Treatment mainly involves immunoglobulin replacement, treatment of infections, and removal of thymoma.[3-4] The prognosis is believed to be worse than that of other adult immunodeficiency conditions.[5]

CASE PRESENTATION

A 33-year-old single, nulliparous, non-smoker woman with a history of childhood asthma and recurrent pulmonary infections, including Salmonella non-typhi bacteremia, and recurrent admission for pulmonary infections presented with a 6-month history of productive cough without hemoptysis. She reported significant unintentional weight loss and reduced appetite over the same duration, along with a 2-week history of progressive shortness of breath.

Physical examination revealed bilateral generalized rhonchi accompanied by crepitations across both lung fields. Initial blood gas analysis showed type II respiratory failure, with a full blood count showing leukocytosis and elevated C-reactive protein levels of 58 × 10^3/µL (neutrophil predominance) and 74 mg/L. Chest radiography revealed consolidation with cavitation in the bilateral upper lung zones. She was initially intubated for 1 week for respiratory failure, requiring intensive care unit (ICU) admission for 9 days before transfer to the general medical ward for further treatment. She was treated for community-acquired pneumonia (CAP) with a 1-week course of intravenous Meropenem in ICU. Although she improved and was transferred to a general medical ward, her condition deteriorated and she developed desaturation five days later. She was then treated for Pseudomonas aeruginosa pneumonia, as evidenced by a positive sputum culture, with a total of one month of anti-Pseudomonas antibiotics. Computed tomography pulmonary angiography was performed due to the patient's difficulty in oxygen weaning, and it showed no pulmonary embolism.

Serial infective workups showed negative blood, fungal, urine, and Mycobacterium tuberculosis cultures. Connective tissue workup showed normal C3/C4 values with negative antinuclear antibodies (ANA) and anti-neutrophil cytoplasmic antibodies, while the immunoglobulin test showed hypogammaglobulinemia with IgA, IgG, and IgM values of 0.3 g/L, 4.02 g/L, and <0.25 g/L, respectively, with a raised ESR value of 21 mm/h. Contrast-enhanced computed tomography (CECT) of the thorax showed features consistent with organizing pneumonia with bilateral upper lung lobe fibrosis and bronchiectasis changes, as well as an anterior mediastinal mass representing thymoma. Further history revealed that the patient had a thymoma previously, for which thymectomy was not performed as she defaulted to follow-up. Echocardiography was also performed to look for complications of bronchiectasis and showed pulmonary hypertension.

In view of the collective evidence of recurrent pulmonary infection, presence of thymoma type AB, and hypogammaglobulinemia, a diagnosis of GS was made. The patient was discharged after 3 months of hospitalization, and two courses of IVIG were administered during admission. Following a second course of IVIG one month after the first,

This article was accepted: 22 June 2026
Corresponding Author: Chun Fei Yap
Email: yapchunfei@moh.gov.my

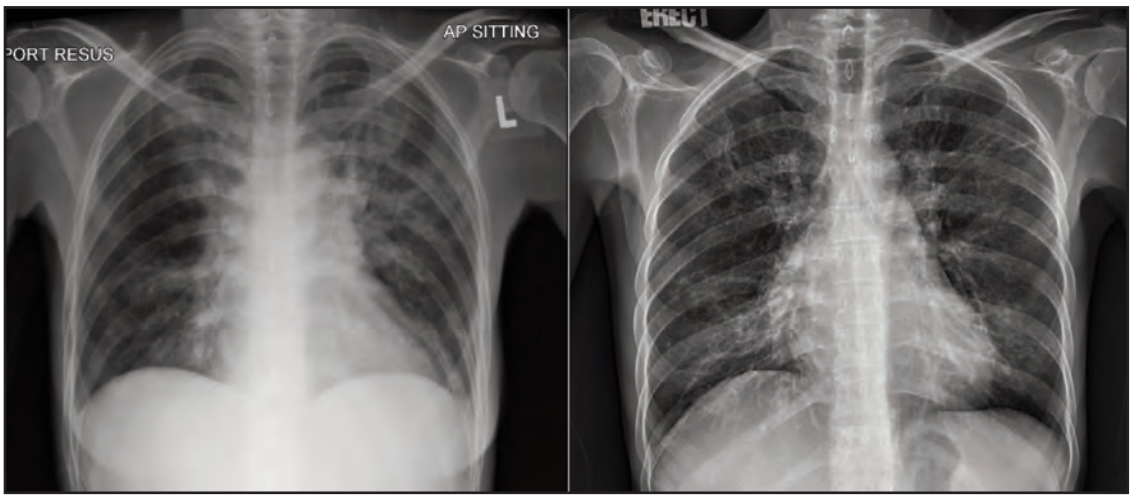

Fig. 1: Left - Chest radiograph upon arrival at the emergency department with pneumonia changes seen over the bilateral upper lobe; Right - Chest radiograph after two courses of antibiotics and one course of IVIG showing resolution of pneumonia

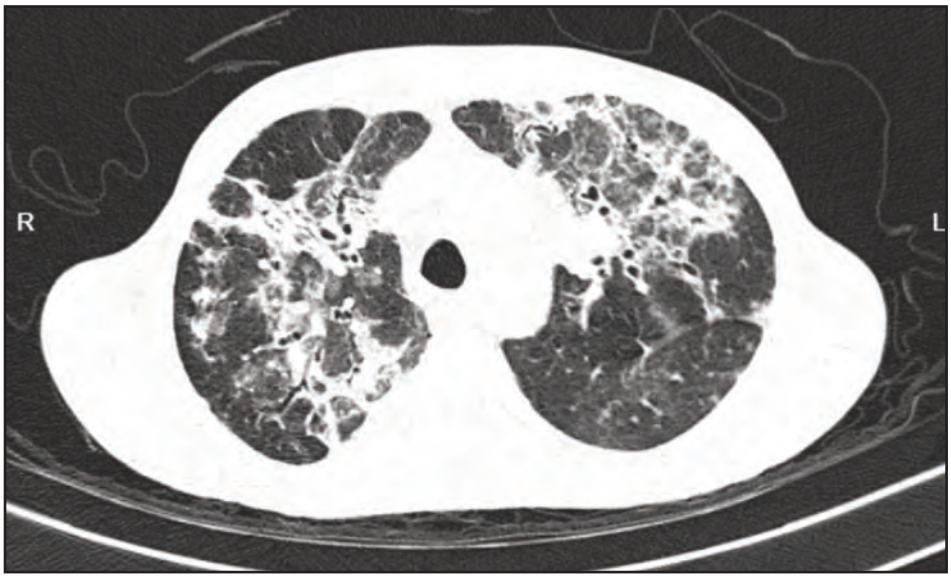

Fig. 2: Bronchiectasis changes from the CECT thorax

immunological reassessment showed IgG improvement from 4.02 g/L to 6.44 g/L after the second course. The post-treatment CD4 and CD8 levels were 404 cells/µL and 603 cells/µL, respectively, resulting in an inverted CD4/CD8 ratio of 0.67.

DISCUSSION

GS, a rare adult-onset immunodeficiency associated with thymoma, was first identified in 1954 by Dr. Robert Good, who described a case of thymoma and hypogammaglobulinemia in an adult patient.[6] The condition has an estimated incidence of 0.15 cases per 100,000 population annually. Hypogammaglobulinemia occurs in approximately 6–11% of patients with thymoma. GS typically presents between the ages of 40 and 60 years, with a prevalence of approximately 1 in 700,000 adults.[1] To our knowledge, based on a comprehensive review of the literature, no prior cases of GS have been reported from Sabah, making this the first documented case in this Malaysian state; however, there could be a possibility of prior unreported cases.

The pathogenesis of immunodeficiency in GS remains unknown, and there are no formal diagnostic criteria for this disorder. There is some evidence that the basic defect may be in the bone marrow, as suggested by the presence of B- and T-cell lymphopenia, pre-B-cell arrest, impaired maturation of erythroid and myeloid precursors, pure red cell aplasia (PRCA), neutropenia, and eosinophilia.[2] Although the principal feature of GS is humoral immunodeficiency, cell-mediated immunity is also impaired. Another proposed mechanism is that B cell dysfunction may be caused by autoimmune destruction, likely due to the presence of autoantibodies associated with thymomas, as observed in other paraneoplastic disorders.[7] T-cells from thymomas can

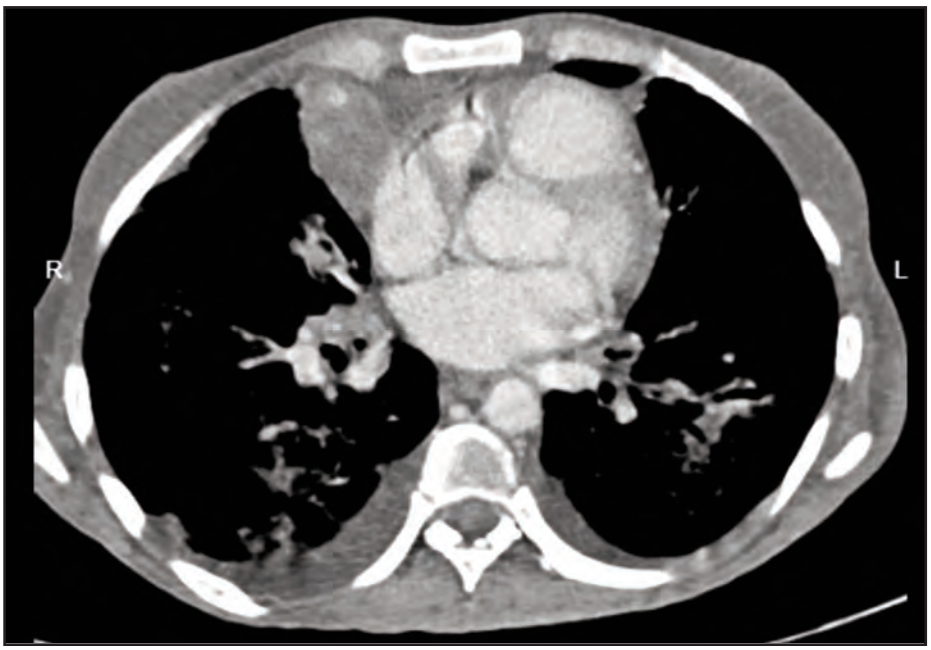

Fig. 3: Thymoma from CECT thorax

also impair the growth of B-cells and their immunoglobulin production. To date, it has been classified as a distinct entity by the expert committee of the World Health Organization/International Union of Immunological Societies on primary immunodeficiencies. Most of the literature reviews used the simultaneous presence of thymoma and hypogammaglobulinemia as the minimal diagnostic criteria for a diagnosis of GS, which in our case fulfilled these minimal diagnostic criteria.[8]

The clinical presentation of GS is highly variable and typically reflects the site of infection. Lower respiratory tract infections are the most frequently reported cases, but patients may also present with upper respiratory, gastrointestinal, skin and soft tissue, urinary tract, systemic, or central nervous system infections. Complications of this recurrent sinopulmonary infection, such as bronchiectasis, necrotizing pneumonia with lung abscess, and empyema, have also been noted in the literature by Tarr et al. and other authors. (2) With regard to causative micro-organisms, bacterial infections account for 80% of the cases, followed by viral and fungal infections.[5]

This patient's history of recurrent pulmonary infections led to bronchiectasis and type 2 respiratory failure. Furthermore, the patient developed group 3 pulmonary hypertension secondary to bronchiectasis. Due to the delayed diagnosis, the combination of pulmonary hypertension and type 2 respiratory failure necessitated long-term oxygen therapy.

Patients with GS usually present in the 4th or 5th decade of life. In a literature review of 51 patients with GS, the mean age of the patients was 56 years (range, 29 – 75 years) at the time of the 1st presentation (infection, thymoma, or hypogammaglobulinemia).[2] Diagnosis of thymoma preceded the diagnosis of hypogammaglobulinemia, infection, or diarrhea in 18 patients in the above literature with an interval of 3 months to 23 years, and in the remaining 29 patients, thymoma was diagnosed after the documentation of infection or hypogammaglobulinemia with an interval of 3 months to 20 years. Of the remaining four patients, two were diagnosed within two months of each other, and in the other two patients, thymoma was only diagnosed at autopsy. These results indicate that thymoma and hypogammaglobulinemia as the minimal diagnostic criteria can be fulfilled as short as within 2 months but can take up to 23 years, which can lead to a delay in diagnosis and treatment.[2] Another systematic review of 152 patients also reported that the diagnosis of thymoma preceded hypogammaglobulinemia or vice versa can be diagnosed within 2 months but can also take a longer period of up to 18 years.[3]

In this case, the patient was first diagnosed with an anterior mediastinal mass at the age of 29 years as an incidental finding when a CECT thorax was performed as part of the investigation for chronic cough. A biopsy of the anterior mediastinal mass was performed, and the histopathological features were in favor of thymoma type AB. Although the patient was not in the 4th or 5th decade of life, her first presentation was still within the range.[2] The patient was diagnosed with Good Syndrome only 4 years after the diagnosis of thymoma, as evidenced by hypogammaglobulinemia. Zaman et al reported in their article on 78 United Kingdom patients with GS that patients with AB-type thymomas were more likely to have bronchiectasis. Another systematic review by Dong et al. reported that type AB is the most common histologic type of thymoma in Chinese patients with GS, which is similar to the findings in our case.[8-9]

Prior to the diagnosis of Good syndrome, our patient experienced multiple episodes of respiratory infections, including several admissions for CAP. During her first

presentation, no pathogens were isolated from sputum or blood cultures, and the tuberculosis workup was negative; however, she had marked leukocytosis (white cell counts - WCC 59 × 10^3/μL) and elevated C-reactive protein (155 mg/L), which normalized after antibiotic treatment. A few years after her first encounter, she presented with a milder episode managed with outpatient antibiotics, again with negative cultures and a peak WCC of 17 × 10^3/μL. During her third encounter, she was admitted for CAP with non-typhoidal Salmonella isolated from blood despite no gastrointestinal symptoms. Subsequent stool and urine cultures were negative, and WCC peaked at 15.3 × 10^3/μL without significant leukocytosis. Another admission for pneumonia showed significant leukocytosis (WCC 70.3 × 10^3/μL), with Pseudomonas aeruginosa isolated from sputum. Although pulmonary tuberculosis remains a high-burden disease in Sabah, it is rarely associated with GS and was consistently ruled out during all admissions. Peripheral blood films consistently showed no evidence of hematological malignancy.

The principal immunological findings in GS are hypogammaglobulinemia, few or absent B cells, an abnormal CD4+:CD8+ T-cell ratio, CD4 + T-cell lymphopenia, and impaired T-cell mitogenic response. Almost all patients have reduced serum IgG, IgA, and IgM levels, but there are very limited data on the prevalence of reduced specific antibody levels. GS should be suspected in patients aged > 40 years with a history of recurrent sinopulmonary infections or opportunistic infections such as cytomegalovirus or mucocutaneous candidiasis, and further workup such as CECT thorax scan should be performed to look for any mediastinal mass. Conversely, serum immunoglobulins should be considered as part of routine diagnostic investigations for patients with anterior mediastinal masses. If the immunologic test results are normal, testing should be performed periodically if GS is suspected, because there can be an interval between the diagnosis of immunodeficiency and/or thymoma and the development of infection.[10]

The management of GS mainly consists of thymectomy for thymoma and gamma globulin replacement. The treatment of thymoma involves surgical intervention, either removal or debulking of the tumor, and the most important indicator of long-term prognosis is the completeness of tumor resection. Thymectomy can prevent locally invasive growth and metastasis of thymomas and usually has a favorable effect on associated conditions, such as myasthenia gravis and PRCA; however, it does not usually reverse the immunological abnormalities in GS.[4] Lifelong immunoglobulin replacement therapy to maintain adequate trough IgG levels has been reported to improve infection control, reduce hospitalization, and decrease the use of antibiotics. In one study, 23 of 30 patients (76%) had a reduction in the number of bacterial sinopulmonary infections, while another study reported that approximately 38% of patients with GS had a reduced incidence of infections after treatment with gamma globulin.[2-3] Thus, IVIG is recommended to maintain appropriate immunoglobulin levels in all these patients. Hizantra, a subcutaneous immunoglobulin, has been FDA-approved for use in immunodeficiency since 2010 and is commonly being transitioned from IVIG, especially in patients who require long-term immunoglobulin replacement. Subcutaneous immunoglobulin is reported to be much more convenient and easier to use, achieving a similar result compared to IVIG, with tolerable minimal side effects.

The patient is scheduled for lifelong monthly IVIG infusions with regular reassessment of immunoglobulin levels while awaiting approval for subcutaneous administration of immunoglobulin. After two courses of IVIG, her IgG levels improved, and she remained free of admission at the time of this report. The patient was enrolled in a regular pneumococcal and influenza vaccination program. She is currently under cardiothoracic review for thymoma, with ongoing discussions regarding thymectomy as part of her management.

In conclusion, this case highlights the importance of clinical awareness and knowledge of GS in patients with thymoma, as delayed recognition can lead to repeated hospital admissions and missed opportunities for timely diagnosis and management of GS. Patients with thymoma should undergo routine assessments of serum immunoglobulin levels to facilitate the early detection of GS. Immunoglobulin replacement is an effective therapy for managing immunodeficiency-related complications.

REFERENCES

1. Kabir A, Alizadehfar R, Tsoukas CM. Good's Syndrome: Time to Move on From Reviewing The Past. Frontiers In Immunology. 2021; 12: 815710.
2. Tarr PE, Sneller MC, Mechanic LJ, Economides A, Eger CM, Strober W, et al. Infections in patients with immunodeficiency with thymoma (Good syndrome). Report of 5 cases and review of the literature. Medicine 2001; 80(2): 123-33.
3. Kelesidis T, Yang O. Good's Syndrome Remains A Mystery After 55 Years: A Systematic Review of The Scientific Evidence. Clinical Immunology (Orlando, Fla) 2010; 135(3): 347-63.
4. Souadjian JV, Enriquez P, Silverstein MN, Pépin JM. The Spectrum of Diseases Associated with Thymoma. Coincidence or Syndrome? Archives of Internal Medicine 1974; 134(2): 374-9.
5. Jansen A, van Deuren M, Miller J, Litzman J, de Gracia J, Sáenz-Cuesta M, et al. Prognosis of Good Syndrome: Mortality and Morbidity of Thymoma Associated Immunodeficiency In Perspective. Clinical Immunology (Orlando, Fla). 2016;171:12-7.
6. Good R. A gammaglobulinemia-A provocative experiment of nature. Bulletin University Minnesota Hospitals and Minnesota Medical Foundation 1954; 26:1 .
7. Charles RJ, Sabo KM, Kidd PG, Abkowitz JL. The pathophysiology of pure red cell aplasia: implications for therapy. Blood 1996; 87(11): 4831-8.
8. Zaman M, Huissoon A, Buckland M, Patel S, Alachkar H, Edgar JD, et al. Clinical and Laboratory Features of Seventy-eight UK Patients with Good's Syndrome (Thymoma and Hypogammaglobulinaemia). Clinical and Experimental Immunology 2019; 195(1): 132-8.
9. Dong JP, Gao W, Teng GG, Tian Y, Wang HH. Characteristics of Good's Syndrome In China: A Systematic Review. Chinese Medical Journal 2017; 130(13): 1604-9.
10. Velde KT, Huber J, van der Slikke LB. Primary Acquired Hypogammaglobulinemia, Myasthenia, and Thymoma. Annals of Internal Medicine 1966; 65(3): 554-9.

Spotlight on retinoblastoma-related cataracts: A case series

Asma Abdul Razak, MBBS (USIM)[1], Chan Li Yen, MBBS (IMU), MOphthal (UM)[1], Evelyn Tai Li Min, MD (USM), MMed Ophthalmology (USM)[2], Jamalia Rahmat, MBBS (UM), MOphthal (UM)[1]

[1]Department of Ophthalmology, Hospital Kuala Lumpur, Kuala Lumpur, Malaysia, [2]Department of Ophthalmology and Visual Science, School of Medical Sciences, Health Campus, Universiti Sains Malaysia, Kubang Kerian, Kelantan, Malaysia

SUMMARY

Retinoblastoma is the most common primary intraocular malignancy in children, accounting for approximately 4% of all childhood cancers. While cataracts may rarely present as a direct manifestation of advanced disease, they are more frequently associated with treatment-related factors. Historically, cataract formation has been reported after external beam radiotherapy. However, cataracts continue to be reported with modern targeted chemotherapy. This case series describes three pediatric patients with bilateral retinoblastoma complicated by cataract formation. These cases illustrate the diverse mechanisms of cataract development and highlight the challenges posed by the timing of cataract surgery, tumor surveillance, and long-term visual outcomes.

INTRODUCTION

Retinoblastoma (RB) is the most common primary intraocular malignancy in children.[1] Recent advances in RB management have shifted treatment towards globe-salvaging approaches, including systemic, intra-arterial, and intravitreal chemotherapy.[2] Despite these advances, cataract formation may occur either as a manifestation of advanced disease or as a treatment-related complication, complicating tumor surveillance and visual rehabilitation.[3] This case series describes three pediatric patients with retinoblastoma complicated by cataract formation arising from distinct mechanisms.

METHODS

This retrospective case series included three pediatric patients with retinoblastoma and associated cataracts who were managed at Hospital Kuala Lumpur between 2010 and 2016. Clinical data were obtained through a retrospective review of medical records and follow-up examinations. Information on demographic and tumor characteristics, treatment history, surgical outcomes, visual acuity, and postoperative complications was collected, with follow-up data available up to 2025.

CASE PRESENTATION

The following cases demonstrate cataract formation in RB resulting from distinct mechanisms, including tumor-related factors and treatment-associated complications in the context of targeted chemotherapy.

Case 1

Bilateral RB was diagnosed at 18 months of age. According to the International Intraocular Retinoblastoma Classification (IIRC), the right eye (RE) was classified as Group E and the left eye (LE) as Group D. At presentation, a central lens opacity was observed in the LE. The RE underwent primary enucleation. The LE received focal therapy, including laser photocoagulation and cryotherapy; seven sessions of intra-arterial chemotherapy (IAC) with melphalan; and six cycles of systemic chemotherapy with carboplatin, vincristine, and etoposide (JOE regimen) administered at three-week intervals. During treatment, the cataract in the LE progressed to a white cataract, which prevented adequate tumor surveillance. Formal visual acuity (VA) assessment was not feasible due to the patient's age; the LE exhibited only light perception, poor visual behavior, absence of object fixation, and no red reflex. Intravitreal chemotherapy (IVitC) with melphalan (20 µg/0.1 mL) was administered to control the tumor seeds. Lens aspiration with intraocular lens (IOL) implantation was performed three weeks after the initial IVitC melphalan injection. Six additional postoperative IVitC melphalan injections (20 µg/0.1 mL) were administered at two-to three-week intervals to minimize the risk of tumor dissemination. Following surgery, visual behavior improved, with the child able to fixate and follow light, demonstrate object-directed visual responses, and exhibit a faint red reflex. Despite further laser photocoagulation, cryotherapy, three additional cycles of JOE chemotherapy, and external beam radiotherapy (EBRT) (40 Gy in 20 fractions), the progressive disease persisted. Enucleation of the LE was performed 10 months after the cataract surgery. The patient remained clinically stable, with no evidence of systemic disease.

Case 2

Case 2 was diagnosed with bilateral RB at 3 months of age, with Group B disease in the RE and Group C disease in the LE. She underwent six cycles of systemic chemotherapy (JOE regimen) at three-week intervals, together with focal therapy, comprising laser photocoagulation and cryotherapy. Despite initial tumor regression, new lesions developed in the LE, resulting in progression to Group E disease. As the parents declined enucleation, additional treatment was administered over subsequent visits and examination under anesthesia

This article was accepted: 22 June 2026
Corresponding Author: Evelyn Tai Li Min
Email: evelyn@usm.my

Table I: Clinical Characteristics and Treatment Overview.

Patient	Age at RB Diagnosis	RB Group	Interval of cataract diagnosis from RB diagnosis	Interval of cataract onset from last treatment	Interval of cataract surgery from last treatment	Systemic chemo-therapy (Y/N)	IAC Melphalan (Y/N)	IVitC Melphalan (Y/N)	VA (Pre-cataract operation)	VA (Post-cataract operation)	Proposed mechanism of cataract formation
1	17 months	D	-	-	3 weeks	Y	Y	Y	PL (No object fixation)	(Able to fixate and follow light, object-directed visual response)	Tumour-associated cataract (present at diagnosis)
2	3 months	C	42 months	15 months	19 months	Y	Y	Y	PL	2/60	Treatment-associated cataract (following prolonged multimodal globe-sparing therapy)
3	7 months	D	67 months	7 months	3 weeks	Y	Y	Y	6/120	6/76	Treatment-associated cataract (following prolonged multimodal globe-sparing therapy, possible iatrogenic lens injury)



Fig. 1: (A) Case 1: Cataract obstructing the fundus view in the LE. (B) Case 1: Clearer fundus view following lens aspiration. (C) Case 2: Central lens opacification in the LE, which progressed to a white cataract

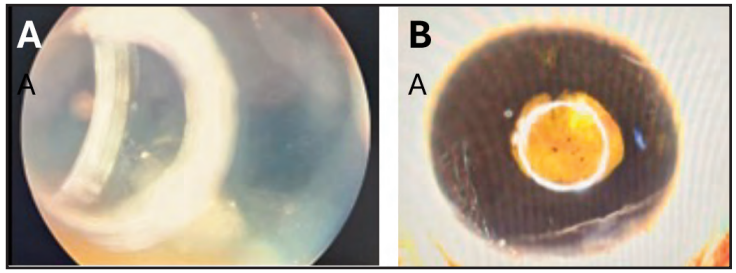

Fig. 2: (Case 3) (A) Cataract obscuring posterior segment view. (B) Progression to white cataract obstructing fundus view

(EUA) sessions, including three further cycles of JOE chemotherapy. Globe-salvage treatment for LE comprised two sessions of IAC melphalan (5 mg/30 mL), intracameral topotecan (7.5 µg/0.015 mL), and one IVitC melphalan injection (20 µg/0.1 mL). The LE remained free of tumor recurrence on surveillance; however, a mild cataract developed approximately 15 months after the last intravitreal injection and subsequently progressed to a mature white cataract, limiting fundus examination. Preoperative VA was perception of light in the LE and 6/38 in the RE. Lens aspiration with IOL implantation improved LE vision to 2/60. Two years later, vision declined to counting fingers (CF) due to posterior capsular opacification (PCO), and surgical capsulotomy was performed. Final VA remained 2/60, with no evidence of tumor recurrence 5 years after cataract surgery.

Case 3

Case 3 was diagnosed with bilateral RB at 7 months of age, with Group E disease in the RE and Group D disease in the LE. The RE underwent primary enucleation, whereas the LE was managed with globe-sparing therapies. The patient completed nine cycles of the JOE chemotherapy regimen, together with focal therapy comprising laser photocoagulation and cryotherapy. Recurrent vitreous seeding in the LE was treated over multiple sessions with 14 IVitC melphalan injections (20 µg/0.1 mL) and one IAC melphalan injection. Six years after diagnosis, five years after completion of systemic chemotherapy, and seven months after the final IVitC melphalan injection, the patient developed a LE cataract. Examination revealed a posterior subcapsular opacity with cortical wedge opacity and anterior capsular wrinkling, raising the possibility of an iatrogenic lens injury from repeated intravitreal injections. Progressive cataract formation necessitated lens aspiration with intraocular lens implantation to allow tumor surveillance; two IVitC melphalan injections (20 µg/0.1 mL) were administered before surgery for ocular priming. Postoperatively, the best-corrected VA improved from 6/120 to 6/76. Four years later, vision declined to CF due to dense PCO and was successfully treated with Nd:YAG capsulotomy, resulting in an improvement in VA to 2/60, which remained stable for several years after. During subsequent follow-ups, VA progressively deteriorated to CF due to treatment-related posterior segment changes. Fundus examination revealed mixed calcific regression and scarring, with no evidence of tumor recurrence.

DISCUSSION

Cataract formation in patients with RB is a multifactorial complication that may occur as a direct manifestation of advanced intraocular disease, reported in approximately 0.25% of cases, or as a delayed consequence of treatment.[3] Although cataracts have historically been most associated with EBRT, the increasing use of globe-sparing modalities such as systemic chemotherapy, IAC, and IVitC has altered patterns of cataract development. This case series presents three distinct mechanisms of cataract formation in RB and highlights the complexity of management decisions regarding the timing of cataract surgery, tumor surveillance, and long-term visual outcomes.

Historically, cataracts have been a well-recognized late complication of EBRT for RB, with a reported incidence as high as 71.7%, particularly with higher radiation doses and younger age at exposure.[3] Radiation-induced cataracts are typically posterior subcapsular in morphology and may progress gradually over time. With the decline in EBRT use following the advent of chemoreduction and targeted chemotherapy delivery, radiotherapy-related cataracts have become less frequent in recent years. However, as demonstrated in this series, cataract formation remains a clinically relevant issue in the modern treatment era, occurring in approximately 16.8% of eyes undergoing eye-preservation therapy, even in the absence of or before radiotherapy.[4]

In Case 1, cataracts were present at diagnosis and progressed rapidly during treatment. Cataracts as a presenting feature of RB are rare and typically associated with advanced disease.[3-4] Proposed mechanisms include tumor-related inflammation, exudation, ischemia, or direct invasion of adjacent ocular structures, all of which may disrupt lens metabolism.[3] In this case, early cataract progression significantly limited tumor visualization, complicating surveillance and treatment assessment. Although cataract extraction was performed to restore fundus visualization, the disease continued to progress despite aggressive multimodal therapy, ultimately necessitating enucleation. This case demonstrates the challenge of managing cataracts in eyes with an active, advanced intraocular tumor burden, where surgical intervention may be required primarily for diagnostic or surveillance purposes rather than for visual rehabilitation.

Cases 2 and 3 demonstrate cataract development as a delayed complication of RB treatment. Both patients received prolonged globe-sparing therapy involving systemic chemotherapy, IAC, and IVitC, with cataracts developing months to years after the completion of active treatment. Although systemic chemotherapy alone has not been strongly implicated in cataractogenesis, repeated intraocular interventions and local drug toxicity may contribute to lens changes.[4] IVitC melphalan has been associated with anterior segment toxicity, including iris atrophy, hypotony, and cataract formation.[2] Mechanical lens injury during intravitreal injection is also a recognized risk.[2] Previous studies have identified a greater number of IVitC cycles as a risk factor for cataract formation following retinoblastoma treatment.[4] These findings are consistent with those of Cases 2 and 3, in which cataracts developed following prolonged treatment incorporating IVitC.

In Case 3, clinical examination identified a posterior subcapsular cataract with associated cortical wedge opacity and anterior capsular wrinkling; findings that suggested iatrogenic lens trauma from repeated intravitreal injections. This observation supports the hypothesis that both mechanical injury and cumulative drug toxicity contribute to cataract development following IVitC.[2,4] The cataract developed several years after the initial diagnosis and months after the final intravitreal injection, indicating delayed presentation. This latency highlights the importance of long-term surveillance for anterior segment complications in RB survivors. The morphological features observed in Case 3 were consistent with previous reports of injection-related

lens injury, further supporting the role of injection in cataract formation.

The timing of cataract surgery in eyes previously treated for retinoblastoma (RB) remains a subject of debate. Historically, cataract extraction was avoided because of concerns regarding tumor dissemination and metastatic risk. However, recent evidence indicates that cataract surgery can be performed safely in selected cases, provided the tumor has remained inactive for an adequate interval and appropriate precautions are implemented.[9] Even in eyes with documented tumor regression, a minimum observation interval of six months prior to intraocular surgery has been recommended.[5] In this series, cataract surgery was undertaken primarily to restore tumor surveillance rather than to optimize VA. Preoperative IVitC was administered in cases 1 and 3 to prime the eye and reduce the theoretical risk of tumor dissemination, a strategy increasingly accepted in current practice.[7]

Although cataract surgery was technically successful, the visual outcomes in this series were limited. In Case 2, visual improvement was modest and subsequently compromised by PCO, a common complication of pediatric cataract surgery. Similarly, Case 3 developed dense PCO several years postoperatively, necessitating Nd: YAG capsulotomy. These findings reflect the cumulative effects of amblyopia, retinal damage from the tumor and treatment, and anterior segment complications on visual prognosis.[9] Visual outcomes should be interpreted with caution in RB survivors, as preservation of life and globe frequently takes precedence over visual rehabilitation.

From an oncological perspective, none of the eyes that underwent cataract surgery for tumor surveillance demonstrated recurrence attributable to surgical intervention. This observation supports the accumulating evidence that cataract extraction, when carefully timed and performed in controlled settings, does not increase the risk of tumor recurrence. Stringent patient selection, multidisciplinary decision-making, and long-term follow-up are essential.

This case series was limited by its retrospective design and small sample size. Nevertheless, it provides valuable insights into the heterogeneous pathways leading to cataract formation in RB and highlights practical considerations for management. The variability in etiology, timing of presentation, and outcomes underscores the importance of individualized care and long-term surveillance in this population.

In conclusion, cataract formation in RB may result from tumor-related factors, treatment toxicity, or iatrogenic injury. Despite advances in targeted chemotherapy, cataracts remain a significant complication that can impair tumor surveillance and visual outcomes. Cataract surgery can be safely performed in selected cases with appropriate precautions, primarily to facilitate ongoing monitoring. Awareness of the diverse mechanisms and long-term implications of cataract development is essential for optimizing care in children with RB.

REFERENCES

1. Kaur K, Patel BC. Retinoblastoma. In: StatPearls [Internet]. Treasure Island (FL): StatPearls Publishing; 2025. Available from: https://www.ncbi.nlm.nih.gov/books/NBK545276/.
2. Francis JH, Marr BP, Brodie SE, Abramson DH. Anterior ocular toxicity of intravitreous melphalan for retinoblastoma. JAMA Ophthalmol. 2015; 133(12): 1459-63.
3. Balasubramanya R, Pushker N, Bajaj MS, Ghose S, Kashyap S, Rani A. Atypical presentations of retinoblastoma. J Pediatr Ophthalmol Strabismus 2004; 41(1): 18-24.
4. Jia S, Wen X, Yu J, Zhou M, Yang L, Feng Y, et al. Risk factors for cataract in retinoblastoma management. Br J Ophthalmol 2024; 108(4): 571-7.
5. Honavar SG, Shields CL, Shields JA, Demirci H, Naduvilath TJ. Intraocular surgery after treatment of retinoblastoma. Arch Ophthalmol 2001; 119(11): 1613-21.

Not every chronic cough is tuberculosis: Congenital diaphragmatic hernia mimicking active tb in an indigenous patient — a diagnostic dilemma in primary care

Hezlin Md Zin, Zahidatul Husna Ali, Siti Maryam Mohd Sallehuddin

Rengit Health Clinic, Johor, Malaysia

SUMMARY

Tuberculosis (TB) continues to disproportionately affect the indigenous Orang Asli population in Malaysia, often presenting diagnostic challenges in primary care settings. We report a case of a 59-year-old Orang Asli man identified during targeted community TB screening following multiple TB-related deaths in Kampung Bumiputera Dalam, Rengit, Malaysia. Although asymptomatic at the initial screening, he demonstrated strong Mantoux positivity and abnormal chest radiography findings. Delayed follow-up revealed persistent cough, raising concerns about active pulmonary tuberculosis. However, repeated sputum microbiological investigations, including GeneXpert MTB/RIF, were negative, and the radiological findings remained stable. Radiological reassessment revealed an incidental congenital diaphragmatic hernia, providing an alternative explanation for the symptoms. Following a multidisciplinary discussion, a diagnosis of latent tuberculosis infection (LTBI) was made. The patient completed a three-month rifampicin-isoniazid regimen despite temporary treatment interruption. This case highlights the importance of correlating microbiological evidence with radiological findings in TB-endemic settings and maintaining a broad differential diagnosis to avoid unnecessary treatment. This underscores the central role of family medicine in balancing disease containment with accurate patient-centered care in vulnerable Indigenous populations.

INTRODUCTION

Tuberculosis remains a significant public health concern in Malaysia, especially among Orang Asli communities, where socioeconomic vulnerability, geographic isolation, and limited healthcare access challenge early diagnosis of the disease.[1] Community-based TB screening programs are vital, fostering a sense of shared responsibility and collective effort to improve health outcomes in high-risk populations.[2]

In TB-endemic settings, clinical decision-making should consider a broad differential diagnosis to avoid overreliance on pre-test probability and public health considerations, which can lead to unnecessary treatment and anxiety. Delivering comprehensive Tuberculosis Awareness among indigenous communities is important to facilitate early preventive and targeted treatment of the disease. However, community resistance and communication barriers limit these opportunities.[2] Recognizing non-tuberculous conditions that mimic pulmonary TB helps clinicians feel assured of their thorough evaluation. As latent tuberculosis cases increase, the need to start preventive treatment earlier may reduce the risk of active tuberculosis progression by approximately 5 to 10 %.[3]

Congenital diaphragmatic hernia (CDH) is typically identified in infancy, and its presentation in adults is uncommon.[4] When present, displacement of the abdominal contents into the thoracic cavity may contribute to gastrointestinal reflux and chronic cough, creating a clinical picture that overlaps with pulmonary disease. Recognition of such atypical presentations is particularly important in primary care settings, where initial diagnostic pathways are established.

We present a case of an Orang Asli patient with a persistent cough and chest radiographic abnormalities initially suggestive of pulmonary TB but ultimately diagnosed with congenital diaphragmatic hernia. This dilemma stirs primary care anxiety with the urgency to treat the active disease while simultaneously establishing the correct diagnosis. This case highlights the diagnostic challenges faced by family physicians in tuberculosis-endemic communities. This underscores the importance of maintaining a broad differential diagnosis when molecular testing does not support an active infection.

CASE PRESENTATION

A 59-year-old Orang Asli man from Kampung Bumiputera Dalam, Rengit, with no known medical illness, underwent targeted TB mass screening on May 27, 2025, following several TB-related deaths within the community. At screening, the patient was asymptomatic, without cough, fever, weight loss, or constitutional symptoms. The Mantoux test demonstrated a 20 mm induration. A chest radiograph performed on the same date showed blunting of the right costophrenic angle, which was suggestive of pleural effusion or pleural thickening.

The patient presented late for follow-up at Klinik Kesihatan Rengit on July 25, 2025, complaining of a persistent cough for approximately three weeks. Investigations revealed sputum AFB smear ×3 negative, sputum culture with no

This article was accepted: 22 June 2026
Corresponding Author: Hezlin MD Zin
Email: hezlinlove@gmail.com



Fig. 1: Chest X-ray PA view taken on 11.8.2025.

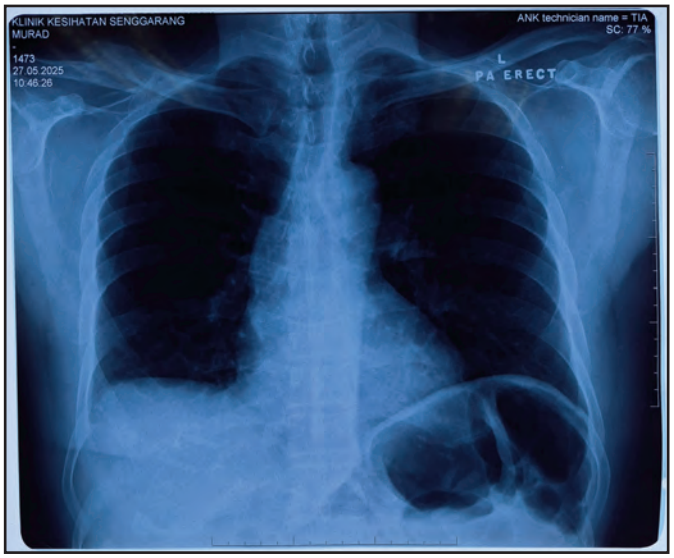

Fig. 2: Chest X-ray PA view taken on 27.5.2025.

growth, and an ESR of 5 mm/hr. The patient was subjected to a chest X-ray at a nearby health clinic with an available radiology unit, and serial chest radiographs (in May and August 2025) demonstrated persistent right costophrenic angle blunting with an incidental left congenital diaphragmatic hernia.

Given the ongoing symptoms and radiographic abnormalities, GeneXpert MTB/RIF testing was performed, and a multidisciplinary discussion with a respiratory physician was conducted. This collaborative approach aims to build confidence in diagnosis and ensure comprehensive patient care.

Considering the strong Mantoux reactivity, epidemiological exposure, stable radiographic findings, and absence of microbiological evidence of active disease, a diagnosis of latent tuberculosis infection was made. The patient commenced treatment with Akurit-2 tablets on August 15, 2025, for a planned three-month regimen. Treatment was interrupted due to default for approximately one month but was restarted on October 22, 2025, and completed on January 22, 2026.

The patient was concurrently managed at Klinik Kesihatan Rengit under the care of a Family Medicine Specialist for latent tuberculosis infection (LTBI). He completed the prescribed LTBI treatment and remained compliant with scheduled follow-up visits at 3, 6, 9 months, 1 year after treatment initiation.

The incidental finding of a left congenital diaphragmatic hernia on serial chest radiography was reviewed and discussed with both the radiologist and respiratory physician. Following counselling regarding the diagnosis, potential complications, and available management options, the patient declined further investigations, specialist referral, or surgical intervention. He was asymptomatic and had lived comfortably with the condition for many years without any perceived impact on his daily activities or overall health. In addition, transportation difficulties posed a significant barrier, as the referral hospital was located approximately 45 km from his residence in Rengit.

Given the patient's informed decision, absence of symptoms, and stable clinical condition, no surgical referral was made at that time. The patient was advised on symptoms that would warrant immediate medical attention and continued primary care follow-up.

DISCUSSION

This case illustrates the diagnostic challenges encountered when assessing tuberculosis in high-risk Indigenous populations identified through community screening. Strong Mantoux reactivity and abnormal chest radiography in a TB-affected community naturally raise concerns regarding active disease; however, microbiological confirmation remains essential to avoid unnecessary treatment. Negative sputum AFB smears, negative GeneXpert MTB/RIF results, low inflammatory markers, and the absence of constitutional symptoms increase diagnostic confidence that active TB is unlikely, guiding clinicians toward appropriate management strategies.

The incidental finding of congenital diaphragmatic hernia provided a plausible alternative explanation for chronic cough, likely related to gastroesophageal reflux or gastric content irritation. Structural thoracic abnormalities, such as congenital diaphragmatic hernia, should be considered in

the differential diagnosis when respiratory symptoms persist despite negative microbiological tests, especially in TB-endemic regions where clinical suspicion is high. Recognizing these conditions can prevent misdiagnosis and unnecessary antituberculous therapy.[5]

Chronic cough is one of the most common presenting complaints encountered in primary care and frequently prompts evaluation for pulmonary tuberculosis (TB), particularly in endemic regions and among under-served populations.[6] As the indigenous population carries a higher risk of tuberculosis infection, detailed screening with a holistic approach needs to be carried out simultaneously, while the team faced difficult challenges in poor awareness and community barriers.[7] In Malaysia, primary care clinicians often face the challenge of balancing early TB detection with the risk of overdiagnosis, especially when symptoms and chest radiography findings are nonspecific. Diagnostic uncertainty may arise when radiological abnormalities, such as pleural thickening, coexist with persistent respiratory symptoms, and microbiological investigations remain negative. Pleural thickening is non-specific and may lead to overinterpretation of the disease, which can be caused by malignancy or benign processes.[8]

Differentiating latent tuberculosis infection (LTBI) from active pulmonary tuberculosis remains challenging in endemic settings, particularly within high-risk indigenous populations.[9] In this case, strong Mantoux reactivity and abnormal chest radiography in the context of recent TB-related deaths heightened suspicion for active disease. However, repeated negative sputum AFB smears, negative GeneXpert MTB/RIF results, absence of constitutional symptoms, low inflammatory markers, and stable radiographic findings reduced the likelihood of active pulmonary tuberculosis diagnosis. Epidemiological risk alone should not supersede microbiological evidence, as diagnostic anchoring may lead to overtreatment and an increase in the incidence of multidrug-resistant tuberculosis.

Tuberculosis screening among Orang Asli communities requires pragmatic diagnostic approaches that consider stigma, mobility barriers, and high default rates. Although the Mantoux test is inexpensive, the completion of the 72-hour reading is often unreliable despite active outreach efforts. Fear, stigma, and avoidance behavior may limit engagement, even when healthcare teams visit the community directly. Single-encounter investigations, such as interferon-gamma release assays (IGRAs), may offer practical advantages despite their higher cost, particularly in populations with poor follow-up adherence.[10]

In this patient, sputum AFB smears were negative despite radiographic abnormalities suggestive of pleural pathology, creating uncertainty regarding the diagnosis of active tuberculosis. GeneXpert MTB/RIF was used to facilitate rapid molecular assessment. While mycobacterial culture remains the diagnostic gold standard, its prolonged turnaround time limits immediate clinical decision-making in community-based primary care settings. The combined use of IGRA and GeneXpert represents a context-adapted strategy that balances diagnostic accuracy with operational feasibility in remote indigenous settings.

The incidental congenital diaphragmatic hernia provided a plausible non-infective explanation for the persistent cough, which was likely related to gastric content irritation or reflux. Hence, a basic chest radiograph is mandatory in health clinics for screening chronic cough. The rare incidence of adult congenital diaphragmatic hernia, at 0.17%-0.20% in the population, may not be the first diagnosis in a patient presenting with a chronic cough.[4] Structural thoracic abnormalities that contribute to gastric irritation may mimic pulmonary tuberculosis symptoms, such as persistent cough, which may cause a dilemma in diagnosing active tuberculosis in high-risk groups. Multidisciplinary consultation is essential for refining the diagnosis and avoiding unnecessary multidrug therapy.

Primary care clinicians working in rural settings frequently encounter diagnostic uncertainties when managing tuberculosis among high-risk Indigenous populations. Limited access to advanced imaging, delayed laboratory turnaround times, and challenges in patient follow-up require family medicine practitioners to balance public health priorities with individualized clinical judgement. In this case, the need to differentiate latent tuberculosis infection from active pulmonary disease was particularly important, as both undertreatment and overtreatment have significant consequences in communities experiencing ongoing transmission and TB-related mortality.

While tuberculosis remains a key consideration in symptomatic individuals from high-risk populations, clinicians must maintain a broad differential diagnosis for such cases. The incidental finding of congenital diaphragmatic hernia in this patient highlights the importance of evaluating the structural and non-infectious causes of respiratory symptoms. A holistic assessment reduces the risk of diagnostic bias and supports safer and more accurate clinical decision-making.

In conclusion, this case highlights the diagnostic complexity of evaluating chronic cough in tuberculosis-endemic primary care settings, where heightened clinical suspicion must be carefully balanced against the consideration of alternative diagnoses. Radiological abnormalities, such as pleural thickening, may be misleading when interpreted in isolation, particularly when molecular investigations do not support active infection. Recognition of uncommon structural conditions, including congenital diaphragmatic hernia, is essential to prevent unnecessary anti-tuberculosis treatment and ensure patient-centered care. Differentiating latent tuberculosis infection from active disease remains particularly challenging among high-risk Orang Asli populations, where epidemiological risk may inadvertently contribute to stigma or over-medicalization if not guided by objective clinical and microbiological evidence.

Continuity of care and structured follow-up imaging were critical in this case, allowing radiological stability to be recognized and supporting a diagnosis of latent rather than active tuberculosis. In resource-limited rural environments, family physicians play a pivotal role in coordinating culturally sensitive evidence-based care, integrating multidisciplinary input, and adapting diagnostic strategies to local realities. Strengthening clinical reasoning while

maintaining a broad differential diagnosis is essential for achieving accurate treatment decisions, sustaining patient trust, and supporting effective tuberculosis containment within vulnerable indigenous communities.

REFERENCES

1. An Y, Teo AKJ, Huot CY, Tieng S, Khun KE, Pheng SH, et al. Barriers to childhood tuberculosis case detection and management in Cambodia: the perspectives of healthcare providers and caregivers. BMC Infect Dis 2023; 23(1).
2. Zawedde-Muyanja S, Manabe YC, Cattamanchi A, Castelnuovo B, Katamba A. Patient and health system level barriers to and facilitators for tuberculosis treatment initiation in Uganda: a qualitative study. BMC Health Serv Res 2022; 22(1).
3. Ilievska-Poposka B, Metodieva M, Zakoska M, Vragoterova C, Trajkov D. Latent tuberculosis infection - Diagnosis and treatment. Open Access Maced J Med Sci 2018; 6(4): 651-5.
4. Hietaniemi H, Järvinen T, Ilonen I, Räsänen J. Congenital diaphragmatic hernia in adults: a decade of experience from a single tertiary center. Scand J Gastroenterol. 2022; 57(11): 1291-5.
5. Telisinghe L, Ruperez M, Amofa-Sekyi M, Mwenge L, Mainga T, Kumar R, et al. Does tuberculosis screening improve individual outcomes? A systematic review. EClinicalMedicine 2021; 40.
6. Domingo C, Gonzálvez J, Dávila I, del Cuvillo A, Sánchez-Jareño M, Cea-Calvo L, et al. Basic assessment of chronic cough in primary care and referral pathways of patients to different specialists. Ther Adv Respir Dis 2023; 17.
7. Mahmud MH, Baharudin UM, Md Isa Z. Diseases among the Orang Asli community in Malaysia: a systematic review. BMC Public Health 2022; 22(1).
8. Lee GM, Walker CM. Pleural Thickening: Detection, Characterization, and Differential Diagnosis. Semin Roentgenol. 2023; 58(4): 399-410.
9. Chumpa N, Kawkitinarong K, Wongpiyabovorn J, Paitoonpong L, Suwanpimolkul G. Prevalence of latent tuberculosis infection among pre-clinical and clinical medical students using QuantiFERON-TB gold plus and tuberculin skin test at a teaching hospital in Thailand: A cross-sectional study. J Infect Public Health 2022; 15(4): 400-5.
10. Allen V, Galloway J. Commentary on: diagnostic accuracy and predictive value of the QuantiFERON-TB Gold Plus assay for tuberculosis in immunocompromised individuals: a prospective TBnet study. Vol. 57, The Lancet Regional Health - Europe. Elsevier Ltd; 2025.

From unresectable to curative resection: Conversion surgery for metastatic oesophagogastric junction gastrointestinal stromal tumour after systemic tyrosine kinase inhibitor therapy

Choon Hui Gan[1,2,3], Kelvin Voon[1], Ikhwan Sani Mohamad[2,3], Premnath Nagalingam[4]

[1]Department of General Surgery, Penang General Hospital, Penang, Malaysia, [2]Hospital Universiti Sains Malaysia, Kelantan Malaysia, [3]Department of General Surgery, School of Medical Sciences, Universiti Sains Malaysia, Kelantan Malaysia, [4]Royal College of Surgeons in Ireland and University College Dublin Malaysia Campus, Penang, Malaysia

SUMMARY

Introduction: Gastrointestinal stromal tumours (GISTs) are the most common mesenchymal tumors of the gastrointestinal tract, with the stomach being the predominant site of origin. The liver is the most common site of metastatic spread. The optimal management of oesophagogastric junction (OGJ) GISTs with synchronous liver metastases remains controversial, particularly regarding the role of surgery following systemic therapy. We report a case of metastatic OGJ GIST successfully managed using a multidisciplinary treatment strategy that combined systemic tyrosine kinase inhibitor (TKI) therapy and conversion surgery. Case Presentation: A 39-year-old woman presented with progressive dysphagia, weight loss, and anemia. Imaging revealed a large 20×20 cm OGJ tumor with diaphragmatic involvement and two metastatic liver lesions in segments VI and VII. Histopathological examination confirmed the diagnosis of metastatic GIST. Following multidisciplinary team discussion, systemic TKI therapy was initiated. After six months of treatment, serial CT and PET-CT demonstrated marked radiological and metabolic responses, with significant regression of the primary tumor and complete resolution of FDG avidity in the liver metastases. Considering the favorable treatment response, the patient underwent curative-intent surgery, which included proximal gastrectomy with double tract reconstruction (DTR) and liver metastasectomy. Complete (R0) resection was achieved, and the patient had an uneventful postoperative recovery period. Conclusion: Selected patients with metastatic OGJ GIST who demonstrate a favorable response to systemic TKI therapy may benefit from conversion surgery with curative intent. Proximal gastrectomy with DTR offers the additional advantage of preserving gastrointestinal function while maintaining satisfactory nutritional outcomes.

INTRODUCTION

Gastrointestinal stromal tumours (GISTs) are the most common mesenchymal neoplasms of the gastrointestinal tract, with the stomach being the predominant site of origin. Although GISTs account for only 1–3% of all gastrointestinal malignancies, they represent the majority of gastrointestinal mesenchymal tumors. The liver and peritoneum are the most frequent sites of metastatic spread.[1-2]

GISTs are characterized by activating mutations involving the receptor tyrosine kinases, KIT or platelet-derived growth factor receptor alpha (PDGFRA), resulting in constitutive activation of tyrosine kinase signalling pathways that drive tumor growth and progression.[3-5] Surgical resection remains the cornerstone of treatment for localized disease. However, the introduction of tyrosine kinase inhibitors (TKIs) has dramatically altered the management and prognosis of patients with locally advanced and metastatic GIST.[5-6]

The optimal management of metastatic GIST, particularly in patients with synchronous liver metastases, remains controversial, and there is currently no clear consensus regarding the role of surgery following systemic therapy. We report a case of a large oesophagogastric junction (OGJ) GIST with synchronous liver metastases that was successfully managed using a multidisciplinary approach comprising systemic TKI therapy, followed by conversion surgery with proximal gastrectomy, double-tract reconstruction, and liver metastasectomy.

CASE PRESENTATION

A 39-year-old woman presented with progressive dysphagia, significant weight loss, and iron deficiency anemia. Physical examination revealed a large, firm epigastric mass extending into the left upper abdomen of the patient. Upper gastrointestinal endoscopy revealed a large submucosal tumor arising from the oesophagogastric junction (OGJ), with central ulceration causing significant luminal narrowing.

Contrast-enhanced computed tomography (CT) revealed a large heterogeneous mass measuring approximately 15 × 20 × 20 cm, arising from the gastric cardia and OGJ, with extension to the left hemidiaphragm. Two metastatic lesions were identified in hepatic segments VI and VII (Figure 1A-B). Image-guided core needle biopsies obtained from both the primary tumor and liver lesions confirmed the diagnosis of metastatic gastrointestinal stromal tumour (GIST).

This article was accepted: 24 June 2026
Corresponding Author: Ikhwan Sani Mohamad
Email: ikhwansani@yahoo.com.my

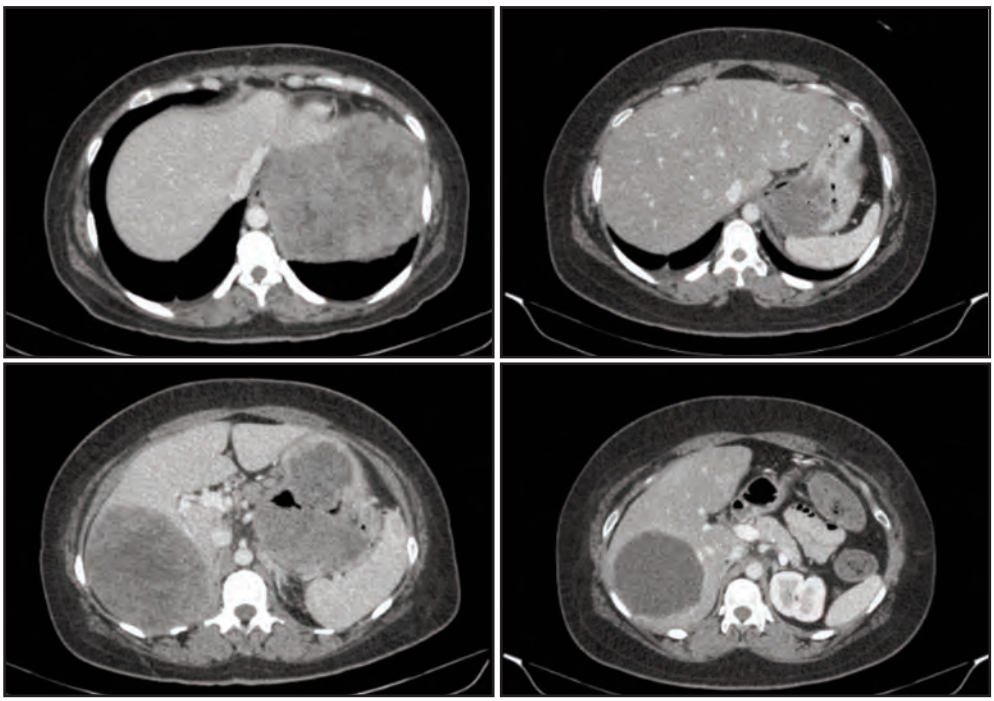

Fig. 1: (A) Large heterogenous COJ GIST (yellow arrow) with infiltration to the left hemidiaphragm; (B) Large segment 6 & 7 liver metastases (red arrow) Stomach GIST; (C) Significant reduction in tumour size 6 months after imatinib therapy; (D) Reduction in liver lesion size with hypodensity after imatinib therapy

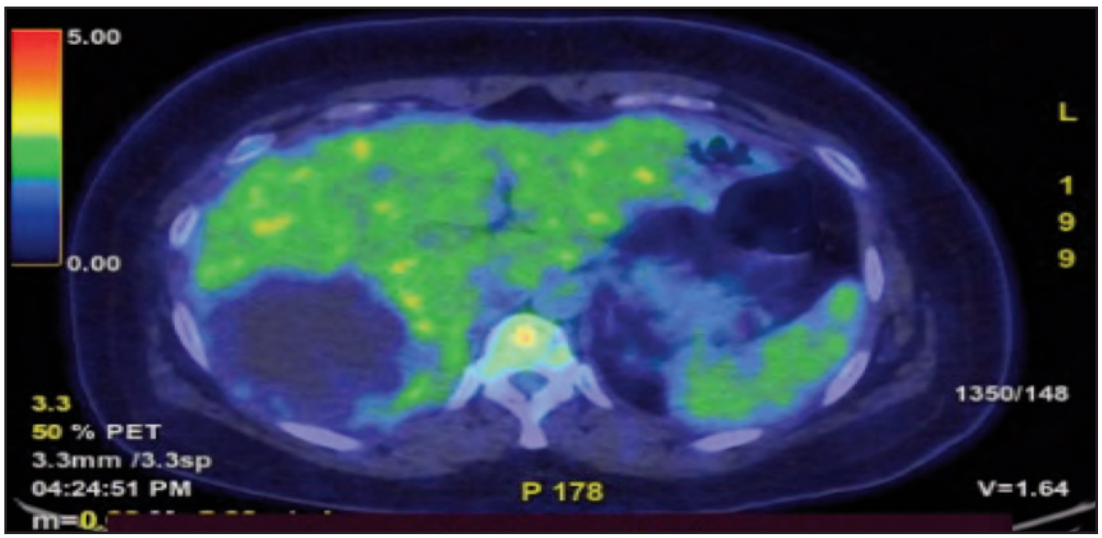

Fig. 2: PET scan showed residual COJ tumour with increased FDG uptake (yellow arrow) & non-FDG avid liver lesions 6 months after imatinib therapy (red arrow), consistent with of partial tumour response

Histopathological examination revealed a spindle cell subtype GIST. Immunohistochemical analysis demonstrated strong diffuse positivity for CD117 (c-KIT) and DOG1, whereas staining for SMA and S100 was negative. Molecular mutational analysis was not performed in this case.

The case was reviewed by a multidisciplinary tumor board comprising upper gastrointestinal surgeons, hepatobiliary surgeons, medical oncologists, radiologists, pathologists, and nuclear medicine specialists. In view of the locally advanced primary tumor and synchronous liver metastases, systemic tyrosine kinase inhibitor (TKI) therapy was initiated as the first-line treatment.

The patient commenced oral TKI therapy(oral imatinib 400 mg OD) at a standard daily dose and tolerated the treatment well, experiencing only mild transient periorbital edema that did not require dose modification. Serial radiological assessment with contrast-enhanced CT demonstrated a substantial reduction in the tumor size and vascularity of both the primary lesion and hepatic metastases (Figure 1C-D). Subsequent PET-CT performed after six months of treatment demonstrated a marked metabolic response, with complete resolution of FDG uptake within the liver metastases and no FDG-avid disease outside the primary OGJ tumor (Figure 2).

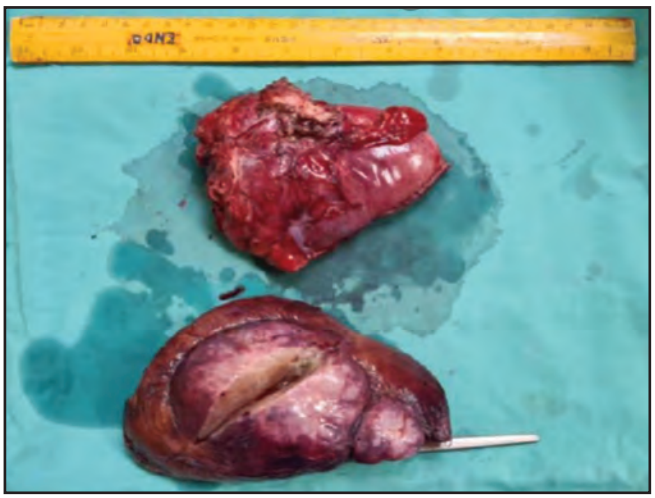

Fig. 3: Proximal gastrectomy (yellow arrow) & non-anatomical resection of right liver metastatic lesions (red arrow)

Following a repeat multidisciplinary review, the patient was considered suitable for conversion surgery with curative intent because of the favorable radiological and metabolic response to systemic therapy and the feasibility of achieving complete tumor clearance.

At laparotomy, no evidence of peritoneal dissemination or extrahepatic metastatic disease was observed. The primary tumor originated from the OGJ, with limited involvement of the left hemidiaphragm. En bloc resection of the involved diaphragmatic segment was performed while preserving the tumor capsule integrity.

Proximal gastrectomy was performed with preservation of the distal stomach and pylorus. Simultaneously, nonanatomical wedge resections of the segment VI and VII liver metastases were performed to achieve complete clearance of the metastatic disease. Reconstruction was performed using the double-tract reconstruction (DTR) technique, consisting of an oesophagojejunostomy (OJ), gastrojejunostomy (GJ), and jejunojejunostomy (JJ), thereby preserving the continuity of the remnant stomach and duodenal passage. OJ was performed using the side-to-side overlap technique, followed by side-to-side GJ approximately 15 cm from the EJ. The JJ was constructed using the side-to-side approach approximately 20 cm from the GJ. All anastomoses were performed using a linear stapler.

Histopathological examination confirmed complete (R0) resection of both the primary tumor and hepatic metastases, with a marked response to preoperative TKI therapy. The postoperative course was uneventful, and the patient was discharged on the ninth postoperative day. Oral TKI therapy was resumed 1 month postoperatively.

At the year follow-up, the patient remained well, with no evidence of disease recurrence. She resumed normal oral intake, maintained a satisfactory nutritional status, and demonstrated no clinical evidence of anemia or micronutrient deficiency.

DISCUSSION

The introduction of tyrosine kinase inhibitors (TKIs) has revolutionized the management of gastrointestinal stromal tumours (GISTs), particularly in patients with locally advanced or metastatic disease. TKI therapy is currently the standard treatment for metastatic GIST and is widely utilized in the neoadjuvant and adjuvant settings for selected high-risk patients. In addition to achieving tumor control, preoperative TKI therapy may facilitate surgical resection through tumor downsizing, reduction in tumor vascularity, improved tumor capsule integrity, and a lower risk of tumor rupture or intraoperative bleeding, thereby increasing the likelihood of achieving an R0 resection. Furthermore, PET-CT plays an important role in assessing the metabolic response to systemic therapy and aids in selecting appropriate candidates for surgical intervention.

The management of metastatic GIST remains challenging, and there are currently no universally accepted guidelines regarding the role and timing of surgery following response to systemic therapy. Historically, metastatic GIST was considered a palliative condition that was primarily managed with systemic treatment. However, growing evidence suggests that selected patients with oligometastatic disease who demonstrate a favorable and sustained response to TKI therapy may benefit from surgical resection.[7-8] The rationale for this approach is to achieve complete clearance of residual disease before the emergence of secondary TKI resistance, potentially improving progression-free and overall survival.[7-8]

This case highlights the importance of a multidisciplinary team (MDT) approach in the management of advanced GIST. At presentation, the patient had a large oesophagogastric junction (OGJ) GIST with synchronous liver metastases. Following discussion within a multidisciplinary team comprising upper gastrointestinal surgeons, hepatobiliary surgeons, medical oncologists, radiologists, pathologists, and nuclear medicine specialists, systemic TKI therapy was initiated as the first-line treatment. Serial CT and PET-CT assessments demonstrated marked radiological and

metabolic responses, with significant regression of both the primary tumor and liver metastases. According to the Choi criteria, the patient achieved a partial response characterized by significant reduction in tumor size and attenuation.9 Following reassessment, complete resection of all detectable diseases was considered feasible, and conversion surgery with curative intent was performed.

The successful achievement of R0 resection of both the primary tumor and liver metastases supports the role of conversion surgery in carefully selected patients with metastatic GIST responding to systemic therapy. Histopathological examination demonstrated excellent treatment response with minimal residual viable tumor, further supporting the effectiveness of a multimodal treatment strategy combining systemic therapy and surgery.[7-8] Although involving a different sarcoma subtype, Aimanan et al. reported successful multidisciplinary management of metastatic chondroblastic osteosarcoma requiring thoracic endovascular aortic repair, highlighting the importance of individualized surgical decision-making in advanced metastatic sarcoma.[10]

An important aspect of this case was the use of proximal gastrectomy with double tract reconstruction (DTR) as a function-preserving surgical approach. Tumors involving the OGJ often require extensive gastroesophageal resection to achieve adequate oncological margins. Traditionally, Either Ivor Lewis esophagectomy or total gastrectomy has been performed in such cases. However, these procedures are associated with more complex surgical steps and significant long-term nutritional and functional consequences, including reflux symptoms, excessive weight loss, iron deficiency anemia, vitamin B12 deficiency, and impaired quality of life.

Proximal gastrectomy with DTR offers several physiological advantages while maintaining oncological safety. Preservation of the distal stomach maintains gastric reservoir function and contributes to more physiological digestion. double tract reconstruction allows a proportion of the food bolus to pass through the remnant stomach and duodenum, preserving normal digestive physiology and facilitating the absorption of iron and micronutrients. Maintaining duodenal transit may reduce the risk of postoperative anemia and nutritional deficiencies commonly observed following total gastrectomy. In addition, DTR has been shown to reduce reflux symptoms compared to conventional oesophagogastrostomy by minimizing the exposure of the esophagus to gastric contents. In the present case, the patient remained nutritionally well, with no evidence of reflux symptoms or nutritional deficiencies during the early follow-up.

This study has several limitations. First, this study was a single case report, which limits the generalizability of the findings. Second, the follow-up duration remains relatively short, and long-term surveillance is required to determine the durability of oncological control, functional outcomes, and nutritional status. Given the risk of late recurrence and potential development of secondary TKI resistance, prolonged follow-up is essential. Additionally, molecular mutational analysis was unavailable at our institution and therefore could not be performed. As KIT and PDGFRA mutation statuses may influence prognosis and responsiveness to tyrosine kinase inhibitors, the absence of molecular characterization represents a limitation of this report. Finally, larger prospective studies are needed to better define the role of conversion surgery and function-preserving reconstruction in patients with metastatic GIST who respond favorably to systemic therapy.

In conclusion, the management of metastatic OGJ GIST requires a multidisciplinary approach. In selected patients who demonstrate a favorable response to systemic TKI therapy, conversion surgery may enable complete (R0) resection of both the primary tumor and metastatic disease. Proximal gastrectomy with double-tract reconstruction offers the additional benefit of preserving gastric and duodenal function while minimizing reflux and nutritional deficiency. This case highlights the potential role of combining systemic therapy with function-preserving surgery to achieve favorable oncological and functional outcomes.

REFERENCES

1. DeMatteo RP, Lewis JJ, Leung D, Mudan SS, Woodruff JM, Brennan MF. Two hundred gastrointestinal stromal tumors: recurrence patterns and prognostic factors for survival. Ann Surg 2000; 231(1): 51-8.
2. Hirota S, Isozaki K, Moriyama Y, Hashimoto K, Nishida T, Ishiguro S, et al. Gain-of-function mutations of c-kit in human gastrointestinal stromal tumors. Science. 1998; 279(5350): 577-580.
3. Heinrich MC, Corless CL, Duensing A, McGreevey L, Chen CJ, Joseph N, et al. PDGFRA activating mutations in gastrointestinal stromal tumors. Science 2003; 299(5607): 708-10.
4. Corless CL, Fletcher JA, Heinrich MC. Biology of gastrointestinal stromal tumors. J Clin Oncol. 2004;22(18): 3813-25.
5. Demetri GD, von Mehren M, Blanke CD, Van den Abbeele AD, Eisenberg B, Roberts PJ, et al. Efficacy and safety of imatinib mesylate in advanced gastrointestinal stromal tumors. N Engl J Med 2002; 347(7): 472-80.
6. Casali PG, Blay JY, Abecassis N, Bajpai J, Bauer S, Biagini R, et al. Gastrointestinal stromal tumours: ESMO–EURACAN–GENTURIS Clinical Practice Guidelines for diagnosis, treatment and follow-up. Ann Oncol 2022; 33(1): 20-33.
7. Gronchi A, Fiore M, Miselli F, Lagonigro MS, Coco P, Messina A, et al. Surgery of residual disease following molecular-targeted therapy with imatinib mesylate in advanced/metastatic GIST. Ann Surg 2007; 245(3): 341-6.
8. Raut CP, Posner M, Desai J, Morgan JA, George S, Zahrieh D, et al. Surgical management of advanced gastrointestinal stromal tumors after treatment with targeted systemic therapy using kinase inhibitors. J Clin Oncol 2006; 24(15): 2325-31.
9. Choi H, Charnsangavej C, Faria SC, Macapinlac HA, Burgess MA, Patel SR, et al. Correlation of computed tomography and positron emission tomography in patients with metastatic gastrointestinal stromal tumor treated at a single institution with imatinib mesylate: proposal of new computed tomography response criteria. J Clin Oncol 2007; 25(13): 1753-9.
10. Aimanan K, Thiagarajan M, Rookkapan S, Kritpracha B, Hussein H. Metastatic chondroblastic osteosarcoma involving the thoracic aorta managed with thoracic endovascular aortic repair: a case report and tribute. Vasc Specialist Int 2025; 41: 31.

Common yet rare: dengue fever immediately after coronary artery bypass grafting: A case report

Nazurah Badrul Zaman[1], Mohd Zamrin Dimon[1], Mafeitzeral Mamat[2], Engku Naim Engku Mohd Nasir[3], Rasidah Senian[4]

[1]Department of Cardiovascular and Thoracic Surgery, Universiti Teknologi MARA, [2]Department of Anaesthesiology and Critical Care, Sunway Medical Centre Velocity, [3]Department of Anaesthesiology and Critical Care, Universiti Teknologi MARA, [4]Infectious Diseases/Internal Medicine, Sunway Medical Centre Velocity

SUMMARY

Dengue fever occurring in the immediate postoperative period after coronary artery bypass grafting (CABG) presents a clinical dilemma due to risks of thrombocytopenia-related bleeding and graft thrombosis. We report a case of dengue fever shortly after CABG and was successfully managed with temporary cessation of dual antiplatelet therapy (DAPT), careful hemodynamic monitoring, and judicious fluid management. This case highlights the importance of early recognition and individualised decision-making in dengue-endemic regions.

CASE PRESENTATION

A 45-year-old man with hypertension, diabetes mellitus and dyslipidaemia was admitted for pneumonia and improved after two weeks of treatment. Prior to discharge, he developed giddiness with ST-segment elevation on electrocardiography. Further evaluation revealed triple-vessel coronary artery disease with distal left main stem involvement, requiring urgent CABG. A left internal mammary artery graft to the left anterior descending artery and sequential saphenous vein grafts were performed. An intra-aortic balloon pump was inserted pre-induction, and postoperative inotropic support was required.

Immediate postoperative chest radiography was unremarkable. Within hours, he developed persistent high-grade fever and was commenced on empirical antibiotics. Blood and urine cultures, repeat chest radiography, COVID-19 and malaria screening did not identify an alternative infective source. Given persistent fever despite antibiotics and progressive thrombocytopenia, dengue testing was performed. NS1 antigen was positive within 24 hours of fever onset, supporting acute dengue infection. Dengue serology was not performed as NS1 positivity established the diagnosis during the viraemic phase. DAPT had already been initiated as platelet counts were initially normal.

By postoperative day four, platelet count declined to 78 × 10^9/L and DAPT was withheld following multidisciplinary discussion. During the critical phase, he developed mild hypotension and a right pleural effusion suggestive of plasma leakage, without active bleeding. Fluid management was guided by bedside echocardiography, bedside ultrasound, urine output and fluid balance monitoring. Bedside echocardiography demonstrated preserved left ventricular function with minimal pericardial effusion. Intravenous crystalloid therapy was carefully titrated to maintain perfusion while avoiding fluid overload.

Platelet counts improved to above 100 × 10^9/L by postoperative day eight. In the absence of bleeding manifestations, with haemodynamic stability and resolution of the critical phase, DAPT was reintroduced. He recovered without haemorrhagic or graft-related complications and remained well at three-month follow-up.

DISCUSSION

Dengue fever is endemic in Malaysia and across many tropical countries. As such, dengue infection must be considered in any postoperative patient presenting with unexplained fever, even in the immediate period following major surgery. Early recognition is crucial, as the critical phase, typically occurring between days 3–7 of illness, is characterised by thrombocytopenia and increased vascular permeability leading to plasma leakage.[1-2]

Postoperative fever after CABG is commonly attributed to bacterial infection or the systemic inflammatory response associated with cardiopulmonary bypass. In this patient, however, early NS1 positivity, progressive thrombocytopenia and subsequent plasma leakage strengthened the diagnosis of acute dengue infection after exclusion of alternative infective causes. Although dengue serology was not performed, NS1 antigen positivity during the early febrile phase is highly specific for acute dengue infection.

While guidelines recommend lifelong aspirin after CABG and DAPT in selected cases, antiplatelet therapy must be reassessed in the presence of thrombocytopenia. Although no specific guidelines exist, therapy is generally withheld when thrombocytopenia becomes clinically significant or bleeding risk outweighs thrombotic risk.[3-4] In this case, DAPT was withheld when platelet counts fell below 100 × 10^9/L after multidisciplinary discussion. Daily assessment included chest drain output, haemoglobin trends and clinical examination for haemorrhagic manifestations. Prophylactic platelet transfusion was not administered as there was no active bleeding. DAPT was resumed after platelet recovery above 100 × 10^9/L, absence of bleeding manifestations,

This article was accepted: 01 July 2026
Corresponding Author: Nazurah Binti Badrul Zaman
Email: nazurahbad@gmail.com

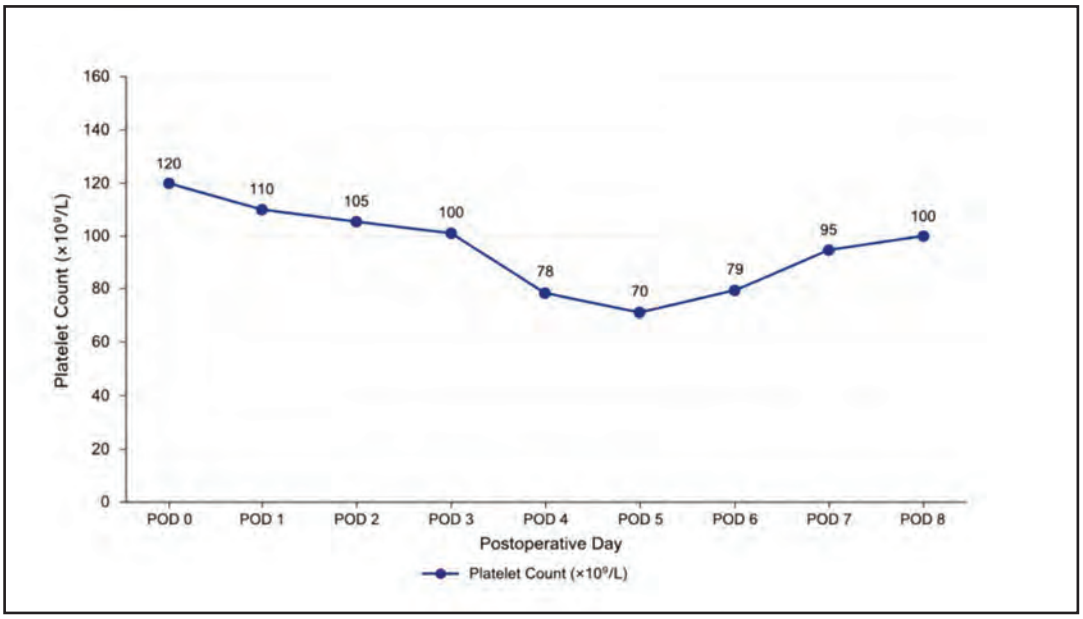

Fig. 1: Serial Platelet Count Trend

haemodynamic stability and resolution of the dengue critical phase, without subsequent thrombotic or haemorrhagic complications.

Dengue-related plasma leakage may lead to hypovolaemia, yet postoperative cardiac patients are vulnerable to fluid overload and pulmonary congestion. Although small pleural effusions are common after CABG, the timing of onset during the thrombocytopenic phase of confirmed dengue infection together with concurrent hypotension suggested dengue-associated plasma leakage as a contributing factor. Fluid management during the critical phase therefore requires careful balance. The World Health Organization dengue guidelines recommend judicious crystalloid resuscitation with close monitoring of clinical parameters.[1] Bedside echocardiography demonstrated preserved ventricular function with only minimal pericardial effusion, while serial point-of-care ultrasound assessment of fluid status guided therapy. These findings helped exclude significant postoperative cardiac dysfunction as the cause of haemodynamic instability and allowed fluid administration to be tailored while avoiding both hypoperfusion and excessive volume loading.

Postoperative management in such complex scenarios necessitates heightened vigilance and close multidisciplinary collaboration among cardiac surgeons, cardiologists, infectious disease specialists, intensivists and haematologists. In this case, delayed discharge allowed continued monitoring and ensured complete recovery from both dengue infection and recent cardiac surgery.[5] Although reports of dengue in the immediate post-CABG setting remain limited, favourable outcomes can be achieved through early recognition, multidisciplinary care and individualised management

REFERENCES

1. World Health Organization. Dengue: guidelines for diagnosis, treatment, prevention and control. Geneva: World Health Organization; 2009.
2. Simmons CP, Farrar JJ, Nguyen VV, Wills B. Dengue. N Engl J Med 2012; 366(15): 1423-32.
3. Levine GN, Bates ER, Bittl JA, Brindis RG, Fihn SD, Fleisher LA, et al. 2016 ACC/AHA guideline focused update on duration of dual antiplatelet therapy in patients with coronary artery disease. Circulation 2016; 134(10): e123-55.
4. McCarthy CP, Steg G, Bhatt DL. The management of antiplatelet therapy in acute coronary syndrome patients with thrombocytopenia: a clinical conundrum. Eur Heart J 2017; 38(47): 3488-92.
5. Tejo AM, Dalugama C, Dissanayake H, Jayasinghe S, Kularatne SAM, Seneviratne SL, et al. Severe dengue in the intensive care unit. J Intensive Med 2024; 4(1): 16-33.

Patch-type kaposi sarcoma as an initial sign of hiv infection with syphilis coinfection: A case report

Nyoman Suryawati, PhD[1], Handelia Phinari, MD[1], Herman Saputra, MD[2]

[1]Department of Dermatology and Venereology, Faculty of Medicine, Udayana University, Ngoerah Hospital, Bali, [2]Department of Anatomical Pathology, Faculty of Medicine, Udayana University, Ngoerah Hospital, Bali

SUMMARY

Kaposi sarcoma (KS) is a vascular neoplasm associated with advanced Human Immunodeficiency Virus (HIV)-related immunosuppression. The patch stage of KS is often challenging for clinicians because it can mimic benign dermatoses, thereby delaying diagnosis. We report a 41-year-old male presenting with multiple violaceous rashes whose dermoscopic and histopathological features are consistent with the patch stage of KS. Laboratory tests confirmed HIV and syphilis infections. The coexistence of KS, HIV, and syphilis highlights the relationship between immunosuppression and sexually transmitted infections (STIs). Early detection of subtle KS lesions enabled timely HIV testing, appropriate antimicrobial therapy, and rapid initiation of antiretroviral treatment, thereby preventing potential progression to visceral or nodular KS. This case highlights the importance of clinical vigilance for early signs of KS, routine STI screening in patients with unusual skin lesions, and the use of skin biopsy to distinguish KS from its mimickers. The report provides insights into the diagnostic challenges posed by early KS and highlights the importance of integrating evaluations of dermatologic and infectious diseases in high-risk populations.

INTRODUCTION

Kaposi sarcoma (KS) is a human herpesvirus-8 (HHV-8)-associated vascular neoplasm that may appear as violaceous macules, patches, plaques, or nodules, with potential mucosal and visceral involvement. It is clinically classified into four epidemiological types: classic, endemic, iatrogenic, and epidemic or HIV-associated KS.[1-2] Although KS is relatively uncommon worldwide, a population-based analysis estimated 34,270 new cases in 2020, with an age-standardised incidence rate of 0.39 per 100,000 population.[3] Importantly, the global burden of KS remains closely linked to HIV infection, with more than two-thirds of KS cases estimated to be HIV-attributable.[4]

Indonesia continues to face a concentrated HIV epidemic, with an estimated 570,000 people living with HIV and a disproportionate burden among key populations, including men who have sex with men, sex workers, transgender people, and people who inject drugs.[5-6] This pattern is clinically relevant because HIV and sexually transmitted infections (STIs) often share overlapping transmission routes and biological interactions. Syphilis, in particular, may increase susceptibility to HIV through mucosal ulceration and inflammation, while HIV infection may alter the clinical course of syphilis.[7] In Indonesia, syphilis remains an important public health problem, with 76,923 new cases reported in 2020.[8]

Early patch-stage KS is diagnostically challenging because its subtle violaceous lesions may resemble benign vascular or inflammatory dermatoses. This can delay recognition of underlying immunosuppression, particularly when KS appears before HIV has been diagnosed. Histopathological examination, supported by HHV-8 immunohistochemistry when available, is therefore important in early or atypical lesions.[1-2] This report presents patch-type Kaposi sarcoma as the initial clinical sign of HIV infection with late latent syphilis, highlighting the importance of early biopsy, HIV testing, and comprehensive STI screening in patients with suspicious violaceous skin lesions.

CASE PRESENTATION

A 41-year-old Russian male, married and residing in Bali for the past two years, presented to the Dermatology and Venereology Outpatient Clinic of Ngoerah Hospital, Bali, in June 2025, with a one-month history of multiple non-pruritic, non-painful erythematous-to-violaceous rash on the nose, trunk, and upper and lower extremities. The lesions initially appeared on the left hand and gradually involved the nasal region, right arm, trunk, and left leg. He also reported one month of watery diarrhea and unintentional weight loss, although no objective measurements were available. The patient had self-medicated with metronidazole and hyoscine butylbromide, without recalling doses or temporal relation to the rash. He denied fever, respiratory symptoms, mucosal lesions, genital ulcers, urethral discharge, prior drug allergy, or systemic comorbidities. Social and sexual history revealed more than ten lifetime female partners, inconsistent condom usage, and the last sexual contact was three months prior. He denied a history of transfusion, tattoos, intravenous drug use, alcohol consumption, or smoking.

On physical examination, vital signs were stable, and the general condition was good. Dermatological assessment revealed multiple well-defined erythematous-to-violaceous macules, patches, papules, and plaques, round to oval in shape, measuring 0.5–3 cm, distributed discretely on the nasal region, bilateral arms, trunk, and left leg. Mucosal abnormalities, Koebner phenomenon, or stigmata of atopy were negative.

This article was accepted: 01 July 2026
Corresponding Author: Nyoman Suryawati
Email: suryawati@unud.ac.id

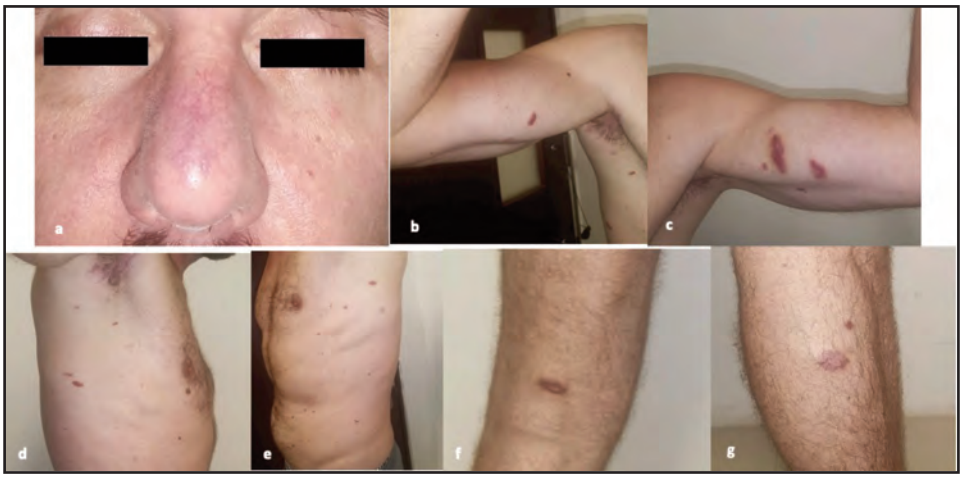

Fig. 1: a-g Clinical photographs on the nasal, right and left brachial, trunk, and left crural regions

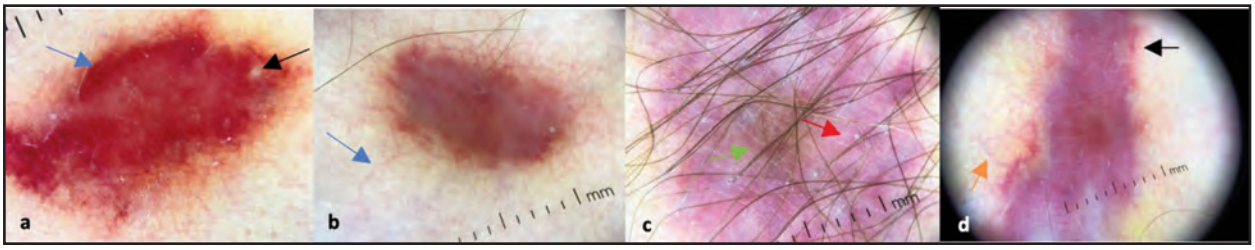

Fig. 2: a-d Dermoscopy examination

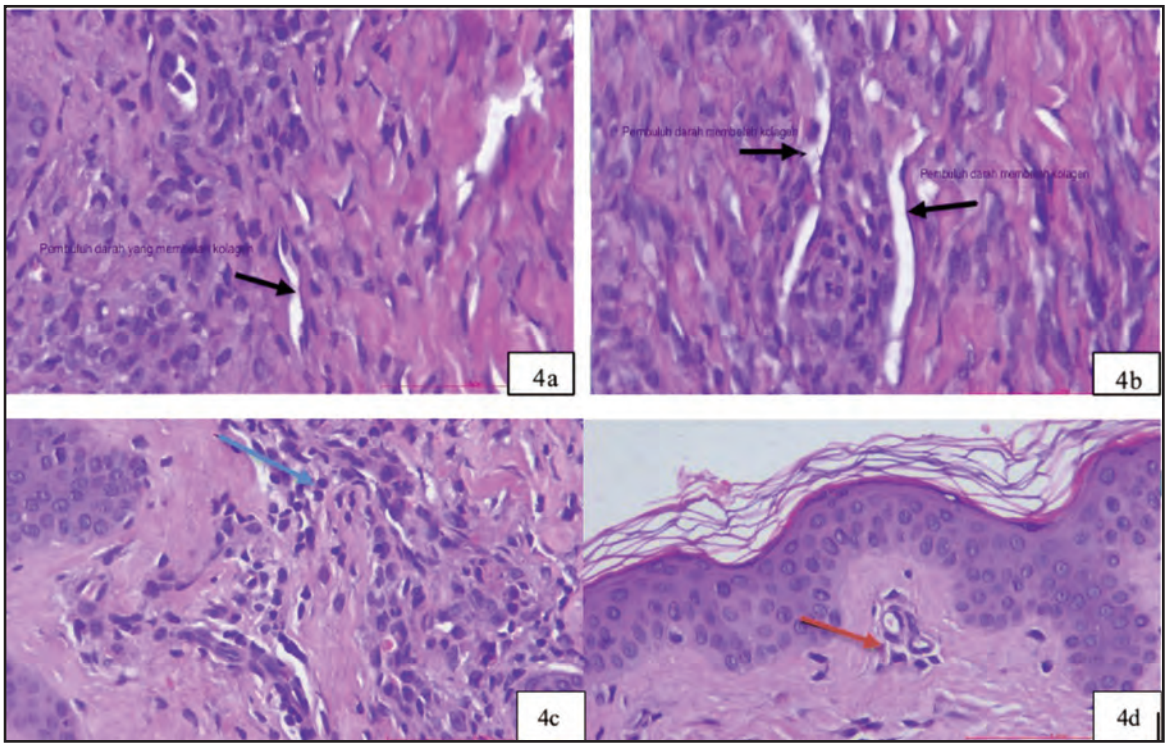

Fig. 2: a-d Histopathological findings

Dermoscopic examination showed polychromatic "rainbow pattern," serpentine, dotted, and coiled vessels, and white lines and clods, features suggestive of Kaposi sarcoma. In the macular–patch lesions, structureless reddish-violaceous areas with fine arborizing vessels at the lesion margins were observed (blue arrows). In the papular–plaque lesions, white scaling and brownish blotches on a reddish-violaceous background (green arrows), along with fragmented vessels at the lesion margins (orange arrows), were noted. A homogeneous polychromatic discoloration forming a rainbow pattern, consisting of light pink, dark red, and violaceous hues, was evident. Serpentine vessels (blue arrows) and dotted and coiled vessels (black arrows) were visible at the lesion margins. White lines and white clods were also observed (indicated by red arrows).

Histopathology of a macular lesion in the left brachial region showed dermal proliferation and dilated vascular channels dissecting through the dermal collagen bundles, some demonstrating a promontory sign (black arrows). Mild perivascular lymphoplasmacytic inflammation is noted (blue arrows), along with scattered hemosiderin pigment (red arrows). Numerous vascular channels surround eccrine structures. The differential diagnosis is consistent with the macular stage of Kaposi sarcoma.

Provider-initiated HIV testing was reactive. Laboratory investigations revealed anemia (Hb 10.5 g/dL), mild thrombocytopenia, elevated liver enzymes, CD4 192 cells/µL, CD4/CD8 ratio 0.11, reactive anti-Cytomegalovirus IgG, Venereal Disease Research Laboratory (VDRL) 1:16, positive Treponema Pallidum Hemagglutination Assay (TPHA), and non-reactive Hepatitis B, Hepatitis C, and Toxoplasma serology. Chest radiography suggested possible pleuritis, and sputum PCR for Mycobacterium tuberculosis was negative. The patient was diagnosed with Kaposi sarcoma, late latent syphilis, and stage IV HIV infection (WHO). He received benzathine penicillin G 2.4 million IU weekly for three doses. From the Internal Medicine Infectious Disease Division, he was started on cotrimoxazole prophylaxis and scheduled to initiate antiretroviral therapy (ART) with tenofovir, lamivudine, and dolutegravir. Screening for AIDS-related opportunistic infections and serial CD4 and viral load monitoring were planned.

After one month follow up, the patient reported no development of new lesions, the pre-existing lesions appeared darker and flatter, without a size in size. VDRL titer decreased to 1:2 one month after benzathine penicillin. The patient was continued on ART and scheduled for routine follow up and monitoring for treatment evaluation and skin lesions progression.

DISCUSSION

KS remains one of the most clinically important AIDS-defining malignancies, particularly in patients with advanced or previously undiagnosed HIV infection. Although KS is uncommon compared with many other malignancies, its epidemiological burden remains closely linked to HIV, with a substantial proportion of global KS cases being HIV-attributable.[3-4] This association is most evident in regions with high HIV and HHV-8 prevalence, particularly sub-Saharan Africa. However, HIV-associated KS continues to be reported in Asia and other non-endemic regions. In Indonesia and Southeast Asia, published data on KS remain limited compared with global reports, making individual case reports important for illustrating regional clinical presentations, diagnostic challenges, and opportunities for earlier recognition.

The present case is noteworthy because patch-type KS was the first visible clue to previously untreated HIV infection. Early KS lesions are often subtle, flat, and faintly violaceous, which makes them easy to misinterpret as purpura, dermatitis, vascular malformations, bacillary angiomatosis, or other benign vascular lesions.[1-2,9] This diagnostic challenge becomes more clinically relevant when HIV infection has not yet been diagnosed, as cutaneous lesions may be the only external sign of significant underlying immunosuppression. In this patient, recognition of suspicious violaceous lesions prompted HIV testing and revealed advanced disease, with a CD4 count of 192 cells/µL and WHO stage IV HIV infection. This finding supports the need to consider HIV-associated KS even when the skin lesions appear mild, asymptomatic, or nonspecific.

Beyond its diagnostic value, this case also reflects the continuing epidemiological overlap between HIV and STIs. Indonesia continues to face a concentrated HIV epidemic, particularly among key populations such as men who have sex with men, sex workers, transgender people, and people who inject drugs.[5-6] Syphilis remains clinically important because it shares overlapping routes of transmission with HIV and may facilitate HIV acquisition through mucosal ulceration, local inflammation, and disruption of epithelial barriers.[7-8] Conversely, HIV infection may modify the clinical course of syphilis and complicate the interpretation of serological response. The coexistence of HIV, HHV-8-associated KS, and late latent syphilis in this patient therefore highlights the importance of comprehensive STI screening when atypical mucocutaneous lesions are encountered, especially in patients with sexual risk factors.

Dermoscopy can provide useful supportive clues when KS is suspected, particularly in early lesions that are clinically subtle. In this case, dermoscopy demonstrated polychromatic discoloration forming a rainbow pattern, accompanied by serpentine, dotted, and coiled vessels, as well as white lines and clods. These findings are consistent with previously reported dermoscopic features of KS and may help differentiate KS from inflammatory or other vascular dermatoses.[10] However, dermoscopy should not be used as a stand-alone diagnostic tool. Its findings must be interpreted together with clinical morphology, distribution of lesions, risk factors, and histopathological examination.

Histopathological confirmation remains central to the diagnosis of early KS. Characteristic features include irregular and slit-like vascular spaces dissecting collagen bundles, spindle-cell proliferation, extravasated erythrocytes, hemosiderin deposition, lymphoplasmacytic infiltrate, and, in some cases, a promontory sign.[1,10] HHV-8 latent nuclear antigen immunohistochemistry is an important

confirmatory tool, particularly in early, subtle, or atypical lesions.[1-2] In this patient, biopsy of a macular lesion enabled diagnosis at the patch stage, before progression into more advanced plaque, nodular, or clinically evident visceral disease. This reinforces the role of early skin biopsy in persistent, multifocal, or unexplained violaceous lesions.

The management of HIV-associated KS depends on the extent of disease, immune status, symptoms, and evidence of visceral involvement. Effective antiretroviral therapy (ART) is the cornerstone of treatment and may lead to stabilisation or regression of early-stage KS by restoring immune function and reducing HHV-8-driven proliferation.[1-2] Local therapy may be considered for limited symptomatic lesions, whereas systemic chemotherapy is generally reserved for extensive, rapidly progressive, symptomatic, or visceral disease.[2] In this case, the patient was started on ART with tenofovir, lamivudine, and dolutegravir, together with cotrimoxazole prophylaxis. Late latent syphilis was treated with benzathine penicillin G 2.4 million IU weekly for three doses, followed by serological monitoring. After one month, the VDRL titre declined from 1:16 to 1:2, suggesting an early favourable serological response, while the absence of new KS lesions indicated early clinical stabilisation.

When compared with reports from highly endemic regions, where KS may present with extensive cutaneous disease, nodular lesions, lymphoedema, or visceral involvement, this case represents an earlier and more subtle cutaneous presentation.[1,3-4] In Southeast Asia and Indonesia, where KS is less frequently reported than in highly endemic regions and may not be the first diagnostic consideration, patch-stage lesions can easily be overlooked.[3-4,9] Therefore, this case adds clinical evidence from Indonesia that early KS may serve as an important entry point for diagnosing advanced HIV infection and concurrent STI coinfection. It also emphasises the value of close collaboration between dermatology, pathology, and infectious disease services in evaluating suspicious skin lesions.[1-2]

This report has several limitations. It describes a single patient, which limits generalisability. Long-term follow-up after ART initiation was not available, restricting assessment of KS regression, immune recovery, and long-term syphilis serological response. The extended evaluation for visceral KS was limited, although the patient had no obvious mucosal involvement and no new lesions during early follow-up. HHV-8 immunohistochemistry was not performed; therefore, the diagnosis was based on clinicopathological correlation supported by dermoscopic and histopathological findings. Despite these limitations, the case provides an important clinical message: persistent violaceous patch lesions, even when asymptomatic, should prompt early biopsy, HIV testing, and comprehensive STI screening, particularly in patients with sexual risk factors or features suggestive of immunosuppression.

CONCLUSION

Prompt biopsy and HIV testing enabled early diagnosis and timely initiation of antiretroviral therapy, which is essential for preventing KS progression. This report reinforces the importance of maintaining clinical vigilance for early KS presentations and contributes additional insight into the diagnostic challenges and epidemiologic overlap of HIV, HHV-8, and syphilis coinfection.

ACKNOWLEDGEMENTS

The authors would like to thank everyone who contributed to this study.

DECLARATIONS

The authors thank the patient for his cooperation and consent to this case report.

CONFLICT OF INTEREST

The authors declared no conflicts of interest.

REFERENCES

1. Cesarman E, Damania B, Krown SE, Martin J, Bower M, Whitby D. Kaposi sarcoma. Nat Rev Dis Primers 2019; 5(1): 9.
2. Esser S, Schöfer H, Hoffmann C, Claßen J, Kreuter A, Leiter U, et al. S1 guidelines for the Kaposi sarcoma. J Dtsch Dermatol Ges 2022; 20(6): 892-904.
3. Fu L, Tian T, Wang B, Lu Z, Gao Y, Sun Y, et al. Global patterns and trends in Kaposi sarcoma incidence: a population-based study. Lancet Glob Health 2023; 11(10): e1566-e1575.
4. Ibrahim Khalil A, Franceschi S, de Martel C, Bray F, Clifford GM. Burden of Kaposi sarcoma according to HIV status: a systematic review and global analysis. Int J Cancer 2022; 150(12): 1948-57.
5. Joint United Nations Programme on HIV/AIDS. Status of HIV programmes in Indonesia. Geneva: UNAIDS; 2025.
6. Januraga PP, Reekie J, Mulyani T, Lestari BW, Iskandar S, Wisaksana R, et al. The cascade of HIV care among key populations in Indonesia: a prospective cohort study. Lancet HIV. 2018; 5(10): e560-e568.
7. Cohen MS, Council OD, Chen JS. Sexually transmitted infections and HIV in the era of antiretroviral treatment and prevention: the biologic basis for epidemiologic synergy. J Int AIDS Soc. 2019; 22 Suppl 6: e25355.
8. Irawan Y, Chelsea E, Surya R. Syphilis elimination in Indonesia by 2030: keeping in the right track. Cermin Dunia Kedokteran. 2023; 50(4): 234-237.
9. Lee DH, Park SY, Hong N, Kook HD, Jung HJ, Ahn J, et al. Very early patch stage of AIDS-related Kaposi sarcoma: a case report. Ann Dermatol 2023; 35(Suppl 2): S310-S313.
10. Tourlaki A, Cinotti E, Ferreli C, Piaserico S, Micali G, Rubegni P, et al. Clinical, dermoscopic, ultrasonographic, and histopathologic correlations in Kaposi's sarcoma lesions and their differential diagnoses: a single-center prospective study. J Clin Med 2023; 12(1): 278.

Long-term type 2 diabetes mellitus remission in non-obese patients using a structured low carbohydrate diet programme: A case series of three Malaysian patients

Manvir Singh Gill, MB BCh BAO

Metabolic Healthcare 34B Jln Tun Mohd Fuad 2, TTDI, Kuala Lumpur Malaysia

SUMMARY

Evidence for type 2 diabetes mellitus (T2DM) remission derives predominantly from overweight and obese populations using very low calorie diet (VLCD) approaches, leaving an evidence gap for non-obese patients with normal body mass index (BMI). Within an unselected real-world cohort of 45 patients on a single structured, medically supervised low carbohydrate diet (LCD) programme (carbohydrate 20–50 g/day) over five years, six had a normal BMI. Five of the six completed the six-month programme and all five achieved remission, spanning Chinese, Indian, and Malay ethnicity; one Chinese patient dropped out. Five-year durability was confirmed in three (two Chinese, one Indian; BMI 20.5–24.5 kg/m²), who form this report; the two Malay remitters were lost to contact after programme completion. The three patients with five-year data sustained remission (HbA1c 5.4%, 6.1%, 6.2%) with net weight loss of 3.7–7.6 kg; one had a transient HbA1c of 6.5% in year three (brief relapse) before returning to remission with renewed dietary adherence. No diabetes-related complications were reported. These observations suggest short-term remission may be readily attainable in non-obese South East Asian patients across ethnic groups, and that the principal barrier to confirming long-term durability may be retention rather than biological response. Larger prospective controlled trials with robust retention strategies are warranted.

INTRODUCTION

T2DM remission, defined by international consensus as an HbA1c below 6.5% (48 mmol/mol) sustained for at least three months without glucose-lowering pharmacotherapy, has become an achievable therapeutic target.[1] The evidence base relies predominantly on weight loss in overweight and obese individuals: the landmark DiRECT trial (BMI 27–45 kg/m²) achieved remission in 48% at one year,[2] though its five-year extension found only 10% of initial remitters remained in remission, with sustained weight loss the principal determinant.[3] Whether remission is achievable in non-obese patients is a critical emerging question. The ReTUNE study (2023) gave the first prospective evidence that approximately 70% of non-obese participants (mean BMI 24.8 kg/m²) could achieve remission through structured weight loss, the key mechanism being reduction of ectopic liver and pancreatic fat, consistent with the Personal Fat Threshold hypothesis.[4] However, ReTUNE used an 800 kcal/day total diet replacement formula; whether a less restrictive, more sustainable LCD achieves comparable remission in non-obese patients, particularly in South East Asians, remains unclear.

South East Asian populations, including Malaysians, develop T2DM at lower BMI thresholds than Western counterparts, driven by higher visceral-to-subcutaneous fat ratios and reduced beta-cell reserve.[5] Malaysia bears one of the region's highest T2DM burdens (18.3% of adults; NHMS 2019), with some subgroups exceeding 20%.[6] Identifying sustainable remission strategies for non-obese patients is therefore of clinical and public health importance. I report a case series drawn from an unselected cohort managed on a single structured LCD programme, focusing on the non-obese subgroup, three of whom have confirmed five-year outcomes. Baseline characteristics are summarised in Table I and clinical outcomes in Table II.

CASE PRESENTATION

Cohort and patient flow

Over the five-year period, 45 patients with T2DM across normal-weight, overweight, and obese categories were enrolled in a single remission programme using an identical protocol; recruitment was not by BMI. Six had a normal BMI (<25 kg/m²). Five of the six completed the programme and all five achieved remission — two Chinese, one Indian, and two Malay (one male, one female); the sixth (a Chinese female) dropped out. Of the five remitters, three (two Chinese males, one Indian male) completed five-year follow-up and are described below; the two Malay remitters could not be contacted after programme completion and were lost to the five-year assessment despite remission at six months.

Programme structure

All patients followed a six-month programme of a ketogenic-range LCD (carbohydrate 20–50 g/day, without protein or caloric restriction) and structured resistance exercise approximately three to four times weekly, individualised and predominantly home-based. Resistance training was chosen over aerobic exercise to preserve lean mass during weight loss and improve insulin sensitivity;[7] detailed session parameters were not prospectively recorded, a limitation. Structured glycaemic monitoring comprised daily SMBG (fasting and two-hour post-prandial) reported online, with weekly

This article was accepted: 02 July 2026
Corresponding Author: Manvir Singh Gill
Email: gill.manvir@gmail.com

Table I: Baseline characteristics of the three patients prior to enrolment in the T2DM remission programme

Case	Patient Profile	Baseline Medications	Age (yr)	BMI (kg/m²)	HbA1c (%)	FBG (mmol/L)	BP (mmHg)	LDL-C[a] (mmol/L)	eGFR[a] (mL/min/1.73m²)
1	Malaysian Chinese male, aged 53; T2DM for 8 yr; no other comorbidities	Sitagliptin/metformin 50/1000 mg OD; gliclazide 60 mg OD	53	24.0	8.3	8.7	130/87	5.6	96
2	Malaysian Chinese male, aged 55; T2DM for 1 yr; hypertension	Empagliflozin 10 mg OD; metformin 850 mg BD; gliclazide MR 30 mg OD; perindopril 8 mg OD	55	24.5	7.2	6.5	128/70	4.8	94
3	Malaysian Indian male, aged 60; T2DM for 14 yr; no other comorbidities	Gliclazide 80 mg OD Gliclazide 80 mg OD	60	20.5	6.4	6.9	104/69	5.2	88

[a]DPP-4i: dipeptidyl peptidase-4 inhibitor; SU: sulfonylurea; SGLT2i: sodium-glucose cotransporter-2 inhibitor; FBG: fasting blood glucose; BP: blood pressure; BMI: body mass index; LDL-C: low-density lipoprotein cholesterol; eGFR: estimated glomerular filtration rate; OD: once daily; BD: twice daily; MR: modified release.

Table II: Clinical outcomes at Year 1 and Year 5 for all three patients

Case	Time Point	Age (yr)	BMI (kg/m²)	HbA1c (%)	FBG (mmol/L)	BP (mmHg)	Net Wt Loss (kg)	LDL-C[a]	Meds	Remission Status
1	Year 1 (2019)	53	22.6	4.5[1]	5.2	110/70	5.0	2.9	Nil	Remission
1	Year 5 (2025)	58	23.3	5.4	5.8	114/73	4.3	2.7	Nil	Sustained
2	Year 1 (2019)	55	22.2	6.0	5.2	135/82	7.0	3.1	Nil	Remission
2	Year 5 (2025)	60	22.0	6.1	5.8	130/84	7.6	2.8	Nil	Sustained
3	Year 1 (2019)	60	19.2	6.0	5.8	100/72	3.7	2.7	Nil	Remission
3	Year 5 (2025)	65	19.2	6.2	6.4	101/70	3.7	2.8	Nil	Re-remission[2]

[1]HbA1c 4.5% at programme end (6 months); no symptomatic hypoglycaemia documented; stabilised to 5.1% at the subsequent 3-month check and remained below 5.7% over 5 years. [2]Case 3 experienced a transient HbA1c of 6.5% in Year 3 (brief relapse); remission was re-achieved and maintained through Year 5. FBG: fasting blood glucose; BP: blood pressure; LDL-C: low-density lipoprotein cholesterol.

clinician consultations (in person or telemedicine) for medication titration. Sulfonylureas (and the SGLT2 inhibitor in Case 2) were tapered early given hypoglycaemia risk; patients reported any SMBG <4.0 mmol/L immediately, and no symptomatic hypoglycaemia occurred. HbA1c, FBG, renal profile (including eGFR) and fasting lipids (including LDL-C) were measured at baseline, three and six months, with annual HbA1c thereafter. Waist circumference, body fat percentage, apolipoprotein B, and sarcopenia or micronutrient screening were not performed (acknowledged as limitations). Written informed consent was obtained from all patients, whose identities are anonymised per the Declaration of Helsinki.

Case 1:
A 53-year-old Malaysian Chinese male with eight-year T2DM and no other illnesses was enrolled on sitagliptin/metformin 50/1000 mg and gliclazide 60 mg daily (Table I). Gliclazide was tapered first without hypoglycaemia, and he was medication-free by month four. At programme end his HbA1c was 4.5% — below the reference limit but without symptomatic hypoglycaemia (SMBG fasting 4.5–5.2 mmol/L) and, off all medication, most likely reflecting genuine normalisation rather than overtreatment. It rose to 5.1% three months later and has remained below 5.7% (5.4% in 2025). Net weight loss was 5.0 kg at year one and 4.3 kg at year five (BMI 23.3 kg/m^2). He remains medication-free with no complications.

Case 2:
A 55-year-old Malaysian Chinese male with one-year T2DM and hypertension was enrolled on empagliflozin 10 mg once daily, metformin 850 mg twice daily, gliclazide MR 30 mg once daily, and perindopril 8 mg once daily (Table I). Given additive hypoglycaemic risk, gliclazide and empagliflozin were tapered early and simultaneously; no hypoglycaemia occurred, and all oral hypoglycaemic agents were stopped by six months (HbA1c 5.7%). Perindopril was also discontinued, as home BP monitoring remained within an acceptable range off therapy; BP is kept under surveillance (130/84 mmHg at five years). HbA1c was 6.0% at three months post-programme (fulfilling remission criteria) and 6.1% at five years, with net weight loss of 7.6 kg (BMI 22.0 kg/m^2). He remains medication-free with no complications.

Case 3:
A 60-year-old Malaysian Indian male with 14-year T2DM was enrolled on gliclazide 80 mg once daily (Table I). Gliclazide was tapered from the first week without hypoglycaemia; by three months his HbA1c was 5.5% off medication, with a six-month value of 6.0% confirming remission. Net weight loss was 3.7 kg, maintained at five years (BMI 19.2 kg/m^2). A transient HbA1c of 6.5% in year three — the diagnostic threshold for diabetes — represented a brief relapse, attributed by the patient to higher carbohydrate intake and psychosocial stress; HbA1c returned below 6.5% with renewed dietary adherence and remained so through year five (meeting re-remission criteria). His five-year HbA1c was 6.2%. His maintained BMI of 19.2 kg/m^2, although within the normal range, lies at its lower end for an older adult; he was never clinically underweight, but formal sarcopenia, body-composition, and micronutrient monitoring were not performed and would be advisable in older patients undergoing such programmes. No complications were identified.

DISCUSSION

This series describes three non-obese Malaysian patients who achieved T2DM remission through a structured, medically supervised ketogenic-range LCD, with remission largely sustained over five years. As an uncontrolled observational series of selected patients, it cannot establish efficacy, but offers several hypothesis-generating observations for a phenotype under-represented in trials.

Mechanism and predictors. The prevailing framework — irrespective of starting BMI — is the Personal Fat Threshold hypothesis, whereby T2DM develops once liver and pancreatic fat exceed an individual's tolerance, impairing insulin sensitivity and beta-cell function even at normal BMI. ReTUNE showed that reducing ectopic fat in non-obese individuals produces metabolic changes identical to those in obese remitters.[4] Here, modest weight losses of 3.7–7.6 kg (6–10% of baseline) accompanied durable remission; carbohydrate restriction reduces hepatic glucose production and intrahepatic lipid independent of caloric intake.[8] Recognised predictors — shorter duration, lower baseline HbA1c, fewer medications[9] — are instructive: Case 2 (one-year duration) had the most favourable profile, Case 1 responded strikingly despite eight years of disease and high baseline HbA1c, and Case 3 (14 years) required the strictest adherence and relapsed transiently, consistent with remission rates falling from ~77% under one year to ~20% beyond 15 years.[10]

LCD versus VLCD, and the South East Asian phenotype.ReTUNE used an 800 kcal/day formula replacement — effective, but potentially less acceptable for non-obese patients with limited weight to lose; meta-analysis finds low and very low carbohydrate diets at least as effective as VLCDs for remission.[11] The LCD used here requires no formula, integrates with familiar South East Asian dietary patterns, and entails a gradual transition that may aid adherence. Malaysian patients of Chinese and Indian ethnicity show earlier-onset disease at lower BMI, greater visceral adiposity, and impaired insulin secretion;[5] even modest ectopic fat reduction may restore beta-cell function. With a national prevalence of 18.3%,[6] this supports evaluating structured remission programmes in primary care, with telemedicine and digital SMBG offering a scalable model.

Safety, and retention as the principal barrier. Hypoglycaemia during LCD-based tapering is the central safety concern, particularly with sulfonylurea and SGLT2i use; these were tapered early and no symptomatic hypoglycaemia occurred. The HbA1c of 4.5% in Case 1, without pharmacotherapy or symptomatic hypoglycaemia, most likely reflected physiological normalisation, though continuous glucose monitoring would be a valuable future adjunct. A notable observation arises from the cohort flow: all five non-obese patients who completed the programme achieved remission, spanning Chinese, Indian, and Malay ethnicity, suggesting

short-term remission is attainable across the major Malaysian ethnic groups. The constraint on confirming long-term durability was not biological non-response but loss of follow-up — two Malay remitters could not be traced at five years. This reframes the central question from "can non-obese patients achieve remission?" to "how can they be retained and monitored so that remission is sustained and documented?" Retention and recall infrastructure may be as important to real-world outcomes as the dietary intervention itself.

LIMITATIONS

This uncontrolled series cannot establish efficacy. Detailed five-year outcomes are confined to three patients; of six non-obese patients, one dropped out and two remitters were lost to contact, so confirmed long-term outcomes are limited to males of Chinese and Indian ethnicity and cannot be extrapolated to women, although short-term remission occurred in both sexes. Confirmed long-term outcomes for Malay patients — the highest-prevalence group — are absent owing to loss of follow-up and should be a research priority. Beta-cell reserve, waist circumference, body composition, apolipoprotein B, and sarcopenia and micronutrient screening were not measured, and the data derive from a single private clinic. Notwithstanding these limitations, the consistency of short-term remission across all three major Malaysian ethnic groups, with five-year durability in three patients, is a meaningful preliminary contribution.

CONCLUSION

This preliminary case series suggests that T2DM remission may be readily achievable in non-obese Malaysian patients through a medically supervised, ketogenic-range LCD with resistance training and structured glycaemic monitoring. Within the non-obese subgroup of an unselected cohort, all five completers achieved remission across Chinese, Indian, and Malay ethnicity, and five-year durability was confirmed in three. Notably, the principal barrier to confirming durability was loss of follow-up rather than loss of remission, suggesting retention infrastructure may be as decisive as the intervention itself. These hypothesis-generating findings, consistent with the Personal Fat Threshold hypothesis and ReTUNE, should be interpreted with caution given the uncontrolled design and small sample, and justify larger prospective controlled trials — with robust retention strategies, inclusive of women and all major Malaysian ethnic groups — to evaluate efficacy, safety, durability, and cost-effectiveness.

DECLARATION

Ethical approval and patient consent: Written informed consent for publication was obtained from all three patients. Patient identities have been fully anonymised.

CONFLICTS OF INTEREST

The author declares no conflicts of interest.

FUNDING

No external funding was received for this work.

ACKNOWLEDGEMENT

The author thanks all three patients for their informed consent to publish and for their sustained commitment to the programme over the five-year follow-up period.

REFERENCES

1. Riddle MC, Cefalu WT, Evans PH, Gerstein HC, Nauck MA, Oh WK, et al. Consensus Report: Definition and Interpretation of Remission in Type 2 Diabetes. Diabetes Care 2021; 44(10): 2438-44.
2. Lean ME, Leslie WS, Barnes AC, Brosnahan N, Thom G, McCombie L, et al. Primary care-led weight management for remission of type 2 diabetes (DiRECT): an open-label, cluster-randomised trial. Lancet 2018; 391(10120): 541-51.
3. Lean ME, Leslie WS, Barnes AC, Brosnahan N, Thom G, McCombie L, et al. 5-year follow-up of the randomised Diabetes Remission Clinical Trial (DiRECT) of continued support for weight loss maintenance in the UK: an extension study. Lancet Diabetes Endocrinol 2024; 12(4): 233-46.
4. Taylor R, Barnes AC, Hollingsworth KG, Irvine KM, Solovyova AS, Clark L, et al. Aetiology of Type 2 diabetes in people with a 'normal' body mass index: testing the personal fat threshold hypothesis. Clin Sci (Lond) 2023; 137(16): 1333-46.
5. Ke C, Narayan KMV, Chan JCN, Jha P, Shah BR. Pathophysiology, phenotypes and management of type 2 diabetes mellitus in Indian and Chinese populations. Nat Rev Endocrinol 2022; 18(7): 413-432.
6. Institute for Public Health. National Health and Morbidity Survey (NHMS) 2019: Non-communicable diseases, healthcare demand, and health literacy — key findings. Kuala Lumpur: Institute for Public Health, Ministry of Health Malaysia; 2020.
7. Strasser B, Pesta D. Resistance training for diabetes prevention and therapy: experimental findings and molecular mechanisms. Biomed Res Int 2013; 2013: 805217.
8. Goldenberg JZ, Day A, Brinkworth GD, et al. Efficacy and safety of low and very low carbohydrate diets for type 2 diabetes remission: systematic review and meta-analysis of published and unpublished randomized trial data. BMJ 2021; 372: m4743.
9. Boye KS, Thieu VT, Lage MJ, Miller H, Paczkowski R. The Association Between Sustained HbA1c Control and Long-Term Complications Among Individuals with Type 2 Diabetes: A Retrospective Study. Adv Ther 2022; 39(5): 2208-21.
10. Unwin D, Delon C, Unwin J, Tobin S, Taylor R. What predicts drug-free type 2 diabetes remission? Insights from an 8-year general practice service evaluation of a lower carbohydrate diet with weight loss. BMJ Nutr Prev Health 2023; 6(1): 46-55.
11. Churuangsuk C, Hall J, Reynolds A, Griffin SJ, Combet E, et al. Diets for weight management in adults with type 2 diabetes: an umbrella review of published meta-analyses and systematic review of trials of diets for diabetes remission. Diabetologia 2022; 65(1): 14-36.
12. Ministry of Health Malaysia. National Strategic Plan for Non-Communicable Diseases (NSP-NCD) 2016–2025. Putrajaya: Ministry of Health Malaysia; 2016. https://www.moh.gov.my/images/04-penerbitan/rujukan/penyakit-berjangkit/ncd/FINAL_NSPNCD.pdf

Late complication of bladder outlet obstruction following mid urethral sling with concurrent detrusor underactivity: A case report

Nurul Hikmah MN (Master of Obstetrics & Gynaecology), Zalina Nusee (Urogynaecology Fellowship)

Department of Obstetrics & Gynaecology, Kuliyyah of Medicine, International Islamic University Malaysia

SUMMARY

Late presentation of voiding dysfunction (VD) secondary to bladder outlet obstruction (BOO) following mid urethral sling (MUS) is seldom reported. A concurrent detrusor underactivity (DUA) could worsen the voiding dysfunction symptoms. We present a case of a 71-year-old woman presented with VD 12 years following MUS. Investigations showed evidence of partial BOO with concurrent DUA. Despite total mesh removal, the symptoms persisted requiring self-intermittent catheterization. Conclusion: This case highlights the importance of long term follow up of more than 10 years, as VD following MUS may still present late. Preoperative urodynamic evaluation of concurrent DUA is also crucial as it may further complicate outcomes.

INTRODUCTION

Mid urethral sling (MUS) is regarded as the gold standard treatment for stress urinary incontinence (SUI) as it is highly effective. However, despite its effectiveness, complications may arise such as mesh exposure, de novo urgency, and voiding dysfunction (VD). VD has been described in approximately 2-25% of women following MUS, and objectively confirmed obstruction may be identified in a substantial proportion of symptomatic patients.[1-2] The presentation ranges from transient postoperative retention to chronic bladder outlet obstruction (BOO). The most common reported timing of occurrence is within two weeks, whilst late presentation is rarely reported.

Detrusor underactivity (DUA) is a urodynamic diagnosis that represents poor contractility of the bladder. Women may be asymptomatic or present with VD such as incomplete bladder emptying which may then lead to chronic urinary retention. This condition may co-exist in women presenting with SUI but often undiagnosed. We present a case of late presentation of BOO 12 years after MUS surgery with concurrent DUA, highlighting the importance of long term follow up and preoperative detection of DUA.

CASE PRESENTATION

A 71-year-old woman, para 3, presented to the urogynecology clinic with VD and recurrent UTIs. She had undergone transobturator tape 12 years earlier. For the past four years, she complained of impaired bladder sensation, urinary frequency, incomplete voiding, and eventually overflow incontinence. She then developed recurrent UTIs requiring hospital admission for intravenous therapy. Otherwise, she denied recurrence of stress incontinence. Examination findings were unremarkable. The post void residual is significantly high at 300ml.

Multiple investigations were conducted to assess the cause of VD and recurrent UTIs. Transperineal ultrasound showed the sling was positioned correctly at the mid urethra while the sling-pubis gap was 18.9 mm which did not suggest an overtight sling (Figure 1). Urodynamic study revealed that she had early first sensation at 69 ml, the bladder capacity was small at 132 ml, and a low compliance bladder (Figure 2). In the voiding phase, she had difficulty to void with Qmax of only 3 ml/s and PdetQmax of 28.6 cmH_2O. The Bladder Outlet Obstruction Index (BOOI) was 22 while the Bladder Contractility Index (BCI) was 53. The micturating cystourethrogram (MCUG) showed bladder distension with irregular wall and narrowing at mid-urethra, which was consistent with partial obstruction, otherwise there was no reflux or hydronephrosis reported. Cystoscopy was also performed and showed generalized trabeculated bladder with no evidence of mesh erosion on both the bladder and urethra. Our diagnostic dilemma was whether the chronic obstruction was contributed by BOO alone or by DUA as well. Even though the sling-pubis gap did not suggest an overtight sling, imaging with MCUG shown partial obstruction while the urodynamic study suggested equivocal obstruction and presence of DUA. In view of the severity of obstruction, we decided for total mesh removal, but preoperatively she was counselled the possibility of persistence of symptom post removal due to the presence of DUA. Post mesh removal, she reported return of voiding sensation however difficulty to initiate urination persisted requiring self-intermittent catheterisation. The frequency of UTI was also similar prior to mesh removal. We continue to monitor her condition to ensure no further complication arise such as upper tract infection or deterioration of renal function.

While the rates of VD after MUS have been reported at 2–25 %, urodynamic-confirmed BOO has been seen in up to 60% of symptomatic cohorts post sling surgery.[1-2] The presentation of BOO is mostly reported early within the postoperative period with limited study reporting the exact time of occurrence. A long term study on outcome of MUS shown that majority of sling revision/removal occurred within the first few years after index sling surgery, with a cumulative risk of

This article was accepted: 04 July 2026
Corresponding Author: Nurul Hikmah MN
Email: nurulhikmah@iium.edu.my

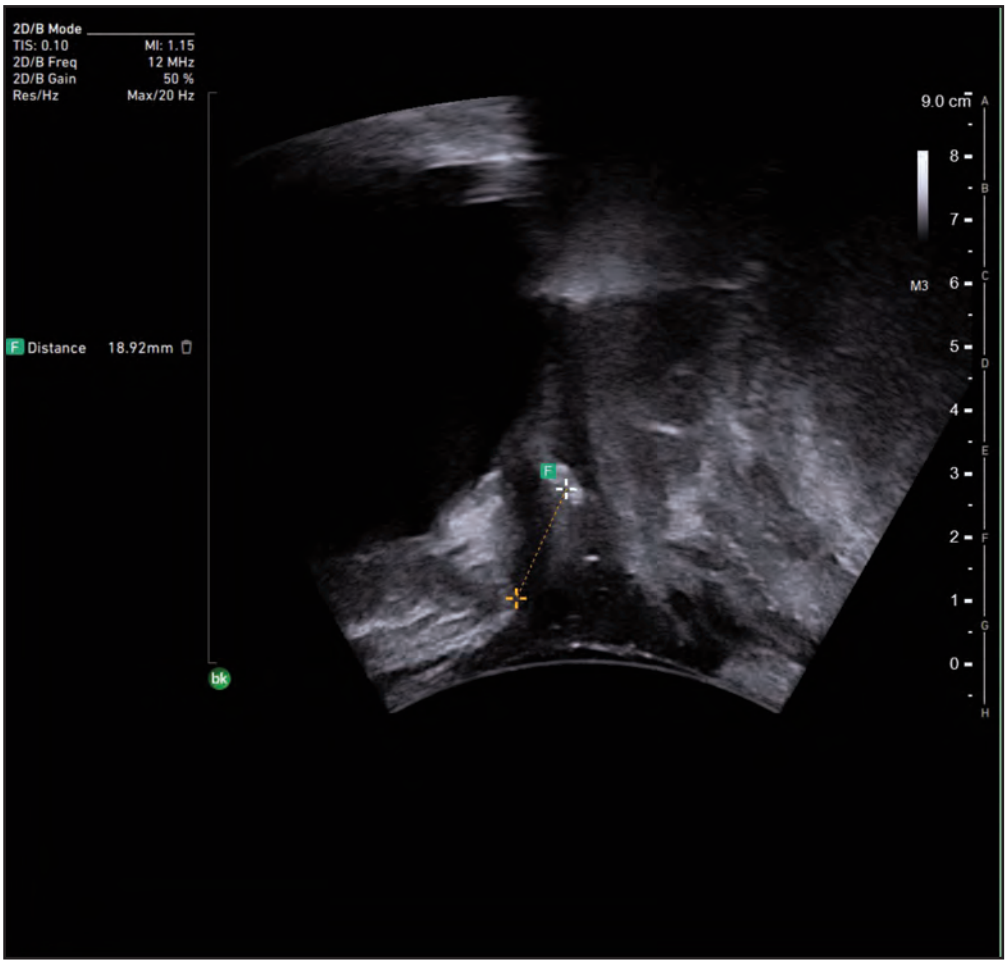

Fig. 1: Transperineal ultrasound showing sling-pubis gap

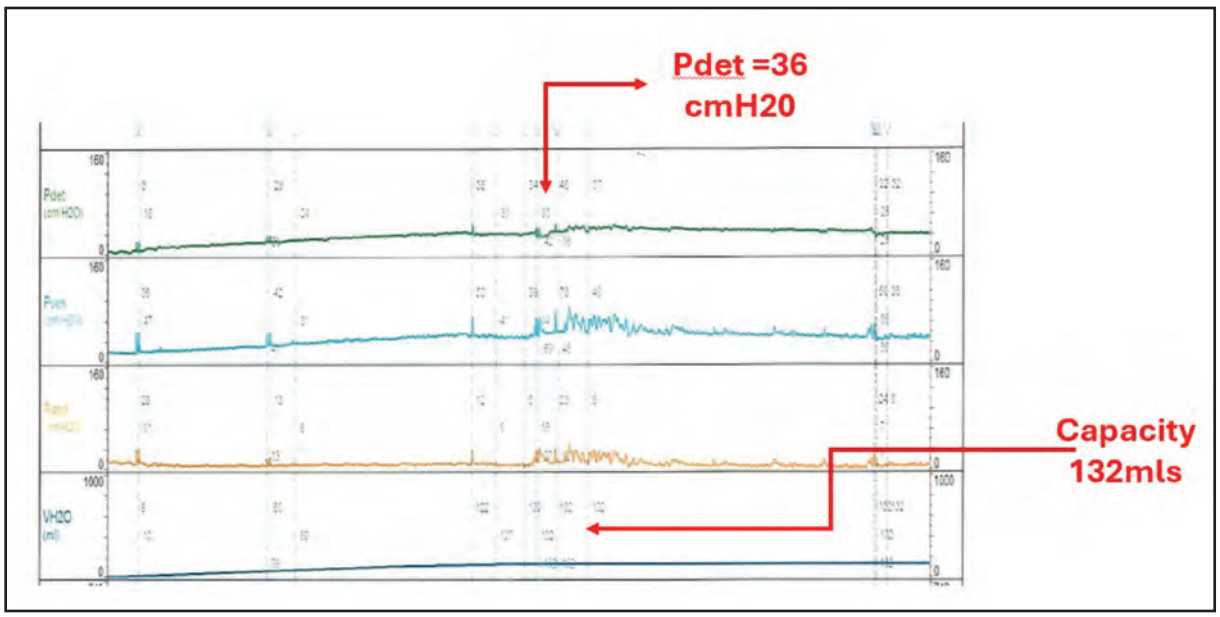

Fig. 2: Urodynamic study result showing low bladder compliance

0.9% (95% CI 0.9,1.0) at 1 year, increased to 1.3% (95% CI 1.2,1.4) at 6 years then remains plateauing until 9 years.[3] This proves that BOO can also present late, and in our case even after 10 years. However, to date there is no standardized guideline suggesting the exact duration of mandatory follow up after MUS to allow early detection of VD. This case demonstrated that late detection of VD has led to low compliance bladder with potential irreversible bladder damage. A long-term follow-up for MUS is therefore mandatory as VD can still present late with possibility of needing lifelong monitoring. Follow-up visit should address specific question of obstructive symptoms such as incomplete emptying, frequency, weak stream, straining, and hesitancy. Post-void residual, uroflowmetry and transperineal ultrasound are useful adjunct for assessing sling position and potential obstruction.

VD after MUS may result from BOO due to an overtight sling, or from an underlying DUA. Differentiating between the two entities is often difficult, particularly when symptoms develop insidiously. DUA is increasingly recognised among women with SUI undergoing preoperative evaluation for MUS with one study reported 54.6% of women have concurrent DUA and SUI.[4] In this case, we were unable to acquire the preoperative urodynamic study result to evaluate presence of concurrent DUA prior to surgery. The temporal association between sling surgery and new symptoms is important, however, in this case, the symptom only arose more than 10 years after the surgery, suggesting that it may not be caused directly by the sling alone but also contributed by other causes such as DUA. The current urodynamic result suggested both element of BOO and DUA given the equivocal BOOI and very low BCI, hence the decision to proceed with total mesh removal.

Several mechanisms may underlie obstructed voiding after MUS. The most frequently proposed is mechanical: excessive tape tension, urethral over-elevation, or mid-urethral kinking increases outlet resistance and compresses the urethra.[5] Progressive peri-tape fibrosis and scar contracture may further tether or narrow the urethra over time, offering a plausible explanation for obstruction that presents years after an initially uncomplicated recovery, as in our patient. A neurogenic contribution from peri-urethral denervation during dissection has also been postulated, although evidence in minimally invasive MUS is limited and mechanical factors are generally regarded as dominant. Importantly, sustained partial obstruction can itself drive detrusor decompensation, whereby chronic outlet resistance leads to detrusor hypertrophy followed by fibrosis, reduced compliance, and ultimately impaired contractility.[6-7] This continuum may account for the coexisting low-compliance, underactive bladder observed in our case and underscores why obstruction and DUA become difficult to disentangle once the disease is established.[8]

Urodynamic study is not a routine preoperative assessment for women planned for MUS, especially among the uncomplicated SUI. This case suggests that urodynamic study is crucial for all women undergoing MUS as this will allow objective assessment of the detrusor contractility. One mid-term outcome study of DUA at two years suggested the impact is mainly at early post operative retention with no significant lasting effect.[9] Therefore, a proper preoperative counselling is essential and compliance to follow up schedule should be emphasized to allow earlier detection and treatment of VD which could be contributed by both MUS placement and DUA.

CONCLUSION

This case highlights the importance of long term follow up for MUS of more than 10 years, potentially needing lifelong surveillance as VD may still present late. Evaluation of concurrent DUA by routine preoperative urodynamic study is also crucial prior to MUS as it may contributes to worsening of the VD and further complicate outcomes if remain undetected.

Ethical considerations & Patient Consent

This case report was prepared in accordance with the Declaration of Helsinki. Approval for publication of anonymised case material was obtained from the institutional research committee of SASMEC @ IIUM. The authors certify that they have obtained all appropriate patient consent forms, in which the patient had given her consent for images and other clinical information to be reported in the journal. She understands that her name and initial will not be published, and due efforts will be made to conceal the identity, but anonymity cannot be guaranteed.

REFERENCES

1. Ross J, Avvakoumova L, Yassein A, et al. Prevalence and Predictors of Bladder Outlet Obstruction in Women With Chronic Urinary Symptoms and a History of Urethral Sling Surgery. J Urol. 2023; 209(2): 384-90.
2. Tsai C-P;, Liu C-K;, Yang E;, et al. Continence Is Not Affected after Sling Revision with Transvaginal Tape Elongation for Post-Sling Voiding Dysfunction. J Clin Med 2024, Vol 13, Page 637. 2024; 13(2): 637.
3. Jonsson Funk M, Siddiqui NY, Pate V, Amundsen CL, Wu JM. Sling Revision/Removal for Mesh Erosion and Urinary Retention: Long-term Risk and Predictors. Am J Obstet Gynecol. 2012; 208(1): 73.e1.
4. Rubilotta E, Ditonno F, Gubbiotti M, Antonelli A, Balzarro M. Detrusor underactivity and complicated stress urinary incontinence: a cross-data study. Cent Eur J Urol 2024; 77(1): 58.
5. Çelik H, Harmanli Ö. Evaluation and management of voiding dysfunction after midurethral sling procedures. J Turkish Ger Gynecol Assoc 2012; 13(2): 123.
6. Fusco F, Creta M, De Nunzio C, et al. Progressive bladder remodeling due to bladder outlet obstruction: a systematic review of morphological and molecular evidences in humans. BMC Urol 2018; 18(1): 15.
7. Osman NI, Chapple CR, Abrams P, et al. Detrusor underactivity and the underactive bladder: A new clinical entity? a review of current terminology, definitions, epidemiology, aetiology, and diagnosis. Eur Urol 2014; 65(2): 389-98.
8. Chow PM, Hsiao SM, Kuo HC. Identifying occult bladder outlet obstruction in women with detrusor-underactivity-like urodynamic profiles. Sci Reports 2021 111. 2021; 11(1): 23242.
9. Rubilotta E, Balzarro M, Gubbiotti M, Cerrato C, Giannantoni A, Antonelli A. Urodynamics criteria of detrusor underactivity in women underwent middle urethral sling for stress urinary incontinence: What is the clinical role? Neurourol Urodyn. 2021; 40(8): 1955-65.

CASE REPORT

A rare case of placenta praevia percreta of an unscarred uterus in a systemic lupus erythematosus patient

Janisha Silva Raju, DrObGyn, Ravichandran Jeganathan, FRCOG

Department of Obstetrics & Gynaecology, Hospital Sultanah Aminah, Johor Bahru, Johor, Malaysia.

SUMMARY

Pregnancy in systemic lupus erythematosus (SLE) patients poses higher risks of adverse pregnancy outcomes. Placenta accreta spectrum (PAS) with various degrees of abnormally invasive placentation is associated with severe maternal morbidity and mortality. Pregnancy in SLE with coexisting PAS is indeed a double whammy. This was an unusual case of placenta previa percreta in a nulliparous with unscarred uterus and underlying SLE with grade IV lupus nephritis, in whom a placenta previa major with PAS suspected prenatally, sustained massive obstetric haemorrhage at delivery due to percreta, necessitated multiple blood transfusions and Caesarean hysterectomy. Adjunct MRI found suspicious of percreta. She has been on steroid for past 11 years, and her SLE remained quiescent throughout pregnancy. She underwent bilateral internal iliac artery balloon occlusion, bilateral retrograde pyelogram with ureteric stenting and Caesarean hysterectomy at 37 weeks. Intraoperatively noted bulging hypervascularized uterine lower segment with large vessels diffusely seen on uterine serosa, diffuse thinning of myometrium with areas appeared devoid of myometrium and large placenta occupying almost entire uterus. Histopathological analysis revealed percreta, with diffuse myometrial thinning especially at placental adherent site, and areas of placental invasion breaching uterine serosa.

This case emphasizes the significance of precise prenatal diagnosis of PAS for optimal perioperative preparation to minimise complications. PAS is indeed rare among nulliparous women and unusual on an unscarred uterus. However, preexisting SLE with prolonged steroid consumption may be a rare risk factor for PAS especially in placenta previa.

INTRODUCTION

Systemic lupus erythematosus (SLE) is a multisystemic autoimmune disorder with heterogeneous manifestations that is prevalent in females of reproductive age. Pregnant women with SLE are at higher risks of adverse pregnancy outcomes and complications, including severe preeclampsia, infections, thromboembolic complications, flares during pregnancy, utero-placental insufficiency, fetal growth restriction and even maternal or fetal mortality.

Placenta accreta spectrum (PAS) defined by various degrees of abnormally invasive placentation is associated with severe maternal morbidity and mortality, mainly reflecting massive maternal hemorrhage at delivery, the need for massive blood transfusion, complex surgery and increased intensive care unit admissions. Predisposing factors for PAS include multiparity, placenta praevia, smoking, previous PAS and previous uterine surgeries including endometrial curettage, Caesarean delivery and myomectomy. The increase in the overall rate of Caesarean deliveries with concurrent increase in maternal age at delivery, causes a rise in the incidence of PAS.

Prenatal sonographic findings associated with PAS, especially in placenta praevia cases include the loss of hypoechoic retroplacental sonolucency, myometrial thinning, interruption of utero-vesical plane, placental bulge into the bladder wall, hypervascularity of the utero-vesical interface, multiple placental lacunae ("moth-eaten" appearance of the placenta), hypervascularity of subplacental area, bridging vessels with vascularity extending from the placental bed across the uterine wall into the bladder or adjacent pelvic organs.

CASE PRESENTATION

This is an unusual case of placenta praevia percreta in a young nulliparous patient with unscarred uterus and underlying systemic lupus erythematosus (SLE) with grade IV lupus nephritis, in whom placenta praevia major with placenta accreta spectrum (PAS) suspected prenatally, sustained massive obstetric haemorrhage at delivery due to placenta accreta spectrum, necessitated multiple blood transfusions and Caesarean hysterectomy.

A 29-year-old, primigravida, with underlying SLE and diffuse proliferative lupus nephritis of grade IV since age 18, had a spontaneous conception after 2 years of marriage. She has been on steroid treatment for the past 11 years. Her last flare was at age 25. She was on Prednisolone, Hydroxychloroquine and Azathioprine. She was on low dose Aspirin in pregnancy, and her SLE remained quiescent throughout pregnancy. Her baseline 24-hour urine protein at 18 weeks was 140 mg/day. Laboratory value indices including full blood count, renal function and liver function were within normal limits. Modified oral glucose challenge test at 13 weeks and 28 weeks were normal. Antiphospholipid antibodies and extractable nuclear antigen antibodies were negative, whereas complements level C3 and C4 were normal.

Ultrasound at 22 weeks found anterior low-lying placenta with thin residual myometrium and multiple placental

This article was accepted: 07 August 2026
Corresponding Author: Janisha Silva Raju
Email: janisha82@gmail.com

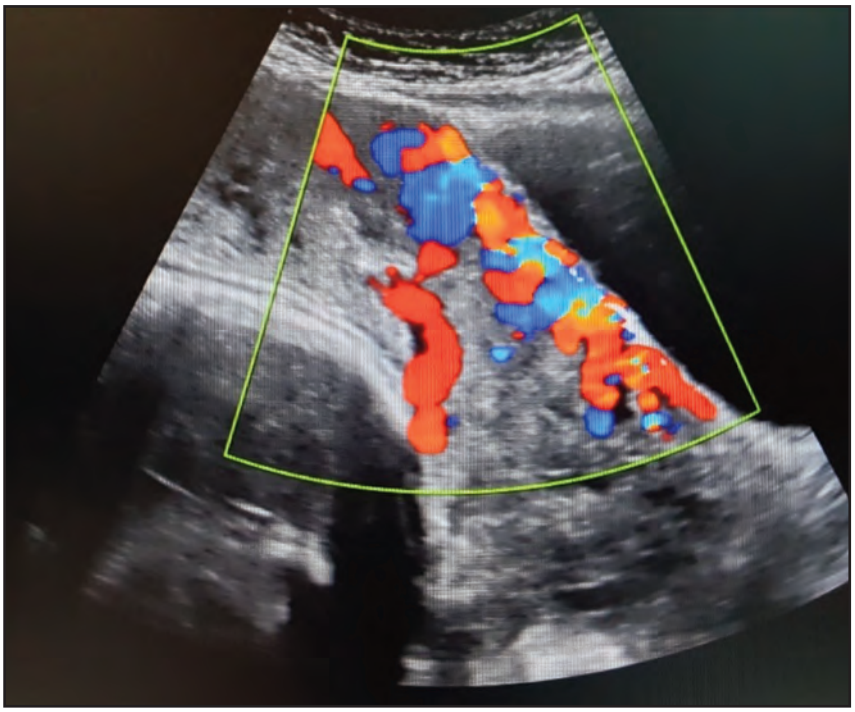

Fig. 1: USG Color Doppler image showing hypervascularity at utero-vesical interface

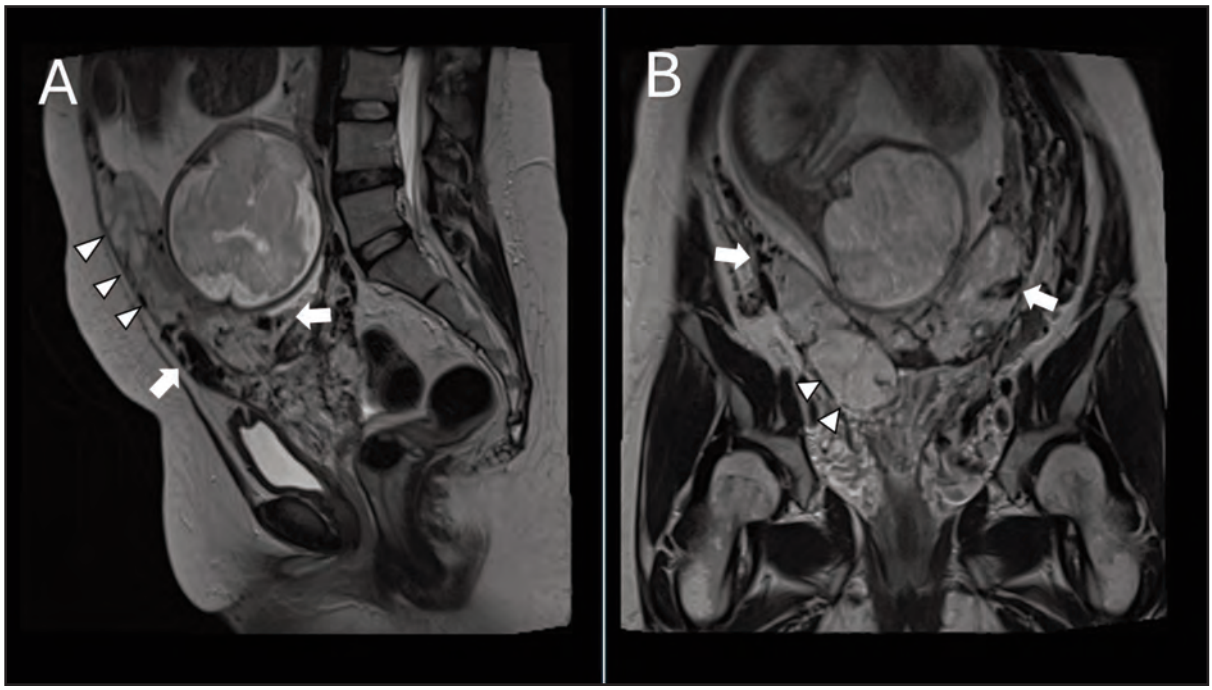

Fig. 2: MRI T2W Sagittal (A) and Coronal view (B): Placenta previa major with abnormal intra-placental vasculature (white arrow in "A" and "B"). Thinned out myometrium with loss of normal hypointense myometrial interface between the placenta and the myometrium (white arrowheads in "A"). Placental bulge at the right lower uterine segment (white arrowheads in "B")

lacunae. Fetus had large omphalocoele with liver content. Couple was not keen for amniocentesis for further evaluation of the fetal omphalocoele. She remained normotensive, whereas fetus was small for gestation, but liquor volume and fetal dopplers were within normal limits throughout pregnancy. Ultrasound at 29 weeks noted placenta praevia major covering internal os, with sonographic features of PAS. Adjunct magnetic resonance imaging (MRI) done to evaluate the extend of placental invasion, revealed loss of normal T2W low signal intensity between uterus and urinary

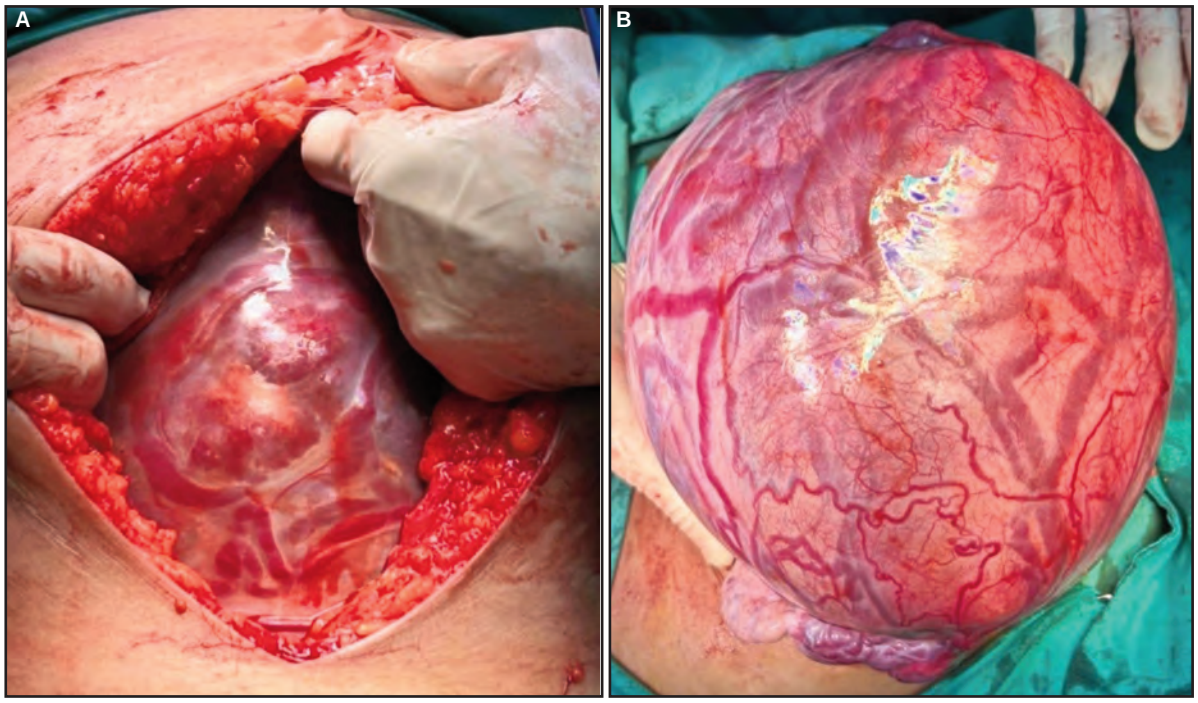

Fig. 3: Bulging hypervascularized anterior lower segment of the uterus (A). Gravid uterus with diffuse vascularization seen through uterine serosa and diffuse thinning of myometrium (B).

bladder, with tented bladder dome, suspicious of placenta praevia percreta.

She underwent bilateral internal iliac artery balloon occlusion, bilateral retrograde pyelogram with ureteric stenting and Caesarean hysterectomy at 37 weeks. Midline laparotomy with Classical uterine incision done followed by delivery of the baby. Intraoperatively noted bulging hypervascularized uterine lower segment with large vessels diffusely seen on uterine serosa, diffuse thinning of myometrium with areas appeared devoid of myometrium but with diffuse neovascularisation, and a large placenta occupying almost the entire anterior uterine wall. Massive obstetric haemorrhage due to placenta accreta spectrum with hypervascularisation and uterine atony complicated with approximately 8000 mL of blood loss, necessitated immediate multiple blood products replacement, of total 10 units of packed red blood cells, 8 units of fresh frozen plasma and 4 units of pooled platelet, and resort to total hysterectomy. Baby girl with birth weight of 2800 grams and major omphalocoele with liver and bowel content, required endotracheal intubation and NICU admission upon delivery. Postoperative recovery of mother was uneventful and she was discharged home on postpartum day 7. Histopathological analysis revealed placenta praevia major with percreta. Sections of uterus with placenta show focal areas displaying villi adhered directly to the thinned-out myometrium of less than 1 mm, without intervening decidua, and focal areas of placental uterine serosal breach and with presence of fibrin and blood.

DISCUSSION

Placenta accreta spectrum (PAS) commonly occurs among patients with previous cesarean scars, with the presence of placenta previa in the index pregnancy, and the likelihood of PAS increases proportionally with the number of previous cesarean deliveries. Other risk factors include increased maternal age, multiparity, other prior uterine surgery, prior uterine curettage, uterine irradiation, endometrial ablation, uterine synechiae, uterine leiomyomata, uterine anomalies, hypertensive disorders of pregnancy and smoking. Placenta accreta spectrum (PAS), formerly known as morbidly adherent placenta, refers to the range of pathologic adherence of the placenta, including placenta accreta, placenta increta and placenta percreta. The accepted hypothesis regarding the etiology of PAS is the defect of endometrial–myometrial interface leading to failure of normal decidualization especially in the area of a uterine scar, which facilitates abnormally deep placental anchoring villi and trophoblast infiltration.

Systemic lupus erythematosus (SLE) is an autoimmune disorder that can cause chronic inflammation, vasculitis, and diffuse thinning of the uterine myometrium, which may predispose patients to placental invasion even without prior cesarean or uterine scars. Emerging reports has shown SLE is linked to an elevated risk of abnormal placentation, including PAS.[1-5] This risk is heightened by long-term steroid therapy, which is hypothesized to cause muscle degeneration and diffuse uterine myometrial thinning. Furthermore, from the immunological perspective, autoimmune activity in SLE, can cause abnormal trophoblast invasion and poor placental anchoring. These conditions significantly increase the peril of severe obstetric hemorrhage, spontaneous uterine rupture, with maternal and neonatal morbidity and mortality.

This case illustrates the unusual complication of SLE, likely related to the peculiar condition of estrogen-mediated immune system, affecting uterine wall echo-structure.

Previous case reports hypothesized few theories including; chronic steroid exposure and SLE-induced antiestrogenic effect contributing to uterine wall thinning by inhibiting myometrial hypertrophy and endothelial proliferation, whereas complement cascade activation causes uterine microvasculature damage, and chronic inflammation contribute to endo-myometrial layer damage.[1-5]

Nevertheless the pathophysiology of the association between SLE and extensive PAS remains unclear, it is plausible that myometrial thinning resulting from chronic steroid exposure may contribute to this rare occurrence.

CONCLUSION

Pregnancy in SLE, which is a multisystemic autoimmune disorder with heterogeneous manifestations, poses higher risks of adverse pregnancy outcomes. PAS with various degrees of abnormally invasive placentation is associated with severe maternal morbidity and mortality.

SLE in pregnancy with coexisting PAS elicits great challenge in managing. Thus, a precise prenatal diagnosis of PAS is crucial for optimal perioperative optimization and preparation involving multidisciplinary approach to minimize complications to both, mother and baby.

PAS is rare among nulliparous women and unusual on an unscarred uterus. However, preexisting SLE with prolonged steroid consumption may be a rare risk factor for PAS especially in placenta previa, which necessitates a comprehensive prenatal evaluation and diagnosis.

ACKNOWLEDGEMENT

We would like to thank the patient and her spouse for their cooperation and agreement to publish this case. We are very grateful to Dr Koh SH (Radiologist) who helped with MRI image and description.

DECLARATION

The authors declare no conflicts of interest to disclose in relation to this work. There was no funding received.

REFERENCES

1. Mittal N, Pineda M, Lim B, Carey E. Placenta Previa Increta in an Unscarred Uterus with Marked Thinning of Myometrium in the Entire Uterus in a Patient with Systemic Lupus Erythematosus. Int J Gynecol Pathol 2018; 37(2): 198-203.
2. Sherer DM, Thompson M, Field A, Granderson F, Dalloul M. Extensive fundal placenta accreta spectrum (PAS) in a nulliparous patient with an unscarred uterus and systemic lupus erythematosus (SLE) necessitating cesarean hysterectomy at delivery. Radiol Case Rep 2023; 18(11): 4057-61.
3. Mitoma T, Hayata K, Yokohata S, Ohira A, Kashino C, Kirino S, et al. Diffuse myometrium thinning and placenta accreta spectrum in a patient with systemic lupus erythematosus (SLE): a case report and review of the literature. BMC Pregnancy Childbirth 2022; 22(1): 535.
4. de Jesus GR, Mendoza-Pinto C, de Jesus NR, Dos Santos FC, Klumb EM, Carrasco MG, et al. Understanding and Managing Pregnancy in Patients with Lupus. Autoimmune Dis 2015: 943490.
5. Liu J, Liu C, Zuo X, Teng Y. Pernicious placenta previa/placenta percreta complicating active systemic lupus erythematosus resulting in postoperative artery thrombosis. J Int Med Res 2019; 47(12): 6365-73.

CASE REPORT

Clostridium tetani bacteremia without classical tetanus: A lesson from Malaysia

Muhammad Hashemi Dahalan Md Razip, MRCP, Gan Wee Fu, FRCP

Infectious Disease Unit, Internal Medicine Department, Malacca Hospital, Melaka, Malaysia

SUMMARY

Clostridium tetani infection classically presents as a toxin-mediated neuromuscular disease, while invasive bloodstream infection is exceptionally rare. In regions with low tetanus incidence, atypical presentations may delay recognition and definitive management. We report a 61-year-old Malay man with long standing schizophrenia who presented with a two-week history of progressive right lower limb pain and blackish discoloration following a fall. Clinical examination and imaging were consistent with gas gangrene. Despite early broad-spectrum antibiotics, definitive surgical source control was delayed due to challenges in obtaining informed consent. The patient underwent right above knee amputation (AKA) but subsequently deteriorated with septic shock, respiratory failure, and pulmonary embolism. Blood cultures obtained during clinical deterioration yielded Clostridium tetani. He succumbed despite active resuscitation. This case illustrates a rare and fulminant presentation of Clostridium tetani bacteremia arising from necrotizing soft tissue infection without classical neurological features of tetanus. To our knowledge, this is the first case of Clostridium tetani bacteremia reported in Malaysia. Early recognition, prompt antimicrobial therapy, assessment of tetanus immunization status, timely administration of tetanus immunoglobulin, and urgent surgical source control remain critical to improve outcomes in similar cases.

INTRODUCTION

Tetanus came from a Greek word tetanos that was derived from teinein meaning to stretch. It was first described in Egypt over 3000 years ago. Clinical disease is typically mediated by neurotoxins responsible for the characteristic features of muscular rigidity and spasms. It is rare cases nowadays due to the effectiveness of vaccination program but potentially fatal if it is missed. Despite this success, low disease prevalence may reduce clinical vigilance and delay recognition, particularly when presentations deviate from classical neuromuscular manifestations. Although Clostridium tetani is well recognized as a toxin-producing pathogen, invasive infection with documented bacteremia is exceedingly rare and sparsely reported in the literature. Such presentations may mimic other necrotizing soft tissue infections and obscure the underlying diagnosis. Hereby, we describe a fatal case of Clostridium tetani bacteremia arising from necrotizing soft tissue infection in a patient without classical features of tetanus. This report highlights the diagnostic and management challenges posed by atypical disease presentations in low-incidence settings and underscores the importance of early suspicion, prompt treatment with antibiotics, immunoglobulins, vaccinations and timely surgical source control.

CASE PRESENTATION

We reported a 61 years-old Malay gentleman who lived alone, with a known case of schizophrenia for the past 20 years under primary health care follow up, on Zuclopenthixol 10 drops twice daily. He was brought to emergency department by ambulance complaining of right lower limb pain and blackish discoloration for two weeks prior to admission. He had a preceding history of a fall, after which he experienced persistent right hip pain and inability to ambulate. He denied any history of insect bites, open wounds, or fever.

On initial assessment, he was alert and oriented but appeared unkempt. His blood pressure was 167/85 mmHg, heart rate of 92 beats per minute, and capillary blood glucose of 10.4 mmol/L. Examination of the right lower limb revealed extensive blackish discoloration involving the entire leg, extending until above the knee, with foul smelling and palpable crepitus. Distal pulses were not palpable, except for the right femoral pulse. There was marked tenderness over the right hip.

Plain radiography of the right lower limb demonstrated extensive gas shadows extending up to the upper thigh. Pelvic and right hip radiographs showed no evidence of fracture. Initial laboratory investigations revealed leukocytosis with a total white cell count of 16.2 $\times 10^9$/L and elevated C-reactive protein of 281 mg/L. The rest of blood investigations were unremarkable except hyponatremia with sodium of 126mmol/L with mild elevation of lactate of 2.4 mmol/L without any metabolic acidosis, as shown by Table 1.

A diagnosis of gas gangrene of the right lower limb was made. The patient was immediately commenced on intravenous piperacillin–tazobactam 4.5g stat followed by 6-hourly dosing. Urgent right AKA was planned. However, surgical intervention was delayed due to difficulty of obtaining informed consent because of his underlying psychiatric illness and difficulty to reach his family members. Right AKA with partial closure of the distal stump was performed three days after his admission. Intraoperatively, there was necrosis and edema of the medial compartment

This article was accepted: 02 August 2026
Corresponding Author: Muhammad Hashemi Dahalan bin Md Razip
Email: hashemidahalan@gmail.com

Table I: Table of serial blood investigations

Laboratory test	Reference Range (Units)	20/4/24 (Admission)	27/4/24 Day 7 (deterioration)	1/5/24 Day 11
Hemoglobin	13.0 – 17.0 (g/dL)	16.1	14.4	13.4
White cell count	4.0 - 10.0 (10^9/L)	16.2	22.7	21.1
Platelet	150 – 410 (10^9/L)	187	296	220
Urea	3.2 – 8.2 (mmol/L)	5.2	5.3	14.6
Creatinine	62 – 115 (umol/L)	64	60	105
Sodium	136 – 145 (mmol/L)	126	129	161
Potassium	3.5 – 5.1 (mmol/L)	4.9	3.5	4.2
Chloride	98 – 107 (mmol/L)	91	98	121
Total protein	57 – 82 (g/L)	61	60	
Albumin	32 – 48 (g/L)	32	29	
Total Bilirubin	<21 (umol/L)	16.4	8.8	
Alanine Transferase (ALT)	10 – 49 (U/L)	118	139	
Alkaline Phosphate (ALP)	46 – 116 (U/L)	144	205	
Aspartate Transaminase (AST)	<34 (U/L)	113		
Calcium	2.18-2.60 (mmol/L)		2.23	1.88
Phosphate	0.78-1.65 (mmol/L)		1.53	1.26
Magnesium	0.53-1.11 (mmol/L)		0.85	0.93
C-Related Peptide, CRP	<10 (mg/L)	281	253	268
PT	9.4 - 11.0 (sec)	11.8	16.3	13.0
INR	0.87 - 1.03	1.14	1.61	1.27
aPTT	22.2 - 31.0 (sec)	32.1	39.1	32.4
pH	7.35 – 7.45 (mmHg)		7.26	7.62
partial oxygen	83 – 108 (mmHg)		136	140
partial carbon dioxide	35 – 48 (mmol/L)		34	25
bicarbonate	18 – 23 (mmol/L)		13.9	25.7
Base excess			-12	5.5
oxygen saturation	95 – 98 (%)		99	100
lactate	0.5 – 2.2 (mmol/L)	2.4	8.0	
D-dimer	<0/5 (mg/L)		2.31	

Cultures Summary

Type of cultures	Date	Result
Tissue	23/4/24	No Growth
Blood	27/4/24	Clostridium tetani

muscles with sloughy tissue, while the anterior and posterior compartments appeared viable. The patient was transferred back to the general orthopedic ward with a plan for secondary wound closure later. Intraoperative tissue cultures showed no microbial growth. The patient was successfully extubated postoperatively and demonstrated initial clinical improvement. However, the surgical wound remained unsatisfactory, with persistent slough, non-viable muscle tissue, macerated surrounding skin, and pale bluish discoloration despite regular wound care.

On post-operative day four, he was found gasping with a sudden drop in Glasgow Coma Scale (GCS) to E4V1M1 and hypoglycemia (capillary blood glucose 3.3 mmol/L). His blood pressure was 128/77 mmHg and tachycardia at 120 beats per minute. Oxygen saturation was 80% under room air and remained critically low (70–80%) despite on high flow mask oxygen therapy. He was intubated for respiratory distress and reduced consciousness, subsequently requiring inotropic support. A computed tomography pulmonary angiogram (CTPA) revealed pulmonary embolism involving the distal right pulmonary artery with extension into the right ascending and descending pulmonary arterial branches. Computed tomography (CT) brain showed no intracranial haemorrhage.

Wound inspection during his deterioration revealed macerated skin, foul odor, and necrotic tissue extending proximally toward the right hip. A plan for further surgical debridement and possible hip disarticulation was made. Unfortunately, the patient experienced cardiac arrest and passed away after 11 days of hospitalization despite active resuscitation. Blood culture obtained during his clinical deterioration on day seven of admission yielded Clostridium tetani.

DISCUSSION

Tetanus is a toxin-mediated, non-communicable, potentially fatal disease caused by Clostridium tetani, an obligate anaerobic, gram-positive, spore-forming bacillus that is ubiquitous in the environment. In Malaysia, tetanus remains uncommon, with an incidence of 0.09 per 100,000 population according to Health Facts 2024 published by the Ministry of Health Malaysia.[1] While this reflects successful national immunization efforts, the rarity of the disease may contribute to reduced clinical familiarity and delayed recognition, particularly in atypical presentations. Despite advances in critical care, generalized tetanus continues to be associated with a mortality rate of 10–20%.

Table I: Table of serial blood investigations

Case number	Author, Country	Year	Age, Gender	Clinical presentation	investigation	Source	Treatment	Outcome
1	Rabih Riad Hallit et al, USA	2012	87 years old, Female	Generalized weakness and diarrhea for 3 days	Blood culture: C. tetani, colonoscopy : moderately severe colitis, diverticulosis, internal haemorrhoids	Gastrointestinal	Metronidazole, booster dose of the tetanus and diphtheria (Td) vaccine	Alive
2	Chih-Cheng Lai et al, Taiwan	2018	73 years old, Male	fever, chills, vomiting and general weakness for 1 day, 4 days after TAE for HCC	Blood culture: C. tetani	Gastrointestinal	Metronidazole	Alive
3	Kazadi D et al, USA	2022	86 years old, Male	Found on ground after unwitnessed fall with history of left leg pain prior	Blood culture: non perferingens C. spp, sacral ulcer cultures: Clostridium inocuum and Clostridium sporogenes	Cutaneous (blistering ulceration left leg and sacral ulcer)	IV Piperacillin-Tazobactam, IV Vancomycin, debridement of sacral and left lower extremities ulcer	Alive
4	Our patient, Malaysia	2024	61 years old, Male	Right lower limb pain for 2 weeks	Blood culture: C. tetani	Cutaneous	IV Piperacillin-Tazobactam, right AKA	Deceased

The clinical manifestations of tetanus are primarily mediated by tetanospasmin, a potent neurotoxin that inhibits the release of inhibitory neurotransmitters, resulting in sustained muscle rigidity and painful spasms as shown in Figure 1. Classical features include trismus, neck stiffness, and generalized muscle rigidity, which may progress to respiratory failure and autonomic dysfunction. However, not all Clostridium tetani infections present with the characteristic neurological syndrome, creating diagnostic challenges and potentially delaying appropriate prophylactic measures.

As mentioned, Clostridium tetani is classically associated with toxin-mediated neuromuscular disease however, invasive bloodstream infection can occur. A limited number of cases of Clostridium tetani bacteremia have been reported in the literature, as summarized by Boualam et al.[2] To our knowledge, this case represents the second reported case of confirmed Clostridium tetani bacteremia arising from a cutaneous source following the report by Kazadi et al.[3], and the first documented case from Malaysia. The present case highlights the capacity of Clostridium tetani to cause severe invasive disease with a fulminant clinical course even in the absence of classical neurological manifestations.

The diagnosis of Clostridium tetani bacteremia was established through blood culture. A paired blood culture set became positive after 46 hours of incubation, with growth detected in the anaerobic bottle. Identification of the isolate was identified by MALDI-TOF mass spectrometry and was verified by microbiologist. Antimicrobial susceptibility testing was not done, as there are currently no guideline recommendations for routine susceptibility testing of Clostridium tetani. The isolation of Clostridium tetani from blood culture in the context of cutaneous and soft tissue source strongly supports its pathogenic role and against specimen contamination.

At present, there is also no definitive consensus guideline for the management of Clostridium tetani bloodstream infection. Consequently, treatment strategies are largely guided by expert opinion and source control principles. Review of previously reported cases as shown in Table II demonstrates that empiric antimicrobial therapy was directed according to the suspected source of infection. Intravenous metronidazole was administered in cases with presumed gastrointestinal sources, whereas piperacillin–tazobactam was used in cases involving skin and soft tissue infection, including our patient. Surgical debridement remains a cornerstone of management, as it removes necrotic tissue, reduces bacterial burden, eradicates spores, and limits ongoing toxin production. Delayed source control in our patient may have contributed to persistent infection and clinical deterioration.

An additional consideration in this case was the presence of pulmonary embolism, which may have contributed to the patient's worsening clinical condition and eventual death. Although severe soft tissue infection and septic complications likely represented the primary drivers of clinical decline, pulmonary embolism may have further compromised cardiopulmonary reserve and exacerbated tissue hypoxia.

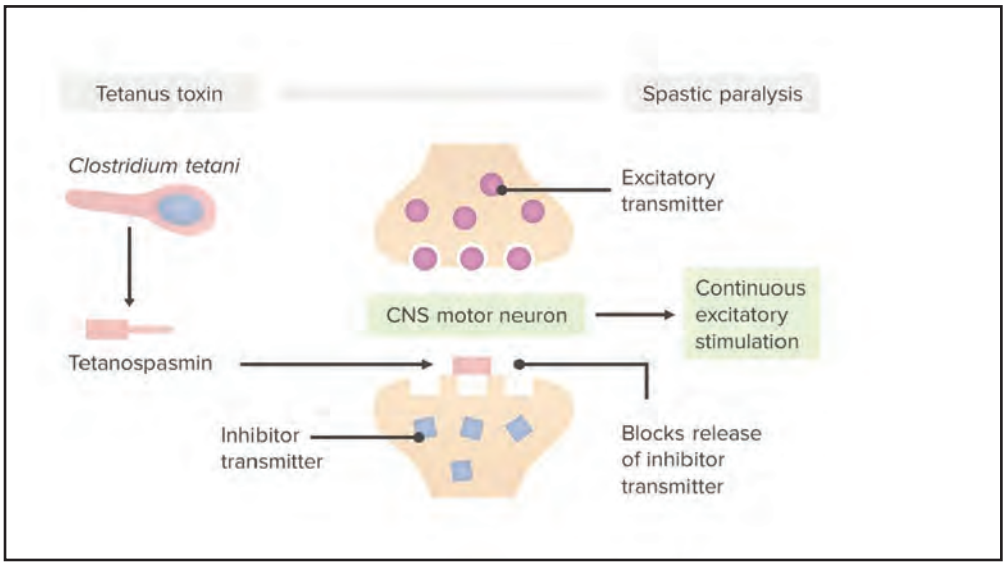

Fig. 1: Schematic illustration of pathophysiology in tetanus induced spastic paralysis: in an anaerobic environment (e.g. during active inflammation from the contaminated tissue) C. tetani spores germinate and produce the tetanospasmin toxin. Tetanospasmin binds to the presynaptic neuron, eventually allowing the light chain part of the protein to reach the spinal cord. The toxin specifically enters the central inhibitory neurons, prohibiting the release of GABA- and glycine containing vesicles from the cell membrane. This results in a loss of inhibition and subsequently continuous excitatory stimulation in motor neurons and the autonomic nervous system, causing uncontrolled motoric contractions[4]

Given the multifactorial nature of the patient's deterioration, it is difficult to determine the relative contribution of each process however, pulmonary embolism should be recognized as a potentially important coexisting factor influencing the fatal outcome.

Several important clinical challenges were illustrated by this case. First, delayed presentation to healthcare services, likely influenced by underlying psychosocial factors, resulted in extensive soft tissue involvement at the time of diagnosis. Second, definitive surgical source control was delayed because the patient lacked the capacity to provide informed consent, creating ethical and legal complexities that hindered timely intervention. Third, the atypical presentation, which was more consistent with an invasive soft tissue infection than classical tetanus, contributed to the omission of early tetanus vaccination and tetanus immunoglobulin administration. Collectively, these factors likely contributed to disease progression and limited opportunities for effective source control.

This case highlights the importance of assessing tetanus immunization status in all patients with tetanus prone wounds requiring post-exposure prophylaxis. Among previously reported cases in Table II, only one patient received a tetanus booster vaccination, while the remainder did not receive either a tetanus vaccine or human tetanus immunoglobulin. Current national recommendations advise administration of a tetanus vaccine and human tetanus immunoglobulin when vaccination history is uncertain or when wounds are considered high risk.[5] Unfortunately, our patient's immunization status could not be verified, and neither a tetanus vaccine nor tetanus immunoglobulin was administered during hospitalization. From a broader public health perspective, this case reinforces the importance of maintaining adequate tetanus immunity throughout adulthood. Routine tetanus booster vaccination is generally recommended every 10 years as per the National Vaccine-Preventable Diseases Recommendation for Older Adults published in 2025.[5] Although widespread childhood immunization has markedly reduced the incidence of tetanus, waning immunity remains a concern in adults. Greater awareness among healthcare professionals and the public regarding routine booster vaccination and appropriate post-exposure prophylaxis may help prevent both classical tetanus and invasive Clostridium tetani infections.

CONCLUSION

This case demonstrates that Clostridium tetani can present as a fulminant invasive bloodstream infection without classical neurological manifestations of tetanus. Failure to recognize atypical presentations may result in delayed prophylaxis, postponed surgical intervention, and missed opportunities for escalation of care. Clinicians should maintain a high index of suspicion for tetanus related infection in patients presenting with necrotizing soft tissue infection of unclear aetiology, even in the absence of trismus or muscle spasms. Early recognition, prompt antimicrobial therapy, timely surgical source control, and appropriate administration of tetanus vaccine and immunoglobulin remain essential components of management and may improve outcomes in similar cases.

ACKNOWLEDGEMENTS

The authors thank all those involved in the patient's care and extend their respect to the patient.

CONFLICT OF INTEREST STATEMENT

The authors declare that there are no financial, personal, or professional relationships that could have influenced the work reported in this case report.

REFERENCES

1. Ministry of Health Malaysia. Health Facts 2024: Incidence Rate and Mortality Rate of Communicable Diseases, 2023. Putrajaya: Ministry of Health Malaysia; 2024. Available from: https://www.moh.gov.my/moh/resources/Penerbitan/Penerbitan%20Utama/HEALTH%20FACTS/Health_Facts_2024.pdf
2. Boualam MA, Bouri A, Signoli M, Drancourt M, Caputo A, Terrer E, et al. Clostridium tetani bacteraemia in the plague area in France: Two cases. Curr Res Microb Sci 2025; 8: 100339.
3. Kazadi D, Zychowski D, Skipper C, Teravskis P, Hansen GT, Ordaya EE. Clostridium tetani bacteremia from a suspected
4. Boer M, Voogd M, Niemeijer N, van der Hoeven L. Tetanus: a case report highlighting the challenges in diagnosis and treatment. Trop Dis Travel Med Vaccines. 2024; 10: 10.
5. Malaysian Society of Geriatric Medicine. All You Need to Know: Diphtheria, Tetanus, Pertussis. In: National Vaccine-Preventable Diseases Recommendation for Older Adults. Petaling Jaya: Malaysian Society of Geriatric Medicine; 2025. p. 28-34. Available from: https://www.msgm.com.my/_files/ugd/b90e70_9838f6ccd11d4d2e91f55d59526d07a0.pdf

Culture-proven Streptococcus viridans endophthalmitis in a healthy child: Challenges in determining the source of infection

Derrick Chuah Jun Quan, MD[1,2], Grace Tan Zhen Wen, MBBS[1], Akmal Haliza Zamli, MOphthal[1], Shahidatul-Adha Mohamad, MMed[2]

[1]Department of Ophthalmology, Hospital Tengku Ampuan Afzan, Kuantan, Pahang, Malaysia, [2]Department of Ophthalmology and Visual Science, School of Medical Sciences, Universiti Sains Malaysia, Health Campus, Kubang Kerian, Kelantan, Malaysia

SUMMARY

Endophthalmitis is a vision-threatening intraocular infection requiring urgent diagnosis and treatment. Determining the route of infection may be challenging, particularly in children with limited history and multiple potential sources. A 4-year-old indigenous boy presented with unilateral ocular redness and reduced vision three days after a reported minor ocular injury. Examination of the affected eye revealed mild conjunctival injection, intense anterior chamber inflammation with hypopyon, together with dense vitritis. There was no evidence of a corneal infiltrate or penetrating ocular injury. Imaging excluded an intraocular foreign body. Urgent vitreous tap followed by intravitreal vancomycin, ceftazidime, and amphotericin B was performed. Vitreous culture grew Streptococcus viridans, while blood cultures and systemic investigations were unremarkable. Further assessment identified early childhood caries; however, no other definitive source of infection could be established. The patient demonstrated marked clinical improvement following intravitreal and systemic antimicrobial therapy. This case highlights the challenges of determining the source of infection in paediatric endophthalmitis and emphasizes the importance of prompt microbiological sampling and early treatment, even when the route of infection remains uncertain.

INTRODUCTION

Endophthalmitis is a vision-threatening intraocular infection that constitutes an ophthalmic emergency requiring prompt diagnosis and treatment. It is broadly classified as exogenous, resulting from direct microbial inoculation following trauma or surgery, or endogenous, arising from haematogenous spread from a distant infectious focus.[1] Endogenous endophthalmitis is uncommon in children and is typically associated with an identifiable systemic source of infection.[2] Dental-associated endogenous endophthalmitis is exceedingly rare, with only isolated cases reported in adults.[3-4] We report a case of culture-proven Streptococcus viridans endophthalmitis in a healthy child with dental caries as the only identifiable potential source of infection. The diagnosis was further complicated by a history of minor ocular trauma, which initially raised concern for an exogenous aetiology.

CASE PRESENTATION

A 4-year-old indigenous boy presented with left-eye redness and reduced vision three days after a reported ocular injury. He had no known medical comorbidities, and his immunisations were up to date. According to his caretaker, the incident was witnessed by a teacher, who reported that another child had thrown a pencil; however, it was unclear whether the eye had been directly struck. Following the incident, the child remained systemically well and afebrile. There was no history of toothache, gum swelling, facial pain, or recent dental procedures. The father reported frequent exposure to soil and muddy water, and that the family kept an unvaccinated feral cat.

On examination, visual acuity was 6/9 in the right eye and 6/36 in the left, with no relative afferent pupillary defect. The left eye demonstrated mild conjunctival injection with intense anterior chamber inflammation, including 4+ cells, a 1-mm hypopyon, and a small organised fibrinous exudate (Fig. 1). The cornea was clear, with no epithelial defect, stromal infiltrate, or keratic precipitates. There was no evidence of self-sealed corneal wound or other penetrating ocular injury. The lens was clear with no capsular breach. Fundus examination was limited by dense vitritis. B-scan ultrasonography demonstrated vitreous opacities consistent with vitritis (Fig. 2). The right eye was unremarkable.

Given the presence of hypopyon and vitritis, a diagnosis of endophthalmitis was made and urgent treatment initiated. Intravenous ciprofloxacin was immediately commenced together with intensive topical moxifloxacin and atropine 1%. The child underwent an urgent vitreous tap and aqueous paracentesis for microbiological analysis, followed by intravitreal injection of vancomycin (1 mg/0.1 mL), ceftazidime (2 mg/0.1 mL), and amphotericin B (5 mcg/0.1 mL) under general anaesthesia.

The possible route of infection was investigated concurrently. In view of the reported ocular trauma, an exogenous source was initially considered. Skull radiography and urgent non-contrast CT orbit excluded an intraocular foreign body. The child was co-managed with the paediatric team for systemic evaluation and investigation of a possible endogenous source of infection. Full blood count, C-reactive protein and other

This article was accepted: 06 August 2026
Corresponding Author: Shahidatul Adha Mohamad
Email: shieda@usm.my



Fig. 1: Slit-lamp examination of the left eye showing mildly injected conjunctiva, hypopyon and a small, organised fibrinous inflammatory exudate within the anterior chamber; the cornea was otherwise clear

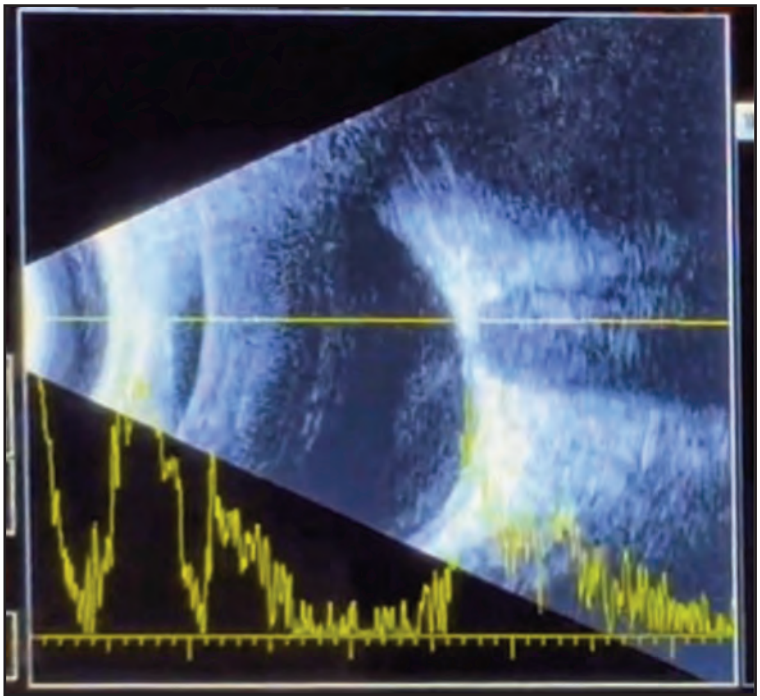

Fig. 2: B-scan of the left eye showing vitreous opacities suggestive of vitritis.



Fig. 3: Intraoral photograph demonstrating caries involving the primary molars

inflammatory markers were within normal limits, while blood, urine and aqueous humour cultures showed no growth. Given the history of cat exposure, empirical coverage for cat-scratch disease was initiated, and intravenous antibiotics were rationalised to ceftazidime. Vitreous culture isolated alpha-haemolytic Streptococcus viridans, which was sensitive to chloramphenicol and cefotaxime. Serological testing for Bartonella henselae and melioidosis subsequently returned negative. Dental assessment identified caries involving the primary molars, although no dental abscess or other focus of infection was identified. Dental treatment comprising caries removal, restoration, and fluoride varnish application was performed (Fig. 3).

The patient demonstrated a favourable clinical response to intravenous ceftazidime, with complete resolution of the hypopyon, anterior chamber inflammation, and vitritis after two weeks of treatment. No repeat intravitreal antibiotic injections or pars plana vitrectomy were required. Visual acuity improved from 6/36 to 6/9 in the affected eye. Fundus examination at discharge demonstrated a clear view of the posterior pole, with a healthy optic disc and retina.

DISCUSSION

Determining the route of infection represented the principal diagnostic challenge in this case. Paediatric endophthalmitis is uncommon and most frequently occurs following penetrating ocular trauma or intraocular surgery, whereas endogenous infection accounts for a relatively small proportion of cases.[1-2,5] In a recent series of paediatric endogenous endophthalmitis, most children had an identifiable systemic focus of infection, including respiratory tract infections, urinary tract infections, sepsis, and septic arthritis.[2,5] Unlike these commonly reported sources, the only identifiable potential source in our patient was dental caries involving the primary molars. Despite extensive investigations, no definitive systemic focus of infection was identified.

The reported history of minor ocular trauma initially raised concern for exogenous endophthalmitis secondary to direct inoculation. However, this explanation became less convincing following clinical examination and imaging. No corneal wound, scleral laceration, lens breach, or other evidence of penetrating ocular injury was identified, while skull radiography and CT orbit excluded an intraocular foreign body. Although a self-sealed occult injury cannot be entirely excluded, the absence of supporting clinical findings reduced the likelihood of a traumatic source.

The isolation of Streptococcus viridans from the vitreous specimen prompted consideration of an endogenous source. Viridans streptococci are common oral commensals frequently associated with dental plaque and dental caries.[6-7] Dental assessment identified caries involving the primary molars, raising suspicion of a possible oral source. Dental-associated endogenous endophthalmitis appears to be exceedingly rare.[8] Published reports have been limited to adults, including a case associated with a dental abscess and another occurring after a mild dental infection in an otherwise healthy individual.[3-4] To our knowledge, previously reported dental-associated endogenous endophthalmitis has been limited to adults.

Nevertheless, direct evidence linking the dental findings to the ocular infection was lacking in our case. Although dental assessment identified caries involving the primary molars, cultures were not obtained from the affected teeth, preventing direct confirmation that the dental lesions harboured the same organism isolated from the vitreous sample. Furthermore, there was no evidence of dental abscess, periodontal infection, or other overt odontogenic sepsis. Consequently, while an endogenous oral origin remained the most plausible explanation, causality could not be definitively established.

Although blood cultures were negative, transient bacteraemia cannot be excluded, as viridans streptococci may enter the bloodstream following disruption of the oral mucosal barrier and such episodes are often brief and may not be captured by routine blood cultures. Endogenous endophthalmitis occurs when microorganisms disseminate via the bloodstream and seed the highly vascular choroidal circulation before extending into the retina and vitreous cavity.[1,8] Therefore, transient haematogenous spread remains the most plausible explanation linking the isolation of Streptococcus viridans to the concurrent dental caries in our patient. Given the patient's frequent exposure to muddy soil and feral cats, atypical infectious causes such as melioidosis and Bartonella henselae infection were also considered; however, investigations for these conditions were negative.

Regardless of the route of infection, management of suspected endophthalmitis should not be delayed while attempting to identify the source. Early vitreous sampling remains essential for microbiological diagnosis and facilitates targeted antimicrobial therapy.[8-9] In our patient, prompt vitreous tap followed by intravitreal broad-spectrum antimicrobial therapy resulted in rapid resolution of intraocular inflammation and favourable clinical recovery. The positive vitreous culture proved particularly valuable, as extensive systemic investigations failed to identify a definitive source of infection.

CONCLUSION

Determining the source of infection in paediatric endophthalmitis may be challenging, particularly when multiple potential aetiologies exist. Regardless of the route of infection, early recognition of endophthalmitis, urgent vitreous sampling with prompt intravitreal antimicrobial therapy, and appropriate systemic antimicrobial treatment remain crucial for achieving favourable visual outcomes.

DECLARATIONS

Written informed consent for publication was obtained from the patient's parent. The authors declare no conflicts of interest. No financial support or funding was received for this work. All authors have read and approved the final manuscript.

REFERENCES

1. Tabatabaei SA, Masoumi A, Mirzaei A, Mirshahi R, Momenaei B, Bijani FM, et al. Infectious endophthalmitis: an overview of clinical features, microbiology profile, and antibiotic sensitivity pattern. J Curr Ophthalmol 2024; 36(3): 284-90.
2. Dorairaja T, Ab Kadir AJ, Rahmat J. Paediatric endophthalmitis: a 10-year retrospective study at Hospital Kuala Lumpur for incidence, risk factors, and outcomes. Malays J Ophthalmol 2022; 4(2): 157-70.
3. Mascali R, Berguiga M, Delhoum S, Le Loir M, Cochard-Marianowski C, Cochener B, et al. Endogenous bacterial endophthalmitis related to dental abscess: case report. J Fr Ophtalmol 2012; 35(1): 35-9.
4. Hoopes H, Cloutier N. A case of endogenous endophthalmitis after a mild dental infection. J Am Coll Emerg Physicians Open 2021; 2(5): e12557.
5. Nanda R, Das T, Padhi TR, Panda KG, Ger M, Padhy SK. Pediatric endogenous endophthalmitis: Clinical features and treatment outcomes. Indian J Ophthalmol 2025; 73(5): 665-71.
6. Santin K, Bispo PJ, Rocchetti TT, Denadai L, Martins WM, Carmo MS, et al. Characterization and distribution of viridans group streptococci isolated from infectious endophthalmitis and keratitis. Arq Bras Oftalmol 2021; 83: 463-72.
7. Ahmed NA, Tariq P, Naim A. Viridans group Streptococci and dental caries: an overview. Int J Biol Biotech 2023; 20(1): 3-16.
8. Xie CA, Singh J, Tyagi M, Androudi S, Dave VP, Arora A, et al. Endogenous endophthalmitis-a major review. Ocul Immunol Inflamm 2023; 31(7): 1362-85.
9. Hu M, Liu M, Jin S, Wang X, Liu X. Clinical features, treatment and prognosis of patients with endogenous infectious endophthalmitis. Int Ophthalmol 2024; 44(1): 321.

Pulse corticosteroid therapy in post-keratoplasty graft rejection: A strategy to restore vision

Muhammad Syazani I[1,2], Julieana Muhammed[1,2]

[1]Department of Ophthalmology and Visual Science, School of Medical Sciences, Health Campus Universiti Sains Malaysia, Kubang Kerian, Kelantan, [2]Hospital Pakar USM, Kubang Kerian, Kelantan

SUMMARY

A case of corneal graft rejection following penetrating keratoplasty (PK) successfully managed with pulse corticosteroid therapy, leading to the reversal of graft rejection and restoration of vision. We present a case of a 35-year-old female with bilateral keratoconus who underwent PK for the left eye. The patient developed early graft rejection within two weeks postoperatively, presenting with conjunctival injection, corneal infiltrates and limbal vascularisation. Intensive topical and systemic therapy, including intravenous methylprednisolone pulse therapy (500 mg daily for three days), was administered, followed by oral corticosteroids and adjunctive treatments. Following pulse corticosteroid therapy, the patient exhibited significant improvement, with resolution of graft rejection signs and visual acuity recovery to 6/12 (pinhole 6/9) four months post-PK. Early recognition and aggressive management of graft rejection are critical for corneal graft survival. Pulse corticosteroid therapy offers a rapid and effective approach in reversing severe rejection while minimising prolonged systemic corticosteroid exposure.

INTRODUCTION

Corneal graft rejection is a sight-threatening complication that can occur after penetrating keratoplasty, potentially resulting in substantial endothelial cell loss and corneal decompensation.[1-2] Factors that increase the risk of corneal graft rejection include donor age, graft size, multiple graft procedures, a history of graft rejection and corneal vascularisation, as all these factors compromise innate immunological privilege.[1] Corneal transplant may be indicated in various conditions such as corneal ectasia, bullous keratopathy, stromal dystrophies, Fuchs' endothelial dystrophy, scarring, perforation or failure of a previous graft.[3] Early diagnosis of corneal rejection and timely treatment are essential to reduce visual morbidity and preserve the corneal transplant. We report this case in view of limited evidence regarding the use of systemic pulse corticosteroid in managing graft rejection following penetrating keratoplasty.

CASE PRESENTATION

A 35-year-old lady with history of allergic rhinitis, bronchial asthma, and hypertension presented with acute hydrops in the left eye in December 2023. She had been diagnosed with bilateral keratoconus in Glasgow in 2014 but had defaulted on follow-up. Her younger sister also has keratoconus, indicating a possible familial predisposition. Upon presentation, her best-corrected visual acuity (BCVA) was 6/24 in the right eye (RE) and counting fingers in the left eye (LE). Examination revealed signs of advanced keratoconus in both eyes. Munson's sign, prominent corneal nerves, Rizzuti sign and Vogt's striae were noted in the RE, while the LE showed central corneal oedema with bullae. Initial treatment included topical corticosteroids, antibiotic, hypertonic saline and atropine.

On August 7, 2024, she underwent penetrating keratoplasty (PK) for the left eye. Intraoperatively, the donor cornea exhibited a total epithelial defect and oedema. Postoperatively, her vision improved to 6/18 by the third day. However, complications arose on the twelfth postoperative day, including early graft rejection characterised by conjunctival injection, corneal infiltrates, epithelial defect and limbal vascularisation. These were managed with intensive antibiotics, topical corticosteroids and systemic doxycycline. Corneal re-suturing was performed two weeks later due to loose sutures, improving her vision to 6/60 (pinhole 6/12).

The patient was closely monitored for progressive corneal infiltrates by means of weekly review. On subsequent review, the condition worsened significantly. Corneal infiltrates were noted at 5 o'clock position at two points, involving the graft-host junction (GHJ) and the recipient tissue, corneal oedema extending from 4-7 o'clock at the GHJ. Superficial limbal vascularisation was present between 11 to 1 o'clock without compromising the GHJ. These findings warranted hospital admission for intravenous methylprednisolone pulse therapy (500mg daily for 3 days).

The patient was discharged on oral prednisolone 60 mg daily and topical corticosteroids and topical lubricant hourly together with hypertonic saline 3% every four hours to manage corneal oedema. Antibiotic coverage included topical levofloxacin and oral doxycycline. Additional supportive treatments included oral vitamin C to aid corneal wound healing and topical olopatadine 0.1% twice daily for allergic symptom control.

Two months post-PK, the patient developed steroid-induced ocular hypertension, with intraocular pressures (IOP) of 22 mmHg in the RE and 28 mmHg in the LE. This was addressed by rapidly tapering topical corticosteroid, switching from prednisolone acetate to fluorometholone (FML) and initiating dorzolamide eye drops.

This article was accepted: 17 August 2026
Corresponding Author: Muhammad Syazani Ibrahim
Email: syazani101@gmail.com

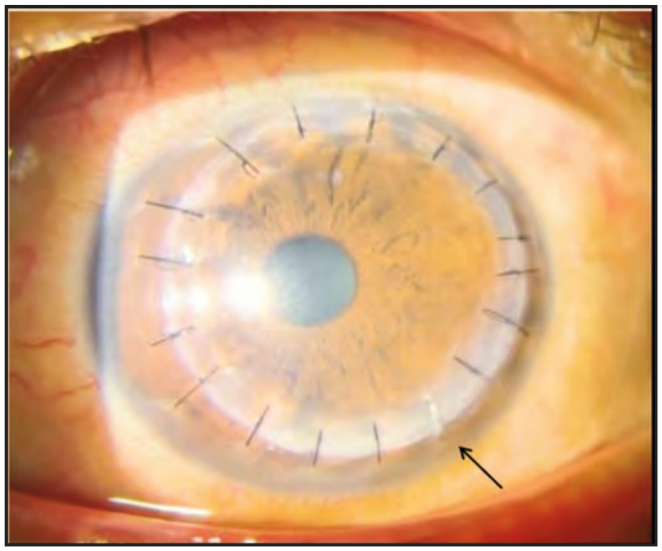

Fig. 1: The left eye of the patient demonstrates a corneal infiltrate (indicated by the arrow)

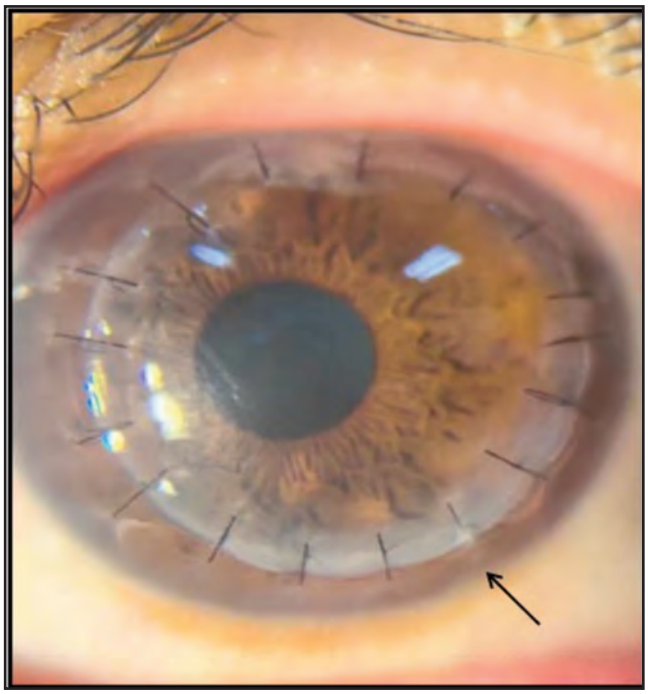

Fig. 2: The left eye showed remarkable resolution of the infiltrate after pulse methylprednisolone (indicated by the arrow)



Fig. 3: The left eye demonstrates complete resolution of the corneal infiltrate four months postoperatively, with restored graft clarity and no signs of active rejection

At four months post-PK, the patient's LE vision had improved to 6/12 (pinhole 6/9), with no signs of graft failure. Examination revealed intact sutures, mild subepithelial haze and no significant vascularisation involving the graft-host junction. The RE, affected by severe keratoconus, is planned for corneal cross-linking to prevent further progression. Her treatment regimen included oral prednisolone, topical antibiotics, topical corticosteroid and antiglaucoma medications, with close monitoring of IOP and graft integrity. Regular follow-up was planned to ensure continued recovery and graft stability.

Severe corneal graft rejection has been reported in up to two-thirds of cases, with graft clarity maintained in two-thirds of these.[1] Graft rejections most commonly occur within the first six months after surgery.[4] Acute graft rejection may present with conjunctival injection, anterior chamber activity, keratic precipitates, endothelial rejection line (Khodadoust line) and stromal or epithelial oedema.[4] Early recognition of the signs of rejection is vital, as initiation of early treatment will ensure a better visual prognosis. Systemic corticosteroid is useful in cases of early and severe graft rejection.[4] The rejection reversal rate ranges from 50-80% in patients treated with pulse and oral corticosteroids, suggesting a favourable outcome when using systemic corticosteroid to manage graft rejection.[5] In our case, the patient received high-dose pulse corticosteroid followed by oral prednisolone, leading to successful reversal of graft rejection.

Pulse corticosteroid therapy refers to the administration of a supraphysiological dose of corticosteroid, conventionally 500 to 1000 mg of intravenous methylprednisolone daily for one to three days, given over a short period.[5-9] This achieves faster control of an acute immunological insult while reducing the cumulative steroid burden and the adverse effects associated with prolonged high-dose oral therapy. Pulse therapy is well established in ophthalmology. In acute optic neuritis, intravenous methylprednisolone hastens visual recovery[8], and in sight-threatening thyroid eye disease, single doses of 500 to 1000mg over three days constitute first-line treatment for dysthyroid optic neuropathy.[9] In corneal transplant, Hill et al. demonstrated in a randomised comparison that a single intravenous methylprednisolone pulse was superior to oral steroid alone in reversing rejection and that it reduced the incidence of subsequent rejection episodes.[5] Our management followed this principle.

The quality of the donor corneal tissue merits consideration in this case. Although the preoperative eye bank assessment was satisfactory, the donor cornea was found intraoperatively to have a total epithelial defect and stromal oedema. These changes were most likely due to epithelial loss during storage and handling rather than to endothelial compromise, since the endothelial cell density met our threshold for corneal transplant. Even so, a suboptimal donor cornea at the time of surgery may lead to delayed epithelialisation, persistent epithelial defect and prolonged ocular surface inflammation. Ocular surface inflammation is a known risk factor for rejection. It promotes neovascularisation and neolymphangiogenesis, drawing immune cells into the graft and increasing risk of rejection.[10] Our patient followed a similar course, developing epithelial defect and corneal infiltrates before the rejection episode.

This case highlights the importance of careful donor corneal tissue assessment before grafting, including endothelial cell density, epithelial integrity and stromal clarity. In elective cases such as keratoconus, where the prognosis is otherwise good, it may be preferable to request another donor corneal button rather than accept borderline tissue and risk a good outcome.

CONCLUSION

Early recognition of graft rejection is crucial, as prompt treatment reduces the risk of irreversible graft damage. Pulse corticosteroid therapy offers rapid control of the acute rejection episode while reducing the cumulative side effects of prolonged oral corticosteroids and may lower the risk of further rejection, supporting long-term graft survival.

DECLARATION OF PATIENT CONSENT

The authors confirm that they have obtained all necessary patient consent forms. These forms indicate that the patient has provided consent for their images and clinical information to be published in the journal. The patients acknowledge that their names and initials will not be disclosed and that every effort will be made to protect their identity, though complete anonymity cannot be assured.

REFERENCES

1. Yamazoe K, Yamazoe K, Shimazaki-Den S, Shimazaki J. Prognostic factors for corneal graft recovery after severe corneal graft rejection following penetrating keratoplasty. BMC Ophthalmol 2013; 13: 5.
2. Vail A, Gore SM, Bradley BA, Easty DL, Rogers CA. Corneal graft survival and visual outcome: a multicenter study. Corneal Transplant Follow-up Study Collaborators. Ophthalmology 1994; 101(1): 120-7.
3. Szkodny D, Wróblewska-Czajka E, Wylęgała A, Nandzik M, Wylęgała E. Incidence of complications related to corneal graft in a group of 758 patients. J Clin Med. 2023; 12(1): 220.
4. Mandal S, Maharana PK, Kaweri L, Asif MI, Nagpal R, Sharma N. Management and prevention of corneal graft rejection. Indian J Ophthalmol 2023; 71(9): 3149-59.
5. Hill JC, Maske R, Watson P. Corticosteroids in corneal graft rejection: oral versus single pulse therapy. Ophthalmology 1991; 98(3): 329-33.
6. Buttgereit F, da Silva JAP, Boers M, Burmester GR, Cutolo M, Jacobs J, et al. Standardised nomenclature for glucocorticoid dosages and glucocorticoid treatment regimens: current questions and tentative answers in rheumatology. Ann Rheum Dis 2002; 61(8): 718-22.
7. Stahn C, Buttgereit F. Genomic and nongenomic effects of glucocorticoids. Nat Clin Pract Rheumatol 2008; 4(10): 525-33.
8. Beck RW, Cleary PA, Anderson MM Jr, Keltner JL, Shults WT, Kaufman DI, et al. A randomized, controlled trial of corticosteroids in the treatment of acute optic neuritis. N Engl J Med 1992; 326(9): 581-8.
9. Bartalena L, Kahaly GJ, Baldeschi L, Dayan CM, Eckstein A, Marcocci C, et al. The 2021 European Group on Graves' orbitopathy (EUGOGO) clinical practice guidelines for the medical management of Graves' orbitopathy. Eur J Endocrinol 2021; 185(4): G43-67.
10. Armitage WJ, Goodchild C, Griffin MD, Gunn DJ, Hjortdal J, Lohan P, et al. High-risk corneal transplantation: recent developments and future possibilities. Transplantation 2019; 103(12): 2468-78.

Bilateral ocular toxoplasmosis in an elderly immunocompetent patient: A rare case of sequential vision loss

Nurul Syafiela Zainuddin, MBBS[1,2], Nor Akmal Bahari, MBBS[1], Safinaz Mohd Khialdin, MD[2]

[1]Department of Ophthalmology, Hospital Kuala Lumpur, [2]Department of Ophthalmology, Faculty of Medicine, Universiti Kebangsaan Malaysia

SUMMARY

We report a rare case of bilateral ocular toxoplasmosis in a 74-year-old immunocompetent woman who presented with sequential progressive visual loss, initially in the right eye followed by the left. The clinical picture was atypical for age, and initial differential diagnoses included endogenous endophthalmitis and masquerades syndrome. Despite initial intravitreal and systemic antibiotics her eye condition remains status quo hence diagnostic vitrectomy and vitreous biopsy was performed, however yielded negative findings. Investigations revealed positive Toxoplasma gondii IgG antibodies. Final diagnosis of ocular toxoplasmosis was established, and she responded to prolonged anti-toxoplasma treatment. This case highlights the importance of considering toxoplasmosis in the differential diagnosis of posterior uveitis, even in elderly immunocompetent individuals.

INTRODUCTION

Toxoplasma gondii is an obligate intracellular protozoan parasite that infects nearly one-third of the global population. Ocular involvement, in the form of toxoplasmic chorioretinitis, typically results from congenital infection or reactivation of latent cysts in the retina. Although generally seen in younger patients, especially adolescents and young adults, elderly cases have been documented but remain rare. Bilateral ocular toxoplasmosis is uncommon, particularly in immunocompetent individuals. It can pose a diagnostic challenge, especially when the clinical presentation mimics other infectious or non-infectious causes of posterior uveitis or endophthalmitis. Dense vitritis, as seen in this case, may obscure chorioretinal lesions and complicate the clinical assessment.

This case report illustrates an atypical presentation of bilateral ocular toxoplasmosis in elderly, immunocompetent woman, initially treated for bilateral endogenous endophthalmitis. Early recognition, appropriate antimicrobial therapy, and surgical intervention resulted in better visual recovery and resolution of inflammation.

CASE PRESENTATION

A 74- year-old woman with a background of hypertension, hyperlipidemia, and a history of benign breast lumpectomy presented with gradually worsening blurring of vision in her right eye for six months. Three months later, she developed similar symptoms in the left eye, along with bilateral eye floaters. There was no associated redness, eye pain, photophobia, or discharge. Her prior ophthalmic history included uncomplicated bilateral cataract surgeries performed years earlier. She reported no history of recent travel, trauma, animal contact, or pet ownership. Systemic review was otherwise unremarkable.

On presentation, her best-corrected visual acuity (BCVA) was counting fingers (CF) in both eyes. Anterior segment examination revealed bilateral mutton-fat keratic precipitates, anterior chamber cells 3+, and no hypopyon, fibrin, or iris nodules. The conjunctiva and eyelids appeared normal with no chemosis. Intraocular pressures were within normal range. Fundus examination was limited due to dense vitritis, although a faint hue of the optic disc was visible in both eyes. B-scan ultrasonography showed dense vitreous opacities bilaterally and inferior exudative retinal detachment in the left eye. Based on these findings, a provisional diagnosis of bilateral endogenous endophthalmitis was made, and she was admitted for further management.

Initial treatment included intravitreal vancomycin and ceftazidime in both eyes. The patient was treated with systemic ciprofloxacin to cover for infection. Vitreous taps were performed and sent for microbiological analysis, including gram stain, culture, and cytology. Laboratory workup, including complete blood count, ESR, CRP, renal and liver function tests, HIV screening, autoimmune panel, and tumor markers, was unremarkable. Notably, Toxoplasma gondii IgG was positive with negative IgM, suggesting prior exposure or reactivation.

Considering the positive Toxoplasma gondii IgG serology and unremarkable culture results, ocular toxoplasmosis was considered in the differential diagnosis. The patient was treated with oral trimethoprim-sulfamethoxazole twice daily and oral prednisolone, initiated 48 hours after antimicrobial therapy.

Due to persistently dense vitritis obscuring fundal view, the patient underwent pars plana vitrectomy and vitreous biopsy in both eyes for both diagnostic and therapeutic reasons.

This article was accepted: 17 July 2026
Corresponding Author: Safinaz Mohd Khialdin
Email: drsafinaz_1978@yahoo.com.my

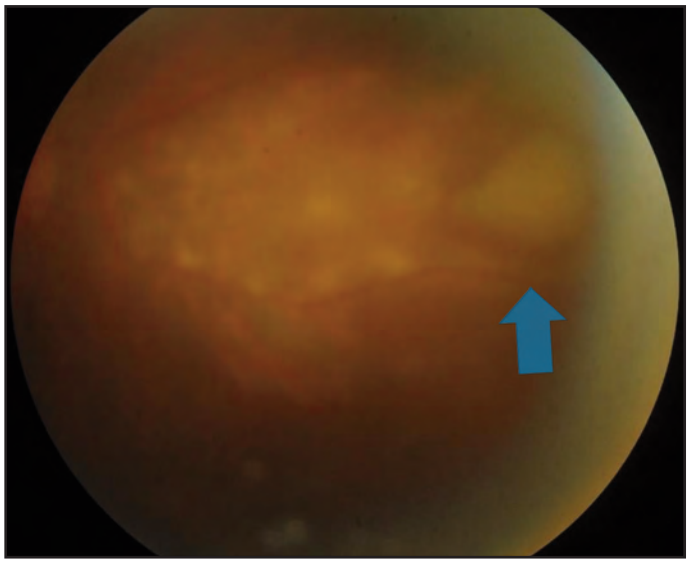

Fig. 1: Fundus photo 2 weeks post vitrectomy: Right eye showed large area of retinitis adjacent to chorioretinal scarring

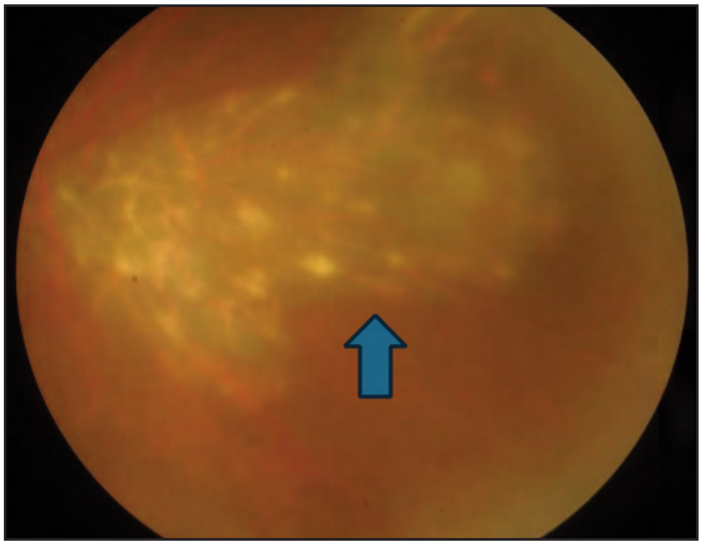

Fig. 2: Fundus photo at 7 month follow up showed extensive chorioretinal scarring

Intraoperative findings in the right eye included dense vitritis, a pink optic disc, and a large nasal retinal lesion with central yellowish activity surrounded by scarring. In the left eye, there were two chorioretinal lesions with well-demarcated scarring located superonasal to vascular arcade. Although positive Toxoplasma gondii IgG serology alone indicates previous exposure, the characteristic intraoperative retinal findings and exclusion of alternative diagnoses supported the diagnosis of reactivated ocular toxoplasmosis. Vitreous samples sent intraoperatively were negative for bacterial and fungal organisms. Cytology did not reveal any malignant cells. Postoperatively, her left eye showed significant improvement, with the retinal lesions progressing to inactive scarring and reduction in vitreous inflammation. The right eye, however, demonstrated slower recovery with ongoing low-grade inflammation, necessitating prolonged anti-toxoplasma therapy for a total of 20 weeks.

At final follow up, her vision had improved to 6/9 in the left eye and 6/36 complicated with vitreomacular traction (VMT) on right eye. Fundus examination showed resolution of active inflammation with well-formed chorioretinal scars. The patient remained systemically well, with no recurrence during the observation period.

DISCUSSION

Ocular toxoplasmosis remains the leading cause of posterior uveitis worldwide.[1] It typically presents in younger, immunocompetent individuals as a unilateral retinochoroiditis adjacent to a pigmented scar, associated with vitreous inflammation seen as headlight in the fog appearance in fundus examination. However, atypical presentation particularly in the elderly are increasingly reported.[2] Bilateral involvement, as seen in our patient, an immunocompetent host and often raises suspicion for masquerade syndromes such as intraocular lymphoma or other infectious etiologies like endogenous endophthalmitis or tuberculosis.[3]

The clinical diagnosis of ocular toxoplasmosis relies on the identification of characteristic retinal lesions, supported by serology. Although positive Toxoplasma gondii IgG indicates previous exposure rather than active infection, it supports the diagnosis when interpreted in the appropriate clinical context. In our patient, the diagnosis was established based on the characteristic intraoperative retinal findings following trans pars plana vitrectomy.

Polymerase chain reaction (PCR) of intraocular fluid could be considered if the diagnosis remains unclear but was not necessary here due to typical intraoperative retinal findings and clinical improvement with anti-toxoplasma therapy. In elderly patients, dense vitritis may obscure chorioretinal lesions, necessitating surgical intervention for diagnosis and therapeutic purposes.[4]

This case emphasizes the importance of considering toxoplasmosis even in the elderly patients, as age- related immune modulation or subclinical immunosuppression may predispose to reactivation. Although IgM was negative, the positive IgG, suggestive intraoperative retinal findings and favorable response to anti-toxoplasma therapy confirmed the diagnosis.[5]

Pars plana vitrectomy played a pivotal role in the management of this patient by providing both diagnostic and therapeutic benefits. Dense vitritis initially obscured the posterior segment, preventing adequate fundus examination and making clinical diagnosis challenging. Removal of the vitreous opacities restored visualization of the retina, allowing identification of the characteristic retinochoroidal lesions that strongly supported the diagnosis of ocular toxoplasmosis. In addition, vitreous biopsy facilitated microbiological analysis and cytological examination, enabling exclusion of bacterial and fungal infections as well as intraocular malignancy. Therapeutically, vitrectomy reduced the inflammatory burden by removing vitreous debris and inflammatory mediators, improved media clarity, and facilitated subsequent monitoring of treatment response. In patients with atypical presentations and dense vitritis, pars plana vitrectomy is therefore an important adjunctive procedure for both diagnostic clarification and therapeutic management.

While standard triple therapy for ocular toxoplasmosis includes pyrimethamine, sulfadiazine, and folinic acid, our patient was treated successfully with trimethoprim-sulfamethoxazole due to availability, cost, and tolerability. This regime has been shown in studies to be equally effective, especially in immunocompetent patients While the standard treatment for ocular toxoplasmosis traditionally consists of pyrimethamine, sulfadiazine, and folinic acid, alternative regimens have been increasingly adopted in clinical practice due to considerations of availability, cost, and safety profile. In our patient, oral trimethoprim-sulfamethoxazole (TMP-SMX) was selected as first-line therapy. This decision was supported by multiple studies demonstrating that TMP-SMX is an effective alternative to classical triple therapy, with comparable efficacy in terms of lesion resolution and visual outcomes, particularly in immunocompetent patients.[1,5,8] In addition, TMP-SMX offers advantages including better tolerability, simpler dosing, and reduced need for haematological monitoring compared to pyrimethamine-based regimens.

The prognosis is generally good with timely diagnosis and appropriate treatment. The recurrence rate may occur within the first year after resolution; hence, close monitoring is important, and in some cases, long-term prophylactic therapy may be required.[6-7]

CONCLUSION

This case highlights an atypical presentation of bilateral ocular toxoplasmosis in immunocompetent elderly. Although typically seen in younger individuals as a unilateral condition, clinicians should remain vigilant for atypical presentations, particularly when fundus visualization is limited by dense vitritis. In such cases, early diagnostic vitrectomy not only aids visualization and diagnostic clarification but also offers therapeutic benefit. The successful response to trimethoprim-sulfamethoxazole and corticosteroids underscores its value as a practical alternative to traditional therapy. Prompt recognition and appropriate management can lead to significant visual recovery, even in complex bilateral cases.

ACKNOWLEDGEMENT

The authors wish to express their sincere appreciation to the Director General of Health Malaysia for granting permission to publish this paper. We are especially grateful to Dr. Nor Azita, Consultant Ophthalmologist, for her invaluable expertise in the management of this patient. We also extend our heartfelt thanks to the Department of Ophthalmology, Hospital Kuala Lumpur, for their support and contributions to this work.

DECLARATION OF PATIENT CONSENT

These authors certify that they have obtained all appropriate patient consent forms. In the form, the patient was given her consent for her images and other clinical information to be reported in the journal. The patient understands that her name and initials will not be published, and due efforts will be made to conceal his identity, but anonymity cannot be guaranteed.

CONFLICT OF INTEREST

There was no conflict of interest.

REFERENCES

1. Holland GN. Ocular toxoplasmosis: a global reassessment. Part I: epidemiology and course of disease. Am J Ophthalmol 2003; 136(6): 973-88.
2. Montoya JG, Liesenfeld O. Toxoplasmosis. Lancet 2004; 363(9425): 1965-76.
3. Yazdanpanah O, Monday LM, Surapaneni S, Singh V, Chi J. Ocular Toxoplasmosis Mimicking Lymphoma: Exploring the Correlation and Distinction. Cureus 2021; 13(1): e13014.
4. Wakefield D, Cunningham ET Jr, Pavesio C, Garweg JG, Zierhut M. Controversies in ocular toxoplasmosis. Ocul Immunol Inflamm 2011; 19(1): 2-9.

5. Garweg JG, de Groot-Mijnes JD, Montoya JG. Diagnostic approach to ocular toxoplasmosis. Ocul Immunol Inflamm. 2011; 19(4): 255-61. Erratum in: Ocul Immunol Inflamm. 2011; 19(6): 456.
6. Silveira C, Belfort R Jr, Muccioli C, Holland GN, Victora CG, Horta BL, Yu F, Nussenblatt RB. The effect of long-term intermittent trimethoprim/sulfamethoxazole treatment on recurrences of toxoplasmic retinochoroiditis. Am J Ophthalmol 2002; 134(1): 41-6.
7. Wadhwa H, Sims JL, Niederer RL. Rate of recurrence of toxoplasmosis retinochoroiditis at a tertiary eye centre in Auckland. N Z Med J 2022; 135(1553): 10-8.
8. Soheilian M, Sadoughi MM, Ghajarnia M, Dehghan MH, Yazdani S, Behboudi H, Anisian A, Peyman GA. Prospective randomized trial of trimethoprim/sulfamethoxazole versus pyrimethamine and sulfadiazine in the treatment of ocular toxoplasmosis. Ophthalmology 2005; 112(11): 1876-82.

Acknowledgement
August Issue 2026

The Editorial Board of The Medical Journal of Malaysia gratefully acknowledge the following individuals for publication:

Handling Editor:

1. Prof Dr Andee Dzulkarnaen

Reviewers:

1. Abdul Rashid Abdul Rahman
2. Adli Azam
3. Aina Mariana Abdul Manaf
4. Andrew Chang Kean Wei
5. Asmah Binti Johar
6. Asrul Abdul Wahab
7. Aufar Zimamuz Zaman Al Hajiri
8. Asrul Abdul Wahab
9. Azlina Mokhtar
10. Azwani Abdullah
11. Chee Wei Tan
12. Chen Shen Lam
13. Choudhury Habibur Rasul
14. David Chew
15. Fadzilah Mohamad
16. Fauzi Abdul Rani
17. Glen Alvin
18. Hock Hin Chua
19. Ibrahim Abdelazim
20. Jessica Mani Penny Tevaraj
21. Karmila Abu Bakar
22. Karthigesu Aimanan
23. Kok Meng John Chan
24. Lailatul Imtikhan
25. Leong Chee Loon
26. Mazlin Baseri
27. Muhammad Luthfi Adnan
28. Mohamad Aziz Salowi
29. Mohd Aziz Husni
30. Mohd Faizal Ahmad
31. Mohd Radniwan a Rashid
32. Muhammad Fadhli Bin Hamid
33. Muhd Syafi Abd Bari
34. Naael H Ali
35. Nik Hazlina Bt Nik Hussain
36. Nurul Zaynah Nordin
37. Nor Fariza Ngah
38. Norazam Abbas
39. Norasnieda Md Shukri
40. Norsyamira Aida Mohamad Umbaik
41. Peng Peng Ang
42. Rozanah Abd Rahman
43. Saidi Noor-Amalina
44. Salman Amiruddin
45. Sharif Ahmad
46. Shatha Farouk Abdullah
47. Sheikh Salahuddin Ahmed
48. Shelva Meena Gurusamy
49. Shivali Shamsher
50. Siew Hong Hooi
51. Siew Mooi Ching
52. Shu Ching Teo

53. Shuaibah Ab Ghani
54. Sivananthan Asokumar
55. Siti Nazira Abdullah
56. Siti Nur Amira Abu Kassim
57. Sivalingam Nalliah
58. Suresh Subramaniam
59. Theepa Nesam
60. Tim Aung
61. Vasu Pillai A/L Letchumanan
62. Verna Kar Mun Lee